
**ISSN Print:** 2394-7489
**ISSN Online:** 2394-7497
IJADS 2014; 1(1): 36-40

www.oraljournal.com
Received: 02-01-2015
Accepted: 07-02-2015

**Shantipriya Reddy**
*Prof and Head, department of periodontics, Dr. Syamala Reddy Dental College, Hospital and Research Centre, Bengaluru-560037, Karnataka, India.*

**Prasad MGS**
*Reader, Department of periodontics, Dr. Syamala Reddy Dental College, Hospital and Research Centre, Bengaluru-560037, Karnataka, India.*

**Sanchita Prasad**
*Sr lecturer, department of periodontics, Dr. Syamala Reddy Dental College, Hospital and Research Centre, Bengaluru-560037, Karnataka, India.*

**Nirjhar Bhowmick**
*Sr lecturer, department of periodontics, Dr. Syamala Reddy Dental College, Hospital and Research Centre, Bengaluru-560037, Karnataka, India.*

**Sravya L**
*Sr lecturer, department of periodontics, Dr. Syamala Reddy Dental College, Hospital and Research Centre, Bengaluru-560037, Karnataka, India.*

**Abis Amir**
*Post Graduate student, department of periodontics, Dr. Syamala Reddy Dental College, Hospital and Research Centre, Bengaluru-560037, Karnataka, India.*

**Krishnanad P**
*Post Graduate student, department of periodontics, Dr. Syamala Reddy Dental College, Hospital and Research Centre, Bengaluru-560037, Karnataka, India.*

**Correspondence**
**Shantipriya Reddy**
Prof and Head, department of periodontics, Dr. Syamala Reddy Dental College, Hospital and Research Centre, Bengaluru-560037, Karnataka, India.

# Extraction socket preservation using β tricalcium phosphate bone graft plug and platelet rich fibrin membrane – A case series.

**Shantipriya Reddy, Prasad MGS, Sanchita Prasad, Nirjhar Bhowmick, Sravya L, Abis Amir, Krishnanad P**

**Abstract**
**AIM:** The aim of the present case series is to check the efficacy of beta tricalcium phosphate bone graft plug along with PRF membrane in post extraction socket preservation.
**Material and Methods:** Five patients with single, non molar tooth indicated for extraction were selected for the study. Atraumatic extraction was performed and a β-tricalcium phosphate bone graft plug was used for socket preservation. A PRF membrane was used to cover the bone graft occlusally and the extraction site was sutured. Cone Beam Computed Tomography was performed immediately after the extraction and after 6 months post operatively.
**Result:** There was a mean average loss of 7.3% and 4.9% in palatal/lingual and buccal vertical height respectively. The width showed an average mean reduction loss of 6.8% at the crest and an average loss of 10.2% at a level 6 mm below the alveolar crest.
**Conclusion:** The results encourage the use of β tricalcium phosphate bone graft plug with PRF membrane as a suitable alternative for performing extraction socket preservation.

**Keywords:** Socket preservation, bone graft plug, PRF membrane, Periotome, Atraumatic extraction.

## 1. Introduction

Tooth extraction whether due to caries, trauma or advanced periodontal disease is a traumatic procedure often resulting in immediate destruction and loss of alveolar bone and surrounding soft tissues [1] In general, the alveolar bone remodeling that occurs after tooth loss yields diminished alveolar ridge dimensions in both the vertical and horizontal planes up to 40% to 60% bone loss height and width as early as 3 months. On an average, grafted extraction sites have reported a loss of width < 2mm and a loss of height < 0.5mm as compared to non-grafted extraction sites which have reported losses of ridge width from 2-6 mm and ridge height of 1 mm with great variations [2]

To prevent this clinical situation, different authors have described several surgical procedures, ranging from regenerative techniques for socket preservation to immediate implant placement. Regenerative techniques have been widely tested in controlled and uncontrolled studies with various materials and clinical approaches: bone grafting alone, including autografts, allografts, xenografts, and alloplasts alone or in combination with absorbable or nonabsorbable membrane [3].

A recent innovation in dentistry is the preparation and use of platelet rich fibrin (PRF), a concentrated suspension of the growth factors found in platelets. These growth factors are involved in wound healing and are postulated as promoters of tissue engineering. Considering the soft tissue and hard tissue healing potential of PRF in various procedures, the present study selected PRF membrane [4].

Thus the aim of the present case series is to check the efficacy of beta tricalcium phosphate bone graft plug along with PRF membrane in post extraction socket preservation.

## 2. Materials and Methods

### 2.1 Study population and design

Five patients were selected from outpatient Department of Periodontics and Implantology, Dr. Syamala Reddy Dental College Hospital and Research Centre, Bengaluru, Karnataka, between

February 2014 and October 2014. The study was approved by the ethical committee of Dr. Syamala Reddy Dental College and Hospital.

Patients were considered for the study based on the following inclusion criterias: 1. Male and female subjects of 18 years of age and above. 2. Hopeless or non-restorable, single, non-molar tooth per quadrant with adjacent teeth present. 3. Subjects with good general health and good oral hygiene. 4. Subjects with freshly extracted sockets. Exclusion criterias were; 1. Endodontic lesions and/or caries (beyond the hopeless tooth considered for this study). 2. Uncontrolled or severe systemic diseases. 3. Medical conditions or Patients taking medication associated with compromised bone healing or medications affecting the number and function of platelets.4. Patients with bleeding disorders. 5. Pregnant and lactating mothers. 6. Previous head and neck radiation therapy. 7. History of chemotherapy in last 12 months.

A written consent from the patients was taken after the whole procedure was explained to them.

**2.2 Presurgical treatment**

Each patient received a diagnostic workup including periapical radiographs, study casts, clinical photographs and a clinical examination to evaluate the proposed extraction site. Customized acrylic stents were fabricated on study casts to serve as fixed reference points for vertical measurements. Occlusally stents were fabricated to cover the tooth to be extracted and extended one tooth mesially and distally and it extended till the gingival margin on the buccal and palatal/lingual aspects. Three grooves, on mid buccal, mid palatal/lingual and on occlusal surface of stent were made and gutta purcha was inserted to act as radiopaque markers for cbct assessment. Occlusal grooves were made at the midpoint after determining the Mesio-distal distance between the teeth adjacent to the tooth to be extracted.

Baseline data were collected just before the extraction and cone beam computed tomography (CBCT) was taken immediately after the procedure. Parameters assessed included 1.Gingival Index [Loe and Silness, 1963] 2.Plaque Index [Silness and Loe, 1964].

Extraction sockets were classified as being class I (adequate), class II (compromised) or as class III (deficient) based on the extraction socket classification system as proposed by Juodzbalys *et al*. [5]

Radiographic investigations included were:

Apico-coronal and Bucco-lingual bone level:

Loss in vertical height of the alveolar bone was measured by marking the distance of the alveolar crest from the radiopaque marker on CBCT at baseline and then after 6 months. The loss was calculated by subtracting the baseline data from the follow up data. Vertical distance was measured at both buccal and palatal/lingual extraction socket wall individually.

The loss in width of the alveolar bone was measured at the mid-occlusal point where a radiographic stent was placed. The width of the alveolar bone was measured at the crest at this level and at a level 6mm apical to the crest. The loss was calculated by subtracting the follow up data from the baseline data.

After 6 months from treatment all the measurements were repeated.

**2.3 Surgical treatment**

A full thickness mucoperiosteal flap was elevated to expose both the buccal and palatal/lingual aspects of the alveolar ridge. Atraumatic extraction using periotome and extraction forceps was performed. The extraction socket was carefully curetted to remove all the soft tissue. After flap reflection, a custom acrylic stent was used to obtain the vertical height data. β- tricalcium phosphate bone graft plug was inserted up to the level of the crest of the socket and it was covered occlusally with PRF membrane. The buccal and palatal/lingual flaps were approximated back into position by giving vertical mattress sutures using a 3-0 mersilk suture.

**2.4 Postoperative Care and Evaluation**

The patients were put on an antibiotic regime consisting of amoxicillin 500 mg three times a day for 5 days along with a chlorhexidine mouthrinse. The patients were asked to abstain from brushing on the surgical area for at least 1 week and they were recalled 1 week postoperatively during which sutures were removed and the operated area was evaluated for healing, infection and any signs of ulceration and necrosis which were tabulated separately in the chart provided. Supportive periodontal therapy was provided every month in both test and control group. Patients were reevaluated at the end of 6th month.

**3. Results**

All subjects reported uneventful healing at all sites. Of the 5 patients treated, 4 were classified as having class I or adequate type extraction socket whereas only one patient was classified as having class II or compromised type extraction socket. Extraction sockets were classified based on the extraction socket classification system as proposed by Juodzbalys *et al*. [5] The classification system developed was based on soft tissue conditions (soft tissue quantity and quality and gingival tissue biotype) as well as on hard tissue parameters (height of alveolar process, available bone beyond the apex of the extraction socket, extraction socket labial plate vertical position, extraction socket facial bone thickness, presence of socket bone lesions, intradental bone peak height, Mesio-Distal distance between adjacent teeth, and the need for palatal angulation. The inference drawn from the results obtained depicts changes in crestal bone height and width after 6 months.

The results of the study showed that there was a mean average loss of 7.3% in vertical height of the palatal/lingual wall of the extraction socket and a mean average loss of 4.9% in vertical height of buccal wall of the extraction socket over a time period of 6 months (Table 1). The width showed an average mean reduction loss of 6.8% at the crest and an average loss of 10.2% at a level 6 mm below the alveolar crest after 6 months (Table 2). The only case categorized as class II extraction socket showed a loss of 3.2% in buccal extraction socket wall height and a loss of 14% in lingual extraction socket wall height after 6 months. The loss of width in this case was 1.2% and 4.4% at the crest and at a level 6mm below the crest after 6 months.

**Table 1**

| | Vertical distance of palatal/lingual socket wall from reference point (in mm) | | Vertical distance of buccal/labial socket wall from reference point (in mm) | |
|---|---|---|---|---|
| | At baseline | after 6 months | At baseline | after 6 months |
| CASE 1 | 10.5 | 12.5 | 7.2 | 9.0 |
| CASE 2 | 5.7 | 5.9 | 4.9 | 5.7 |
| CASE 3 | 5.2 | 4.6 | 7.5 | 6.4 |
| CASE 4 | 6.6 | 7.1 | 10.4 | 10.6 |
| CASE 5 | 6.4 | 6.8 | 8.6 | 8.9 |

**Table 2**

| | Width ( At The Crest) (in mm) | | Width (At 6 Mm Below The Crest) (in mm) | |
|---|---|---|---|---|
| | At baseline | After 6 Months | At Baseline | After 6 Months |
| CASE 1 | 7.9 | 7.1 | 9.5 | 7.8 |
| CASE 2 | 7.9 | 7.8 | 9.0 | 8.6 |
| CASE 3 | 6.5 | 5.0 | 5.7 | 5.3 |
| CASE 4 | 6.3 | 6.8 | 6.7 | 5.7 |
| CASE 5 | 7.2 | 6.6 | 8.1 | 7.6 |

**Fig 1:** Tooth #21.

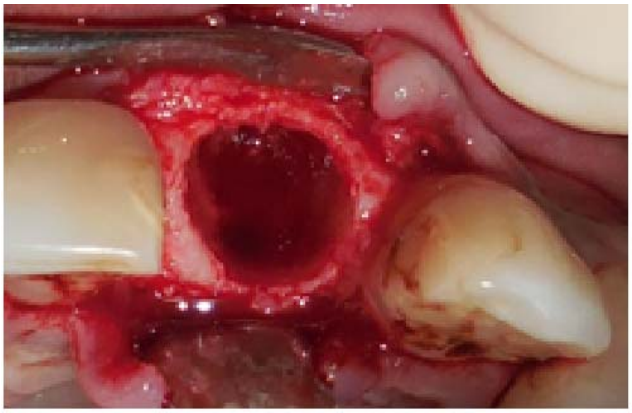

**Fig 2:** Socket after Atraumatic extraction.

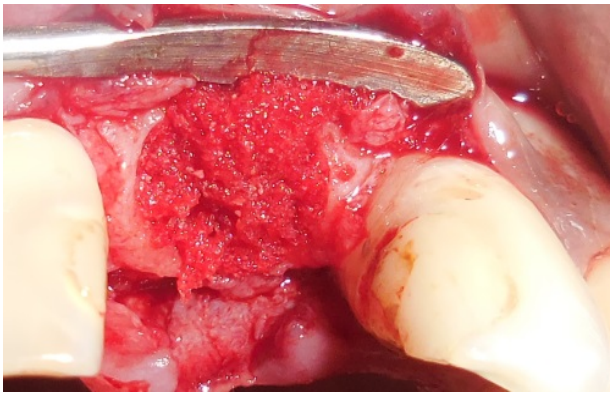

**Fig 3:** Bone graft plug inserted up to the crest.

**Fig 4:** PRF membrane adapted over the bone graft plug.

## 4. Discussion

The healing of an extraction socket is characterized by both internal and external changes that ultimately affect the shape of the alveolar ridge [6]. Studies indicate that during healing, bone does not regenerate to the level of bone crest or to the level of the neighboring teeth, and therefore 100% socket fill does not occur [7].

Alveolar ridge preservation is a relatively new surgical procedure aimed at retaining maximum bone and soft tissue after a tooth has been removed. By maintaining the original ridge morphology, there will be a minimal need for augmentation procedures thereby allowing the resultant restoration to be placed in an aesthetically and functionally ideal position.

Regenerative techniques have been widely tested in controlled and uncontrolled studies with various materials and clinical approaches: bone grafting alone, including autografts, allografts, xenografts, and alloplasts alone or in combination with absorbable or nonabsorbable membrane [3].

A wide range of barrier membranes have been used in numerous studies over the years, e.g., expanded polytetrafluoroethylene (ePTFE), collagen, polyglycolic acid, polyglactin 910 and recently PRF membrane. The literature justifies the use of bone grafting materials in freshly extracted

sockets. When demineralized freeze-dried bone allograft (DFDBA) was used in conjunction with a collagen membrane, the width of the alveolar ridge decreased from 9.2 mm to 8.0 mm, while the width of the socket sites that healed naturally decreased from 9.1 mm to 6.4 mm on average. In addition, the average loss of bone height in the latter group was 1 mm, while the grafted sites actually gained height. Even with no barrier membrane, a socket fill of nearly 85% can be achieved by placing porous bovine bone mineral in fresh extraction sites [8].

A recent publication showed that the combination of β-TCP and type I collagen used for simple preservation of a maxillary extraction socket without a barrier membrane resulted in new bone formation 9 months after the procedure with 62.6% of mineralized bone and 21.1% of bone marrow. β-TCP resorption occurs concurrently with new bone formation. Horch *et al.* reported 65% resorption of β-TCP 1 year after placement when used as bone substitute in large mandibular cystic defects, in alveolar clefts, and for maxillary sinus floor augmentations. Simunek *et al.* reported that the mean graft area occupied by β-TCP was 39%, 9 months after sinus augmentation procedures [9].

Leukocyte and platelet-rich fibrin (L-PRF) was first described by Choukroun as cited by Dohan *et al*. 2006 [10]. It is considered a second-generation platelet concentrate and has been used in various surgical procedures in an attempt to enhance wound healing.

The unique preparation technique allows L-PRF to trap at least 95% of the platelets of the collected blood into a fibrin mesh [11]. The fibrin mesh can then be easily manipulated into a membrane that allows it to be transferred to any surgical site. Here, high concentrations of the collected platelets allow for the slow release of growth factors (GFs) from the platelet granules. Compared to other platelet concentrates, L-PRF releases these factors at a sustained rate over a longer period, thereby optimizing wound healing [12]. Recently, L-PRF has also been shown to stimulate the growth of osteoblasts and periodontal ligament cells, both of which are significant for the regeneration of periodontal defects [13].

In a recent systematic review by Heggeler *et al*, the authors have noted that socket preservation techniques may aid in reducing the bone dimensional changes following tooth extraction. However, they do not prevent bone resorption so that a loss in width up to 3.48 mm and in height up to 2.64 mm may be still expected [14].

Lekovic *et al* in their study have demonstrated a loss of 0.38 mm in vertical height and a horizontal loss of 1.31 mm, whereas serino *et al* have found a gain of 1.30 mm in vertical height and florelline *et al* have found a gain of 1.76 mm in width of the alveolar bone [3].

In the present study, β-tricalcium phosphate bone graft plug was used because the shape of the graft plug confirms approximately to the shape of the extraction socket of a non molar tooth. This may act as an added advantage in maintaining adequate space for regeneration to occur owning to the tensile property of the plug, apart from the osteoconductive property of β-tricalcium phosphate. There is adequate literature that advocates the use of different techniques for extraction socket preservation in non molar teeth. However the effectiveness of bone graft plug in extraction socket preservation needs to be well established against the set parameters of various hard tissue and soft tissue changes.

In the present study an average loss of 2.25 mm in height and a loss of 2.5 mm in width at the crest and 4 mm at a level 6 mm apical from the crest were noted. Also, the loss in height was more in the buccal extraction socket wall (2.5 mm) as compared to the palatal/lingual extraction socket wall (2 mm).

## 5. Conclusion

The result from the present case series is in agreement with the existing data on extraction socket preservation. The results encourage the use of β tricalcium phosphate bone graft plug with PRF membrane as a suitable alternative for performing extraction socket preservation. However, since the present study utilized only cone beam computed tomography for all the measurements, a more direct clinical measurement approach should also be utilized to confirm the radiographic analysis.

## 6. Conflict Of Interest Statement

Nil declared.

## 7. References


1. Caplanis N, Lozada LJ, Kan JYK. Extraction Defect Assessment, Classification and Management.CDA Journal; 2005; 33:853.
2. Brownfield LA, Weltman RL. Ridge preservation with or without an osteoinductive allograft: a clinical, radiographic, micro-computed tomography, and histologic study evaluating dimensional changes and new bone formation of the alveolar ridge. J Periodontol; 2012; 83: 581-583.
3. Orgeas GV, Clemintini M, Valeria DR, Sanctis MD. Surgical techniques for alveolar socket preservation: A systematic review. International Journal of oral and maxillofacial implant 2013; 28:1049-1061.
4. Sharma A, Pradeep AR. Treatment of 3 wall intrabony defects in patients with chronic periodontitis with autologous platelet rich fibrin: a randomized clinical trial Periodontol 2011; 82:1705-12.
5. Juodzbalys G, Sakavicius D, Wang H L. Classification of Extraction Sockets Based Upon Soft and Hard Tissue Components. J Periodontol 2008; 79:413-24.
6. Darby ST, Chen and Buser D. Ridge preservation techniques for implant therapy. The International Journal of Oral & Maxillofacial Implants 2009; 24:260-27.
7. D M.G.Ara´ ujo, Lindhe J. Ridge alterations following tooth extraction with and without flap elevation: an experimental study in the dog. Clinical Oral Implants Research 2009; 20:545-549.
8. Irinakis T. Rationale for socket preservation after extraction of a single-rooted tooth when planning for future Implant Placement. J Can Dent Assoc 2006; 72(10):917-22.
9. Bozidar MB, Brkovic, Hari SP, Michael D, Rohrer K, George K. Beta-tricalcium phosphate/type I collagen cones with or without a barrier membrane in human extraction socket healing: clinical, histologic, histomorphometric, and immunohistochemical evaluation. Clin Oral Invest 2012; 16:581-590.
10. Dohan DM, Choukroun JA. Platelet-rich fibrin (PRF): a second-generation platelet concentrate. Part II: platelet-related biologic features, Oral Surgery, Oral Medicine, Oral Pathology. Oral Radiology and Endodontology 2006; 101:e45-e50.
11. Ehrenfest DMD, DelCorso M, Diss A, Mouhyi J, Charrier JB. Three-dimensional architecture and cell composition of a Choukroun's platelet-rich fibrin clot and membrane. Journal of Periodontology 2010; 81:546-555.

12. Kang YH, Jeon SH, Parketal JY. Platelet-rich fibrin (PRF) is a bioscaffold and reservoir of growth factors for tissue regeneration. Tissue Engineering 2011; 17:349-359.
13. Effects of platelet-rich fibrin on human periodontally related cells. http://iadr.confex.com/iadr/2008Toronto/techprogram/ abstract104888.htm.
14. Ten HJMAG, Slot DE, Van der Weijden GA. Effect of socket preservation therapies following tooth extraction in non-molar regions in humans: a systematic review. Clin Oral Impl Res 2011; 22:779-788.