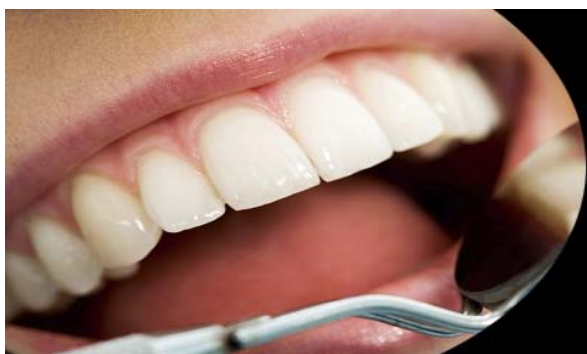



## International Journal of Applied Dental Sciences

ISSN Print: 2394-7489  
ISSN Online: 2394-7497  
IJADS 2015; 1(2): 37-39  
© 2015 IJADS  
www.oraljournal.com  
Received: 15-09-2014  
Accepted: 25-12-2014

### Kashyap A Patel

PG Student of Periodontology  
Department Narshinhbhai Patel  
Dental College & Hospital,  
Visnagar-384315 Gujarat, India.

### Sudhir S Patil

Professor and head of  
Periodontology Department  
Narshinhbhai Patel Dental  
College & Hospital, Visnagar-  
384315 Gujarat, India.

### Charu Agrawal

Reader of Periodontology  
Department Narshinhbhai Patel  
Dental College & Hospital,  
Visnagar.

### Akash P Patel

PG Student of Periodontology  
Department Narshinhbhai Patel  
Dental College & Hospital,  
Visnagar-384315 Gujarat, India.

### Jigar Kalaria

PG Student of Periodontology  
Department Narshinhbhai Patel  
Dental College & Hospital,  
Visnagar-384315 Gujarat, India.

### Correspondence

#### Kashyap A Patel

PG Student of Periodontology  
Department Narshinhbhai Patel  
Dental College & Hospital,  
Visnagar-384315 Gujarat, India.

## Gingival depigmentation: Case series

**Kashyap A Patel, Sudhir S Patil, Charu Agrawal, Akash P Patel, Jigar Kalaria**

### Abstract

Gingival pigmentation results from melanin granules which are produced by melanoblasts. Excessive gingival pigmentation is a major esthetic problem for many people. Different treatment modalities have been reported for depigmentation of gingiva such as bur abrasion, scraping, partial thickness flap, cryotherapy, electrosurgery and laser. In this case series describe four surgical techniques (bur abrasion, scraping, electrosurgery, and diode laser) for melanin depigmentation.

**Keywords:** Hyperpigmentation, Lasers, depigmentation

### 1. Introduction

A smile expresses a feeling of happiness, success, sociability, friendliness and politeness. The harmony of the smile is resolute not only by the shape, position and color of the teeth but also by the gingival tissues. This demand gets fulfilled not only by having a healthy set of dentition, but also esthetically enhanced gingival component. Gingival melanin pigmentation is one of the factors which determine the smile of an individual.

The colour of gingiva depends on several factors: number and size of blood vessels, thickness of the epithelium, level of keratinization, quantity of pigments. Oral pigmented lesions can have many etiologies, including drugs, heavy metals, genetics, endocrine disturbance, and inflammation [1].

Melanin, a brown pigment, is the most common cause of endogenous pigmentation of gingiva and is the most predominant pigmentation of mucosa. [2] Melanin pigmentation is caused by melanin granules in gingival tissue, which are produced in melanosomes of melanocytes. Melanocytes are primarily positioned in the basal and suprabasal cell layers of the epithelium [3].

Although physiologic melanin pigmentation is not a medical problem, patients may complain that their black gums are unaesthetic.

Numerous procedures have been developed for depigmentation of the gingiva, such as scalpel method, Bur abrasion [4], free gingival graft [5], gingivectomy [6], cryosurgery [7], and laser surgery [8].

Hence the aim of case series was to compare four different depigmentation techniques for removing melanin pigmentation of gingiva.

### 2 Surgical techniques

#### 2.1 Scalpel technique: (Fig 1, 2, 3)

After administering local anesthesia, the uppermost layer of the gingiva was scraped using 15 numbers. The blade was held parallel to the long axis of the teeth with Minimum pressure. (Fig-2) Bleeding was controlled with a sterile gauze pressure pack. Surgical areas were covered with a periodontal pack and post-operative instructions were given. Analgesics were prescribed. After one week the pack was removed and the surgical area was examined. The healing was satisfactory. Follow-up was done after 3 months (Fig-3)

#### 2.2 Bur method: (Fig 4, 5, 6)

For this depigmentation techniques with a round diamond bur, revolving bur was used on the surface of pigmented gingiva and moved with feather light strokes without giving any pressure. It was not kept in one place for a long time as it may result in thermal trauma and

permanent harm to underlying tissue. Medium size round bur was used because small bur might produce small pits rather than surface abrasion. (Fig-5) The bleeding was controlled and checked for any pigmented area remained and removed it to prevent relapse. The bleeding was stopped by applying pressure with a gauze piece on the denuded epithelium. Removal of gingival melanin pigmentation should be performed cautiously and the adjacent teeth should be protected, since the inappropriate application may cause gingival recession, damage to underlying periosteum and bone, delayed wound healing, 1 as well as loss of enamel. After one week the pack was removed and the surgical area was examined. And follow-up was done after 3 months (Fig-6)

**2.3 Electrosurgery: (Fig 7, 8, 9)**

Local anesthetic will be given to the operating field. The needle electrode application is used by a sweeping motion localized only in the pigmented regions. Care must be exercised to use feather-light brushing strokes to remove the pigmented areas. (Fig-8) The procedure is performed in a cervico-apical direction on all pigmented areas. Every five minutes, the operation field will be wiped with sterile gauze soaked in 1% normal saline solution. The depigmentation procedure continued until no pigments remained. Then surgical areas were covered with a periodontal pack and post-operative instructions were given. Analgesics were prescribed. After one week the pack was removed and the surgical area was examined and healing was satisfactory. And follow-up was done after 3 months (Fig-9)

**2.4 Laser: (Fig 10, 11, 12)**

We used semiconductor diode laser in this technique. After application of topical anesthesia. Before using laser some precaution should be given like safety glasses were worn by operating assistance and patient, reflected mirror surface were avoided, Avoid using laser in the presence of explosive gases. Depigmentation was done with light brushing strokes and the tip was kept in motion all the time. (Fig-11) Remnants of the ablated tissue were removed using sterile gauze dampened with saline solution. This procedure was repeated until the desired depth of tissue removal was achieved. Then the wound was covered with periodontal pack. Recall after 1 week & 3 months (Fig-12)

**3. Discussion**

Gingiva has been the most frequently pigmented of the intraoral tissues, in addition to being most readily seen during inspections. Melanin is the fundamental pigment that colours the tissues. It appears as early as three hours after birth in the oral tissues and in some cases is the only sign of pigmentation on the body [9].

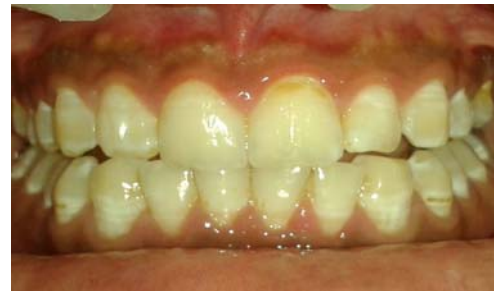Scalpel technique - The use of scalpel technique for depigmentation is the most economical and popular as compared to other techniques, which require more advanced armamentarium. And healing period for scalpel wounds is faster than other techniques. But scalpel surgery causes unpleasant bleeding during and after the operation.

Bur technique -The process of healing in bur method is similar to the scalpel technique. [10] It is also relatively simple, safe and method which can be easily done and readily repeated. Be additional care should be taken to control the speed and pressure of the bur so as not to cause undesirable abrasion or pitting of the tissue.

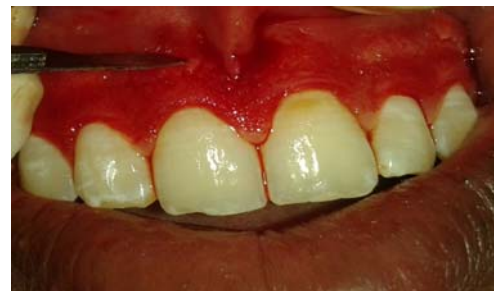Electrosurgery - Result was satisfactory, but the more postoperative discomfort and pain was observed compared to scalpel technique.

Laser technique - Main advantages of laser are easy, homeostasis, sterilization effects and excellent coagulation. Not required periodontal dressing. However, laser surgery has some disadvantages like Delayed healing and, expensive.

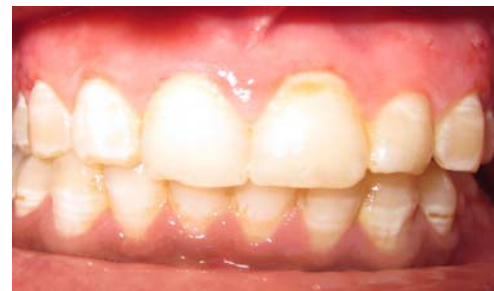**3.1 Figure**



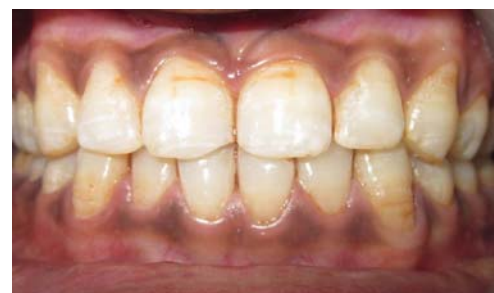**Fig 1: Pre-operative**



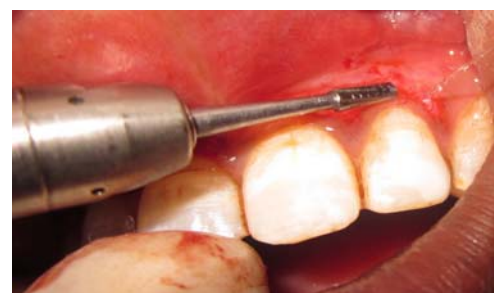**Fig 2: Depigmentation with Scalpel**



**Fig 3: Post-operative After 3 Months**

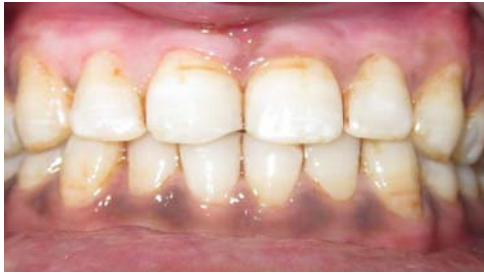

**Fig 4: Pre-operative**

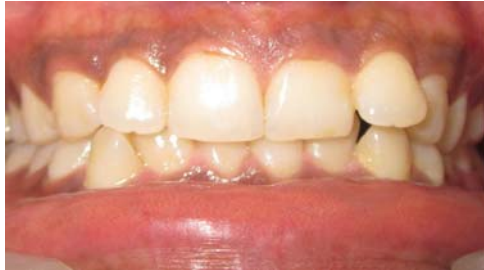

**Fig 5: Depigmentation with Bur**

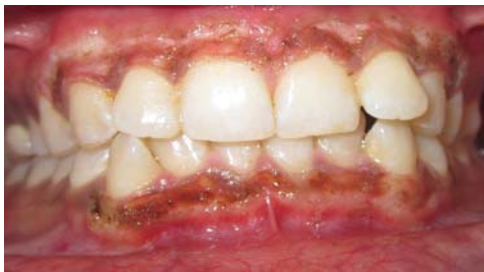



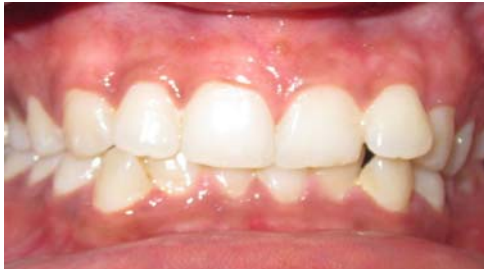**Fig 6:** Post-operative After 3 Months



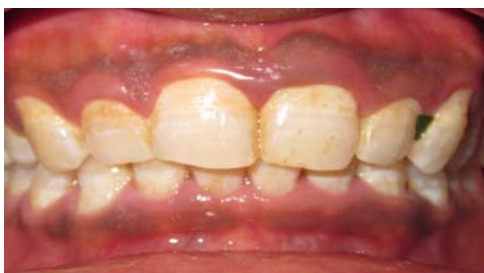**Fig 7:** Pre-operative



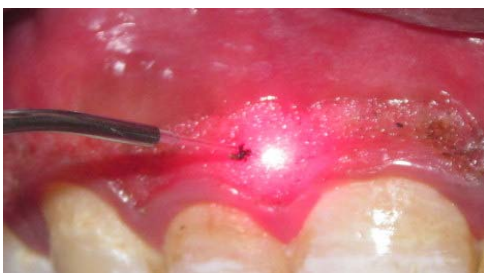**Fig 8:** Depigmentation with Electrosurgical Unit



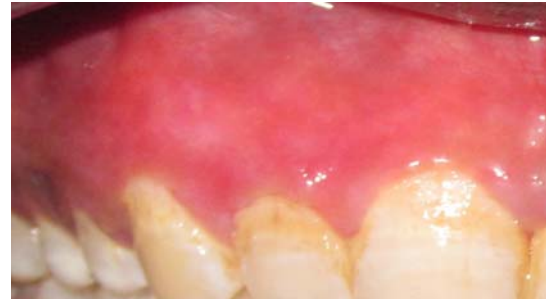
**Fig 9:** Post operative After 3 Months



**Fig 10:** Pre-operative



**Fig 11:** Depigmentation with Laser



**Fig 12:** Post-operative After 3 Months

#### 4. Conclusion

People with high smile lines increasing demand for esthetics requires removal of excessively pigmented gingival areas. This can be achieved with any of the four techniques described in this case series. The methods used here are easy and the results are satisfactory. However, we observed that patient discomfort during the initial healing period is more in electrosurgical & laser procedures.

#### References

1. Kauzman A, Pavone M, Blanas N, Bradley G. Pigmented lesions of the oral cavity: review, differential diagnosis, and case presentations. *J Can Dent Assoc* 2004; 70:682-3.
2. Dummet CO, Barends G. Oromucosal pigmentation: an updated literary review. *Periodontol*. 1971; 42(11):726-36.
3. Meleti M, Vescovi P, Mooi WJ, van der Waal I. Pigmented lesions of the oral mucosa and perioral tissues: a flow-chart for the diagnosis and some recommendations for the management. *Oral Surg Oral Med Oral Pathol Oral Radiol Endod* 2008; 105:606-16.
4. Farnoosh AA. Treatment of gingival pigmentation and discoloration for esthetic purposes. *Int J Periodontics Restorative Dent* 1990; 10:312-9.
5. Tamizi M, Taheri M. Treatment of severe physiologic gingival pigmentation with free gingival autograft. *Quintessence Int* 1996; 27:555-8.
6. Perlmutter S, Tal H. Repigmentation of the gingiva following surgical injury. *J Periodontol* 1986; 57:48-50.
7. Tal H, Landsberg J, Kozlovsky A. Cryosurgical depigmentation of the gingiva. A case report. *J Clin Periodontol* 1987; 14:614-7.
8. Nakamura Y, Hossain M, Hirayama K, Matsumoto K. A clinical study on the removal of gingival melanin pigmentation with the CO (2) laser. *Lasers Surg Med* 1999; 25:140-7.
9. Kaur H, Jain S, Sharma RL. Duration of reappearance of gingival melanin pigmentation after surgical removal – A clinical study. *J Indian Soc Periodontol* 2010; 14(2):101-105.
10. Humagain M, Nayak DG, Uppoor AS. Gingival depigmentation: A case report with review of literature. *J Nepal Dent Assoc* 2009; 10:53-56.