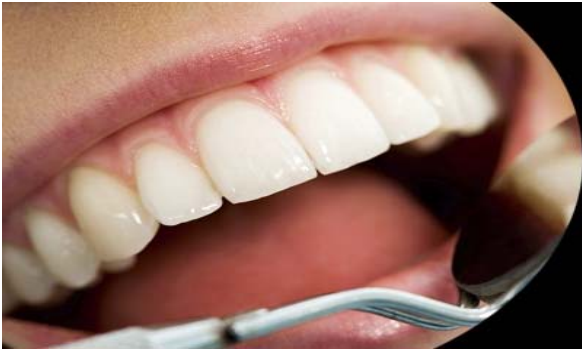



ISSN Print: 2394-7489
ISSN Online: 2394-7497
IJADS 2015; 1(4): 141-144
© 2015 IJADS
www.oraljournal.com
Received: 14-08-2015
Accepted: 16-09-2015

Dr. Savitri D
Post graduate student,
Department of conservative
dentistry and endodontics,
Krishnadevaraya college of
dental sciences, Bangalore.

Dr. Rahul Singh
MDS, Department of
conservative dentistry and
endodontics.

Dr. Sujatha I
Professor, Department of
conservative dentistry and
endodontics, Krishnadevaraya
college of dental sciences,
Bangalore.

**Dr. Siddapur Mathada Sharath
Chandra**, Professor and HOD,
Department of conservative
dentistry and endodontics
Krishnadevaraya college of
dental sciences, Bangalore.

Correspondence

Dr. Savitri D
Post graduate student,
Department of conservative
dentistry and endodontics,
Krishnadevaraya college of
dental sciences, Bangalore.

Endodontic treatment of mandibular first premolar with two roots dividing at two different levels report of two cases

Savitri D, Rahul Singh, Sujatha I, Siddapur mathada Sharath Chandra

Abstract

Mandibular premolars are known for having an aberrant anatomy. Often considered as enigma to the endodontist, the mandibular first premolars have high flare-up and highest failure rates because of extreme variations in root canal morphology [1-3]. The incidence of two roots in mandibular first premolar is quite rare (1.8%) [4]. Root canal morphology can be complex and requires careful evaluation for root canal therapy. This paper attempts at explaining the endodontic management of two rare cases of mandibular first premolars with two roots dividing at two different levels.

Keywords: Mandibular first premolars, Root morphology, two roots, endodontic treatment.

1. Introduction

A detailed knowledge of morphology of root canal system and its variations, thorough cleaning and shaping followed by 3D obturation of root canal system is required for successful management of infection in root canal system [5, 6]. Slowey has suggested that mandibular premolars, often called as “endodontist’s enigma”, may present the greatest difficulty of all teeth to perform successful endodontic treatment [2]. A study done at university of Washington in 1995 evaluated the failure rate of root canal therapy in all teeth, results showed that mandibular first premolar had the highest failure rate in study at 11.45% [2, 3]. A higher incidence of two canals in mandibular first premolars was reported in several populations, upto 50% in Indian populations [7, 8]. They are more prone to bifurcation of canals (23-30%) and terminating in multiple apical foramina (15-20%) [9]. The presence of two distinct roots in mandibular first premolars is quite rare and has been reported to be only 1.8% [10]. A thorough knowledge of root canal space anatomy is a basic prerequisite for the successful completion of endodontic treatment especially in cases where extra rootcanals are expected [11-13].

2. Case Reports

2.1 Case-I

A 32 year old male patient reported to the department of conservative dentistry and endodontics with the chief complaint of decayed tooth in the lower left back tooth region. Patient’s medical history was non-contributory. Clinical examination revealed deep caries in #34. vitality tests on the involved tooth (#34), showed no response to cold and heat tests and EPT suggesting the tooth to be non vital. Radiographic examination revealed caries extending to pulp and an unusual root anatomy, i.e, mesial and distal roots bifurcating at the coronal third of roots resembling that of a molar tooth with no periapical changes. (Fig-1a)

The clinical, radiographic examination and vitality tests led to a diagnosis of asymptomatic irreversible pulpitis of #34 requiring endodontic therapy. The tooth was anaesthetized followed by isolation of tooth using rubber dam. Access cavity was prepared with a round diamond bur in a high speed aerator hand piece. A sharp DG16 explorer was used to locate the mesial and distal canal orifices, and the access was modified accordingly. The orifices were enlarged with Gates glidden drills # 3&2. Pulp extirpation was done and after confirming the canal patency, size 10k (malleifer) files were inserted and working length determined using radiograph and root ZX apex locator.

Cleaning and shaping of the canals were performed using step back technique upto size 50k file under copious irrigation with 5.25% NaOCl and saline in between each instrument. The apex of both canals was enlarged upto size 35 K file. Master cone was selected. (Fig-1b) Subsequently both the canals were

obtured with cold lateral condensation technique using guttapercha cones and zinc oxide eugenol sealer. A post obturation radiograph was taken (Fig-1c). After 1 week tooth was asymptomatic hence restored with permanent restoration.

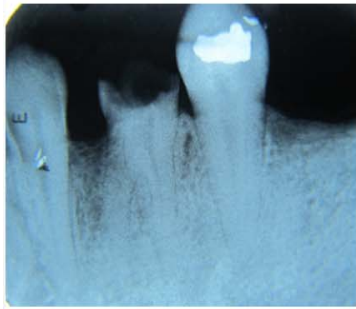


Fig-1a

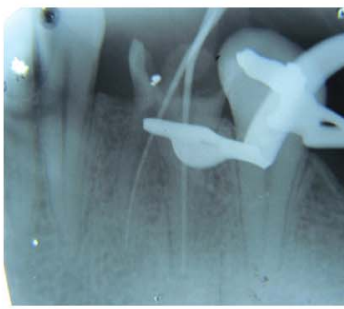


Fig-1b

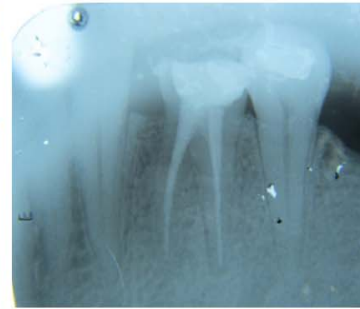

Fig-1c

2.2 Case-II-

A 25 year old male patient reported to the department of conservative dentistry and endodontics with the chief complaint of pain in the lower right back tooth region for the past two days. History revealed that patient had spontaneous and lingering pain on taking cold and hot foods. Patient's medical history was non-contributory. On performing cold test, patient had lingering pain after removal of stimulus and delayed response to hot stimulus. On performing EPT tooth showed early response. Clinical examination revealed deep caries in #44. Tooth was tender on percussion. Radiographic examination of tooth #44 indicated caries extending to the pulp chamber. The root canal anatomy was suggesting two roots (Fig-2a). A second radiograph was taken with more mesial angulation for clear view (tube shift technique). Two roots were found and were distinguished as buccal and lingual based on clark's SLOB rule. The two distinct roots divided at mid root level, also there was widening of apical periodontium. The diagnosis of symptomatic irreversible pulpitis was made

necessitating root canal therapy for #44. (Fig- 2b)

A standard endodontic procedure was carried out and after deroofting the pulp chamber, two distinct canal orifices were found under the buccal and lingual cusps respectively. The orifices were enlarged with GG drills #3&2. After obtaining the canal patency, size 10 k (malleifer) files were inserted and working length was determined using radiograph taken with mesial angulation and confirmed with Root ZX apex locator (Fig-2c).

After establishing a glide path with size 10 and 15 k (malleifer) files, both the canals were shaped with a crown down technique till protaper F2 files. In between instrumentation, copious irrigation was done with 5.25% NaOCl and saline and recapitulated with smaller files. Master cone was selected (Fig-2d). Both the canals were obtured with protaper guttapercha points and zinc oxide eugenol sealer. After 1week tooth was asymptomatic and hence restored with permanent restoration.

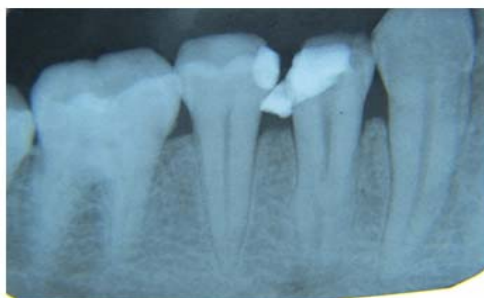

Fig-2a

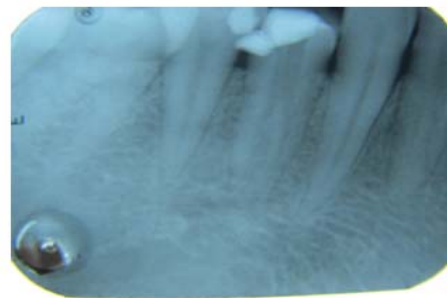


Fig-2b




Fig-2c

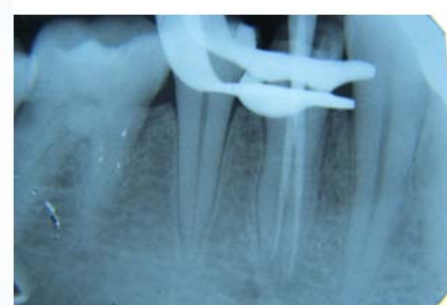

Fig-2d

3. Discussion

Anatomical variations, especially extra canals and roots, should always be kept in mind when treating teeth endodontically. The primary cause of endodontic failure is overlooked root canals [14, 15]. Numerous methods have been used for studying root canal anatomy, including replication techniques, ground sections, clearing techniques and radiography [9]. The presence of extra roots or canals in mandibular premolars is undoubtedly an endodontic challenge. Scott and Turner describe the accessory root of mandibular first premolar as TOME'S ROOT [16]. They observed ethnic differences in the root morphology and reported the highest incidence (>25%) of accessory roots in Australian and sub Saharan African populations. The lowest incidence (0-10%) of tomes root occurred in American, Arctic, New Guinea, Jomon, and Western Eurasian populations. According to Green *et al.*, incidence of two roots, two foramina is 4% [1].

A study of full mouth radiographs from 1000 patients by Amos (74) in 1955 not only reported on bifurcated canal systems of mandibular first premolar teeth but also inferred a higher incidence in canal bifurcation in African American patients compared to Caucasian patients. A study by Trope *et al.* indicate that 10.9% of the patients had at least one mandibular premolar with two roots [4]. Certain population and geographic groups have little or no data regarding mandibular premolar morphology, especially in south American African, Australian and south East Asian populations. In a review of mandibular first and second premolars presented by Cleghorn *et al.* reported that approximately 98% of mandibular first premolars were single rooted with single canal present in 75.8% of teeth [9].

Accurate pre-operative radiographs and their careful examination are essential to detect root canal morphology and anatomy. The clinician should carefully trace the exterior and interior outlines of the tooth in radiograph with adequate magnification [17]. The interpretation of the periodontal ligament space may suggest the presence of an extra root or canal [18]. Martinez-lozano *et al.* recommend upto 40° mesial angulation from horizontal more reliable in identifying the extra canals. Deviation of the xray angle from the vertical axis of 15°-30° was effective only in the mandibular first premolar in helping to visualize canal anatomy of premolar teeth. A study of Yoshioka *et al.* showed that sudden narrowing of the main canal on the parallel radiograph was a good criterion to judge root canal multiplicity [4].

Special attention must be given to the preparation of a access cavity that is the key to find all orifices under successful treatment. Because of absence of direct access, cleaning, shaping and filling of these teeth can be extremely difficult. Failure to recognize the presence of extra root or canals can often lead to acute flare ups during treatment and subsequent failure of endodontic therapy. Proper access into pulp chamber is necessary as it is relatively small with reduced visualization in premolars [18]. It can be improved by enlarging main canal with GG drills. A good tactile sense and pre curving the instruments before negotiating can be helpful. After access opening, use of ocular loops or endodontic microscope, as well as additional lighting (fiber optic illumination) is very useful and makes treatment easier additionally the use of dyes like methylene blue and performing "champagne test" using NaOCl are valuable aids [17-20].

Before access opening, utilizing the advanced technology like CBCT makes easier for clinician to treat and identify the missed canals. Cone beam volumetric tomography (CBVT) ensures elimination of superimposition of anatomic structures,

an undistorted 3D image with lower effective radiation compared to CT. It also provides viewing the image in multiple planes [21]. These advanced modes of radiographic imaging and analysis have allowed for in depth knowledge of pulp space anatomy in 3D and allowed for identification of rare aberrations. They include spiral computed tomography (SCT), micro computed tomography (micro CT), CBCT [9]. Piezoelectric ultrasonics in conjunction with innovative new CPR, ultrasonic instruments provides a breakthrough for exploring and identifying missed canals. Micro openers are flexible stainless steel instruments which makes it easier to locate canals [21]. It is recommended that the clinicians should consider using various diagnostic tools in diagnosing and treating mandibular first premolars as it deserves more emphasis because of the complexity in root and root canal morphology.

4. Conclusion

The clinician should have an accurate knowledge about the anatomy of each tooth as well as the possibility of variations, to identify the presence of unusual number of roots and their morphology. Careful interpretation of the radiograph, close clinical inspection of the floor of the chamber and proper modification of the access opening, the position, angulation of the file in the canal also hints about the presence of extra canal and are essential for a successful treatment outcome. The presentation of both these cases of mandibular first premolars with two roots dividing at two different levels further enhances our knowledge about extreme variations encountered in mandibular first premolars and lack of a proper classification will continue to baffle the clinicians in future and many more such variations are possible.

5. References

1. Two-rooted mandibular first premolar: case report Kishore Raju Kothapalli Annals and Essences of Dentistry July – Sept, 2010, II(3).
2. Ingle J, Bakland L. Endodontics, 5th edition, Hamilton: BC Decker, 2002
3. Slowey RR. Root canal anatomy. Road map to successful endodontics Dent Clin North Am 1979; 23(4):555-73.
4. Endod J. Epub 2007 Feb 27. The root and root canal morphology of the human mandibular first premolar: a literature review. Cleghorn BM1, Christie WH, Dong CC 2007; 33(5):509-16.
5. Endod J. Frequency, location, and direction of the lateral, secondary, and accessory canals. De Deus QD 1975; 1(11):361-6.
6. Endod J. Root canal configuration of the mandibular first premolar. Baisden MK1, Kulild JC, Weller RN 1992; 18(10):505-8.
7. Indian J. Dent Res. doi: 10.4103/0970-9290.66626. Assessment of root canal morphology of mandibular first premolars in the Indian population using spiral computed tomography: an in vitro study. Sandhya R1, Velmurugan N, Kandaswamy D 2010; 21(2):169-73.
8. Int Endod J. doi: 10.1111/j.1365-2591.2008.01494.x. Root canal morphology of mandibular first premolars in an Indian population: a laboratory study. Velmurugan N1, Sandhya R 2009; 42(1):54-8.
9. Root Anatomy and Root Canal Configuration of Human Permanent Mandibular Premolars: A Systematic Review. Jojo Kottoor Denzil Albuquerque Natanasabapathy Velmurugan Jacob Kuruvilla Anatomy research international 01/2013; 2013:254250. DOI:

10.1155/2013/254250

10. INGLE 6TH EDITION

11. Endod J. Anatomy of the pulp-chamber floor. Krasner P1, Rankow HJ 2004; 30(1):5-16.
12. IntEndod J. Diagnosis and root canal treatment of a mandibular second premolar with three root canals. Rödiger T1, Hülsmann M 2003; 36(12):912-9.
13. Indian J. Dent Res. Mandibular premolars: aberrations in pulp space morphology. Sikri VK1, Sikri P 1994; 5(1):9-14.
14. Endod J. Mandibular premolar with two roots. Goswami M1, Chandra S, Chandra S, Singh S 1997; 23(3):187.
15. Aust Endod J. Clinical judgement and decision making in endodontics. Messer HH 1999; 25(3):124-32.
16. Scott R, Turner C. The anthropology of modern human teeth. Cambridge: Cambridge university press, 2000.
17. Int Endod J. Diagnosis and root canal treatment of a mandibular second premolar with three root canals. Rödiger T1, Hülsmann M 2003; 36(12):912-9.
18. Endod J. Three canal mandibular first and second premolars: a treatment approach. Nallapati S 2005; 31(6):474-6.
19. Endod J. Epub 2006, Oct 19. Endodontic treatment of a mandibular second premolar with four canals using operating microscope. Tzanetakis GN1, Lagoudakos TA, Kontakiotis EG 2007; 33(3):318-21.
20. Endod J. Root canal treatment in a mandibular second premolar with three root canals. De Moor RJ1, Calberson FL 2005; 31(4):310-3.
21. Indian J. Dent Res. doi: 10.4103/0970-9290.114914. Endodontic retreatment--unusual anatomy of a maxillary second and mandibular first premolar: report of two cases. Shenoy A1, Bolla N, Vemuri S, Kurian J 2013; 24(1):123-7.