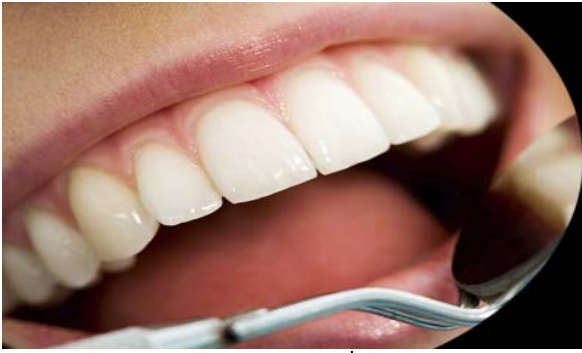



International Journal of Applied Dental Sciences

ISSN Print: 2394-7489
ISSN Online: 2394-7497
IJADS 2015; 1(4): 152-155
© 2015 IJADS
www.oraljournal.com
Received: 17-08-2015
Accepted: 18-09-2015

Dr. Diana George
BDS, Post Graduate Student

Dr. Prashanth Kamath
MDS, Professor and Head of the
Department

Dr. Arun Kumar BR
MDS, Senior Lecturer

Dr. Rajat Scindhia
MDS, Senior Lecturer

Dr. Raghuraj MB
Senior Lecturer

Vertical Dimensional Change Analysis during Smile: A Survey Study

**Diana George, Prashanth Kamath, Arun Kumar BR, Rajat Scindhia,
Raghuraj MB**

Abstract

Introduction: Esthetics is the Greek word for perception, deals with beauty and the beautiful. Esthetics in orthodontics is defined mainly in terms of profile enhancement. Esthetic judgment is made by viewing the patient from the front in dynamic states like conversation, facial expressions, and smiling. Analysis of dimensional changes of smile is an important stage for the diagnosis, treatment planning and prognosis of any dental treatment involving aesthetic objectives. The evaluation of the vertical dimensional changes of the smile is a necessary procedure to achieve consistent form in orthodontic treatments

Aims and Objectives: The objectives of this study were to evaluate and quantify upper lip soft-tissue changes in the vertical dimensions at both rest and maximum smile, to assess the differences of dimensions between the sexes, to assess of differences between subjects with and without gingival display during the smile, quantification of differences in mandibular tooth exposure between the sexes and assessment of differences between different smile pattern groups.

Materials and Methods: Eighty volunteers (40 men, 40 women) aged 20 to 40 (mean 24.76 years) were recruited for this study. For each subject, 10 measurements of upper lip position and maxillary and mandibular incisor crown height at rest and in maximum smile were recorded. The individual measurements were correlated with sex distribution. Also an assessment of smile pattern was done which was correlated with the sexes as well as the 10 individual measurements.

Results: Relaxed and smiling external upper lip length was shorter in the women than in the men. Resting vermilion height and the maxillary central incisor height was also lesser in females than in males. The mean maxillary central incisor display at rest was greater in the women than in the men. A high smile line was 1.5 times more prevalent in the women. The upper lip was shortened by 31% in subjects with a high smile line compared with 39% in subjects with a low smile line.

Conclusions: Thus most of the measured variables like in upper lip length during smiling as well as during resting, maxillary incisor display and the vermilion height showed statistically significant sexual dimorphism.

Keywords: Smile, Vertical dimensional changes, Sexual dimorphism.

Introduction

The importance of beauty and attractiveness is well established in today's society.

A person's psychosocial wellbeing has been established to be dependent on his/her dentofacial attractiveness. Normal dental appearance amongst various personal characteristics is considered to be more socially attractive than those with malocclusions [1].

An important step in creating attractive smiles is an understanding of the factors that help to create an attractive smile. The ability of a clinician to create the desirable smile has been the purpose of the various studies of beauty standards and norms [2].

Beauty is always evaluated subjectively. However, for this adequate tools are required to overcome the challenge of this subjectivity.

"Esthetics" a Greek word is that branch of philosophy that deals with beauty and the beautiful. The term "Esthetics" in orthodontics has been defined mainly in terms of enhancement of the profile.

Orthodontics as a branch involves in recognizing what is interfering with the smile. In orthodontics to establish a treatment plan it is important to diagnose what is abnormal. Certain parameters in functional problems lead us to a diagnosis of the anomalies. Similarly aesthetic problems also require certain parameters in order to quantify the defects and decide on the treatment planning.

Correspondence

Dr. Diana George
Post Graduate Student
Department of Orthodontics and
Dentofacial Orthopaedics
Dr. Syamala Reddy Dental
College, Hospital and Research
Centre #111/1 Sgr Dental College
Rd., MuneKollala, Marathahalli,
Bangalore, Karnataka,
India -560037.

The purposes of this study were to evaluate and quantify soft-tissue changes of the lip in the vertical dimensions at both rest and maximum smile. Assessment of the differences of dimensions between the sexes as well as assessment of differences between subjects with and without gingival display during the smile. The differences in mandibular tooth exposure between the sexes and different smile pattern groups were also quantified.

Materials and Methods

Eighty volunteers (40 men, 40 women) aged 20 to 40 years were recruited for this study. No participants had undergone any previous orthodontic treatment that could affect the vertical position of the central and lateral incisors by either intrusive or extrusive mechanics, maxillofacial surgery or anterior maxillary tooth prosthodontic rehabilitation. According to the requirements of the Institutional Ethics Research Committee all participants had signed the consent form. For each subject, 10 measurements of upper lip position and maxillary incisor crown height at rest and in maximum smiling were recorded.

The age and the sex of the volunteers was recorded. For recording the maximum smile position, each subject was requested to present his or her full smile a few times, and measurements were taken when the subject successfully repeated the full smile pattern.

The following measurements were done on the volunteers:-

1. Resting external upper lip length (mm)- the vertical measurement from the centre of the base of the nose (subnasale) to the inferior border of the upper lip (stomion superioris) (Figure I A)

2. Resting maxillary central incisor length (mm) - the vertical measurement from the lower border of the upper lip to the incisal edge of the left central incisor.
3. Resting vermilion height- the vertical measurement from the upper border of the vermilion at the Cupid’s bow to the lower border of the upper lip (Figure I B)
4. Resting vermilion/external upper lip length ratio
5. Maxillary incisor height (mm) - the vertical measurement from the incisal edge to the highest point on the gingival margin of right maxillary central incisor was taken.
6. Smiling external upper lip length (mm) - the vertical measurement from the base of the nose (subnasale) to the lower border of the upper lip (stomion superioris) while smiling. (Figure II C)
7. Smiling maxillary central incisor display (mm) - the vertical measurement from the incisal edge to the highest point of display of the incisor of right maxillary central incisor (Figure II E)
8. Smiling/resting external upper lip length ratio
9. Smiling gingival display(mm) –the vertical measurement from gingival margin to point of maximum display of gingiva (Figure II D)
10. Smiling mandibular central incisor length (mm) - the measurement of the amount of mandibular incisor visibility vertically on smiling. (Figure II F)

All measurements were recorded by the first author to the nearest millimetre directly on the face using a Digital vernier calliper.-150MM/6 inch (Pia International) (Figure 2)

The smile pattern has been classified according to Tjan *et al.* [3] as follows:-

Smile Pattern	Maxillary Incisor Visibility
Low Smile	<75% Of Clinical Crown Height Of Maxillary Central Incisor
Average Smile	75-100% Of Clinical Crown Height Of Maxillary Central Incisor
High Smile	.100% Of Clinal Crown Height And A Band Of Contiguous Gingiva

Total lip elevation length was defined (smiling maxillary central incisor display + gum exposure in smile – resting maxillary central incisor display) to quantify the vertical exposure capacity of the lip.

This variable is complementary to the smiling/resting external upper lip length ratio variable in representing the upper lip’s vertical contraction during smiling.

Results

Means and standard deviations, derived for all measured variables of the subjects, are reported with some statistical information.

The mean age of the whole study population was 24.76 years. The youngest subject was 20 years old, and the oldest was 40 years old.

The women’s mean age was 24.38 years, and the men’s mean age was 25.15 years.

A statistically significant sexual dimorphism was apparent in many of the measured variables.

1. Relaxed external upper lip length was 1.2 mm shorter in the women than in the men (P<0.05).
2. The mean maxillary central incisor display at rest was 0.6 mm greater in the women than in the men (P<0.05).
3. The resting vermilion height is 0.8 mm shorter than in men (p < 0.05).
4. The maxillary incisor height is also 0.37mm lesser in females than in males (p <0.05).

5. The upper vermilion length comprised 72% to 73% of the external upper lip length.
6. Smiling external upper lip length is also 0.89mm lesser in females than in males (p<0.05) resulting in a greater gingival display and/or incisal visibility in females compared to males while smiling.
7. A high smile line in which 100% OF CLINAL CROWN HEIGHT AND A BAND OF CONTIGUOUS GINGIVA is visible is seen in 42.5% of the entire population. It is more prevalent in females (52.5%) than in males (32.5%).
8. A low smile line in which <75% OF CLINICAL CROWN HEIGHT OF MAXILLARY CENTRAL INCISOR is visible is seen in lesser percentage of the population i.e.18.89%.According to the study it is more prevalent in females (25%) than in males (12.5%).
9. An average smile line in which 75-100% OF CLINICAL CROWN HEIGHT OF MAXILLARY CENTRAL INCISOR is visible is seen in 38.8% of the population. It shows more prevelance in males (55%) than in females(25%) (Figure 3)

Statistical Analysis

- With the Pearsons correlation test a statistically significant difference was seen between the smile patterns in the male and female gender (p<0.05).(Table 1,2)

Table 1: Cross tabulation of smile patterns in both genders

Pattern Gender Cross Tabulation					
		Gender			Total
		Female	Male		
Pattern	Average	Count	9	22	31
		% Within Gender	22.5%	55.0%	38.8%
	High	Count	21	13	34
		% Within Gender	52.5%	32.5%	42.5%
	Low	Count	10	5	15
		% Within Gender	25.0%	12.5%	18.8%
Total		Count	40	40	80
		% Within Gender	100.0%	100.0%	100.0%

Table 2: Statistical analysis using chi square tests

Chi-Square Tests			
	Value	df	P VALUE
Pearson Chi-Square	9.001	2	.011
N of Valid Cases	80		

Significant Difference in the Male and Female Is Seen In the Pattern

- A positive significant association correlation coefficient, 0.363 ($P < 0.01$) was found between upper lip shortening (smiling external upper lip length – resting external upper lip length) and the gap of internal and external lip length (resting external upper lip length – resting internal upper lip length).
- The one way ANOVA test was done and the following results were obtained
 1. The resting and smiling external upper lip length was more in case of the low smile pattern group compared to the average and high smile pattern groups ($p < 0.01$).
 2. The resting vermilion height was also more in the average smile pattern group compared to the low and high smile pattern group ($p < 0.01$).
 3. The smiling maxillary central incisor display is more in the high smile pattern group compared to low and average smile pattern groups ($p < 0.05$).
 4. The resting vermilion/external upper lip length ratio is significantly more in the high smile pattern group compared to the low and average smile pattern groups ($p < 0.01$).
 5. The posthoc tukey test done for a subgroup analysis revealed the following :-
 - The resting and smiling upper lip length was more in the low smile compared to the average and high smile pattern group ($p < 0.001$). It was also significantly more in the average compared to the high smile pattern groups ($p < 0.05$).
 - Resting vermilion height Resting vermilion/external upper lip length was also lower was significantly lower in low smile compared to the the average smile and high smile groups ($p < 0.001$).
 - Smiling maxillary central incisor display is also more in high smile group pattern compared to low and average smile pattern groups ($p < 0.001$).

Discussion

Vertical anterior tooth display is a very important aspect of dental and facial esthetics is the vertical anterior tooth display. Observation of the patient from the front in dynamic states like conversation, facial expressions, and smiling is done to make an esthetic judgement of the patient.

Orthodontists and surgeons have been conditioned since the past to see a high smile line which is defined as gingival smile

line or gummy smile as undesirable aesthetically [4, 5] Depending on the diagnosis of the gummy smile treatment alternatives of gummy smile include various combinations of orthodontics, surgical and periodontal therapy. The effective correction of excessive display of gingiva and anterior maxillary dentition would benefit more from a combined interdisciplinary treatment [6-8] or sometimes an invasive surgical procedure rather than just a conservative orthodontic treatment. However the most important factor to be considered is whether the treatment of gummy smile is warranted. As Peck and Peck [9] claimed “We orthodontists tend to forget that facial esthetics interests all people everywhere, and the ultimate source of esthetic values depends on people and not just ourselves.”

Low smile lines have been found by Peck *et al.* [5] and Tjan and Miller [3] to be predominantly a male feature (2.5 to one male to female) and a high smile line is predominantly female (two to one female to male). Studies conducted by Vig and Brundo [10] have found sexual dimorphism in the smile patterns. These studies suggested that maxillary anterior tooth display to be almost double that of women as compared to men. Also females were found to be twice as likely as males to have a gummy smile.

The meaning of the form concept is that when we observe a particular facial pattern repeatedly, the chances of us perceiving it as “correct” is more likely. It was expected that excessive gingival display in maxillary arch will be more acceptable as aesthetic for females, whereas lower excessive gingival display will be more acceptable for male Gingival and tooth exposure during smiling are challenging issues to many dental practitioners especially those who deal with smile aesthetics. Excessive display of teeth and gingival tissues is considered by many to be unattractive and usually requires intervention [11].

Data from this study, similar to other studies, clearly indicate sexual dimorphism in lip and tooth measurements. These differences are reflections of the simple biological fact that male subjects are uniformly larger than equivalent female subjects. The upper lip at rest and smiling were 1.2 mm and 0.9mm respectively shorter in the women than in the men ($P < 0.01$), and maxillary incisor exposures at rest were 0.6 mm more in the women than in the men ($P < 0.01$).

Peck *et al.* [5] who recorded vertical measurements in young orthodontic patients (mean age, 15 years), observed that the difference in upper lip length between the sexes was only 2.2 mm, and that tooth exposures at rest were 5.3 mm in the girls and 4.7 mm in the boys.

The clinical central incisor crown was 0.4 mm shorter in the women than in the men, slightly less than the difference observed by Peck *et al.* [5].

Although not statistically significant the results showed that the smiling mandibular central incisor length was more in women than in men.

Our findings suggest that a high smile pattern can be considered a female norm, since more than half of the women in this study exposed their gums while smiling, and a low smile pattern can be considered a male norm.

From the study we also find out that the upper lip contraction is more in the low smile pattern group (39%) compared to the high smile pattern groups (31%). This is contrary to the study by Peck *et al.* [5] where subjects with high smile pattern (more than 2 mm of gingival exposure in maximum smiling) had 20% more muscular capacity to raise the upper lip than did subjects without a gummy smile.

In contrast to a previous report, upper lip changes with aging were not observed in the study population. The young and narrow age distribution in this study is 1 reason that no age-related changes were observed.

Some pitfalls of this study were related to the selection criteria of the patient sample. Standard age and sex groups should be determined to eliminate any age-related soft-tissue changes, and previous plastic or aesthetic interventions should also exclude patients from the study. Also the smile has been quantified only in the vertical dimension. The smile in the horizontal dimension should also be quantified.

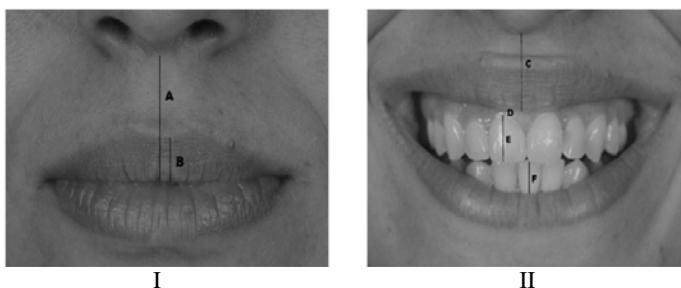

Fig 1: vertical measurements:

I-at rest

II-smiling (A-resting external upper lip length B-resting vermilion height C-smiling external upper lip length(mm) D- smiling gingival display(mm) E- smiling maxillary central incisor display (mm) F-smiling mandibular central incisor length (mm))




Fig 2: Digital vernier calliper.-150MM/6 inch (Pia International)

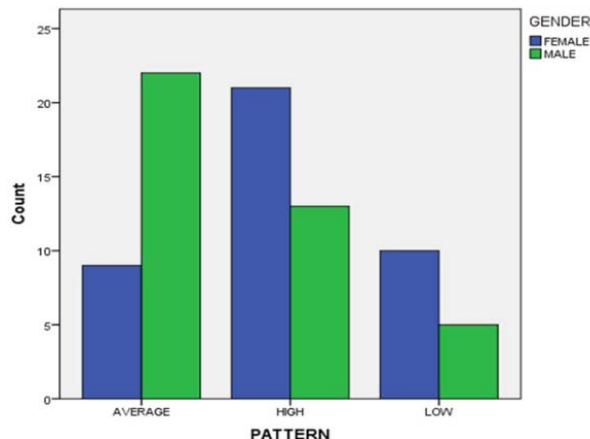


Fig 3: Sexual dimorphism and prevalence of various smile patterns in study group

Conclusion

Data from this study clearly indicates a clear sexual dimorphism in upper lip length during smiling as well as during resting, maxillary incisor display and the vermilion height. Higher smile patterns are more common among female patients, and lower smile patterns are more common among male patients. Also on comparing the high smile pattern with low and average smile pattern groups the observations showed that Resting and smiling upper lip length was lesser, resting vermilion height was more and resting vermilion/external upper lip length ratio is also higher.

Reference

- Howells, David J. The validity and reliability of ratings of dental and facial attractiveness for epidemiologic use. *Am J Orthod.* 1985; 88:402-408.
- Rodriguesa C, Magnanib R, Machadoc MSC, Oliveira OB. The Perception of Smile attractiveness. *Angle Orthod* 2009; 79:634–639.
- Tjan AH, Miller GD, The JG. Some esthetic factors in a smile. *J Prosthet Dent.* 1984; 51:24.
- Janzen EK. A balanced smile—a most important treatment objective. *Am J Orthod.* 1977; 72:359–372.
- Peck S, Peck L, Kataja M. The gingival smile line. *Angle Orthod.* 1992; 62:91–100.
- Garber DA, Salama MA. The aesthetic smile: diagnosis and treatment. *Periodontol* 2000. 1996; 11:18-28.
- Allen EP. Use of mucogingival surgical procedures to enhance esthetics. *Dent Clin North Am.* 1988; 32:307-329.
- Ezquerria F, Berrazueta MJ, Ruiz-Cappilas A, Sainz Arregui J. New approach to the gummy smile. *Plast Reconstr Surg.*1999; 104:1143-1999.
- Peck S, Peck H. A concept of facial esthetics. *Angle Orthod* 1970; 40:284-318.
- Vig RG, Brundo GC. The kinetics of anterior tooth display. *J Prosthet Dent.* 1978; 39:502-504.
- Gerona S, Ataliab W. Influence of Sex on the Perception of Oral and Smile Esthetics with Different Gingival Display and Incisal Plane Inclination. *Angle Orthod* 2005; 75:778-784.