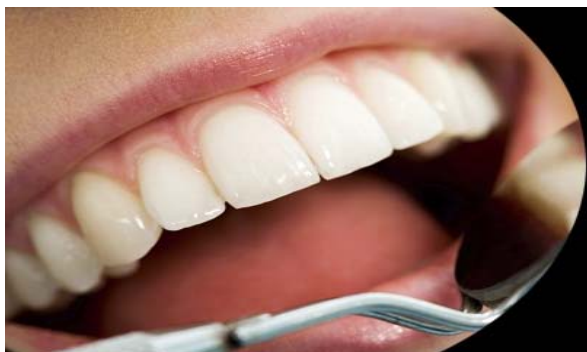



## International Journal of Applied Dental Sciences

ISSN Print: 2394-7489  
ISSN Online: 2394-7497  
IJADS 2015; 1(5): 10-12  
© 2015 IJADS  
www.oraljournal.com  
Received: 03-10-2015  
Accepted: 04-11-2015

### Dr. Pavan Gujjar

BDS, MDS, Senior Lecturer,  
Department of Oral and  
Maxillofacial Pathology,  
Narsinhbhai Patel Dental  
College and Hospital Visnagar,  
Gujarat, India.

### Dr. Priya Sahni

BDS, MDS, Professor & Head,  
Department of Oral and  
Maxillofacial Pathology,  
Narsinhbhai Patel Dental  
College and Hospital Visnagar,  
Gujarat, India.

### Dr. Jayadeva HM

BDS, MDS, Reader, Department  
of Oral and Maxillofacial  
Pathology, Narsinhbhai Patel  
Dental College and Hospital  
Visnagar, Gujarat, India.

### Dr. Shylaja MD

BDS, MDS, Reader, Department  
of Oral and Maxillofacial  
Pathology, Narsinhbhai Patel  
Dental College and Hospital  
Visnagar, Gujarat, India.

### Correspondence

#### Dr. Pavan Gujjar

BDS, MDS, Senior Lecturer,  
Department of Oral and  
Maxillofacial Pathology,  
Narsinhbhai Patel Dental  
College and Hospital Visnagar,  
Gujarat, India.

## Monostotic fibrous dysplasia of mandible: Report of a case in a young female

Dr. Pavan Gujjar, Dr. Priya Sahni, Dr. Jayadeva HM, Dr. Shylaja MD

### Abstract

Fibrous dysplasia (FD) is a skeletal developmental disorder of the bone-forming mesenchyme that manifests as a defect in osteoblastic differentiation and maturation. It is a lesion of unknown etiology, uncertain pathogenesis, and diverse histopathology. FD represents about 2%-5% of all bone tumors and over 7% of all benign tumours. Hereby we are presenting a case of 18 year old female patient who had a chief complaint of bony swelling in the right back region of lower jaw. The histopathological examination revealed the diagnosis of monostotic type of FD.

**Keywords:** Fibrous dysplasia, Craniofacial, Mandible.

### Introduction

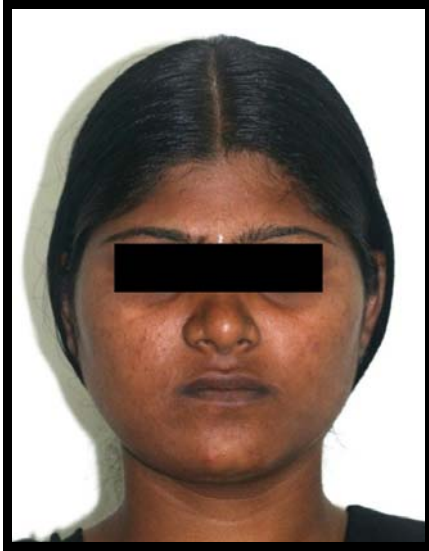Fibrous dysplasia (FD) is a bone developmental anomaly characterized by proliferation of fibrous tissue within the medullary bone, with secondary bony metaplasia, producing immature, newly formed and weakly calcified bone, without maturation of the osteoblast which appears radiolucent on radiographs, with the classically described ground-glass appearance [1]. It is a benign bone disorder of an unknown etiology, uncertain pathogenesis and diverse histopathology [2]. Fibrous dysplasia is described in terms of three major types: monostotic, involving a single bone; polyostotic, having multiple lesions involving multiple bones; and McCune Albright syndrome, a polyostotic form of fibrous dysplasia that also involves endocrine abnormalities. The monostotic form of fibrous dysplasia is the most common, comprising 70% of cases, most likely to occur at puberty. A typical monostotic lesion, usually presented unilateral, will involve the femur, tibia or ribs, with 25% occurring in the bones of the skull. Affection of the craniofacial bone is observed with 10% of the patients suffering from monostotic FD [3,4].

Twenty-five percent of fibrous dysplasia involves two or more bones. These lesions may be localized to one region of the body or they may be disseminated, involving virtually every bone. They are more likely to continue to progress even after puberty. These lesions tend to be structurally weak and are therefore prone to pathologic fracture. Alkaline phosphatase may be elevated in up to 30% of patients with polyostotic fibrous dysplasia, and a dramatic rise may herald malignant degeneration.

Malignant degeneration occurs in less than 1% of cases of fibrous dysplasia. For unknown reasons, monostotic and craniofacial lesions have the greatest potential for malignant degeneration. Pain, rapid growth of a lesion and a dramatic elevation of alkaline phosphatase may represent malignant transformation. Fibrous dysplasia represents about 2- 5% of all bone tumors and over 7% of all benign tumors [5]. There is a female predilection in Polyostotic fibrous dysplasia, and up to 50% may involve bones in the head and neck. Monostotic fibrous dysplasia will occur more commonly at mean age of 25 years [6]. Here we present a case of monostotic fibrous dysplasia of mandible affecting in 18 years old female.

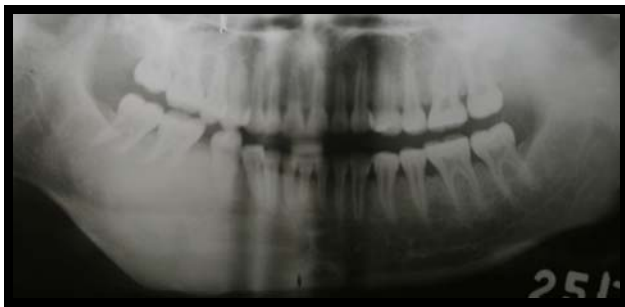### Case Report

An 18 year old female patient presented with a chief complaint of bony swelling at right lower back region of the jaw since 3 months. The swelling was ill defined extending from antero-posteriorly from the parasymphysis region till the angle of mandible. Overlying skin appeared normal (Fig-1).



**Fig 1:** Extra- Oral Photograph

Intraorally vestibular obliteration was seen. Panoramic view was showing ill-defined radio-opacity showing a ground glass appearance involving lower border of the mandible extending upto alveolar ridge causing displacement of 2<sup>nd</sup> premolar (Fig-2).

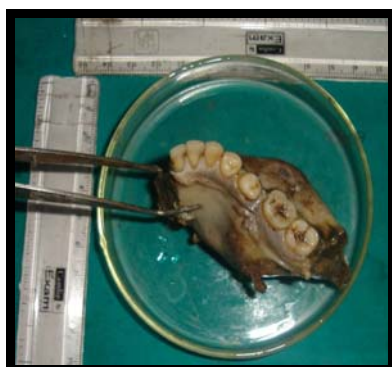

**Fig 2:** Panoramic radiograph showing Ground glass appearance on right side of mandible

With the above findings provisional diagnosis of fibro osseous lesion was given.

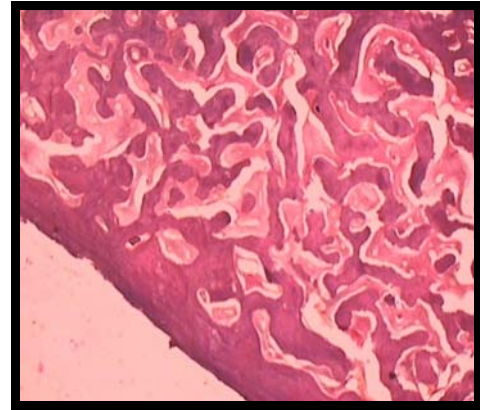
The patient was taken for surgery and the segmental resection of the mandible from the midline to 2<sup>nd</sup> molar was done and was sent for histopathological examination.

On gross examination the resected mandibular specimen was approximately measuring around 8 cmx4cmx3cm in dimension which was extending from mesial of 41 to distal surface of 47. Bony swelling was seen in the premolar to molar region, the swelling was hard in consistency with buccal and lingual cortical plate expansion (Fig-3).



**Fig 3:** Gross specimen showing segmental resection of mandible

The core of the specimen was dissected and kept under decalcification. H&E section of decalcified section revealed immature trabeculae in the arc shaped pattern resembling Chinese letter. The trabeculae were not lined by osteoblasts. The connective tissue was very sparse. The lesional tissue was blending with the surrounding normal bone (Fig-4). Correlating clinically histopathology was suggestive of Monostotic Fibrous dysplasia.



**Fig 4:** H & E (10X) magnification showing immature trabeculae with Chinese letter pattern

**Discussion**

The term fibrous dysplasia (FD) was introduced by lichenstein in 1938. But this type of bony abnormality was first identified by McCune and Bruch in the previous year, they suggested that this type of lesions should be considered as a distinct clinical entity rather than a normal bony lesion. Reed’s definition states that FD is an arrest of bone maturation, woven bone with ossification resulting from metaplasia of a nonspecific fibro osseous type [7]. The etiology of this abnormal growth process is related to a mutation in the gene that encodes the subunit of a stimulatory G protein (G $\alpha$ ) located on chromosome 20 [1, 2]. As a consequence of this mutation, there is a substitution of the cysteine or the histidine-amino acids of the genomic DNA in the osteoblastic cells-by another amino acid, arginine [5]. Consequently, the osteoblastic cells will elaborate a fibrous tissue in the bone marrow instead of normal bone.

A recent study described various forms of FD occurring within a Hong Kong population. The forms were distributed as follows: 74% monostotic, 13% polyostotic and 13% craniofacial. The monostotic form generally occurs during the second decade of life and becomes dormant by the third decade. With initial development of fibrous dysplasia the patient usually reports facial swellings and asymmetries. Although the lesion is usually asymptomatic, encroachment on canals and foramina, as well as limitations of movement, may encounter complaints of pain and discomfort. In general, males and females are thought to be affected evenly [8], although recent research has shown a slight female predominance as is seen in our case. The lesions of fibrous dysplasia are twice as common in the maxilla as the mandible, and the posterior aspects of the jaw are more frequently affected than the anterior [9], in contrast we are presenting a case of monostotic FD involving right half of the mandible. Radiographically FD will show ground glass appearance and the lesional tissue mass will displace mandibular canals and also teeth associated with it [8], similarly in our case it showed a ground glass appearance radiographically and also displacement of 46 and 47 teeth from their occlusal axis with the inferior displacement of mandibular canal.

Central ossifying fibroma (COF), central giant cell granuloma (CGCG), aneurysmal bone cyst and osteomyelitis are few important lesion to be taken care in the initial stage of FD diagnosis, because clinical and radiological features of above lesion are similar to the initial stage of FD<sup>[10]</sup>.

Early stage of FD and above listed lesions all will show swelling clinically and radiographically as a radiolucent lesion. Osteomyelitis in contrast to FD will always associated with a caries tooth and in chronic cases sinus drainage is seen.

Histopathology is the gold standard technique in diagnosing any lesion, so as FD. FD shows cellular connective tissue stroma comprising of woven bone it will be arranged in the various shapes of trabeculae. These different shaped woven bone trabeculae is being compared to Chinese letters, always the lesional tissue will be blending with the adjacent normal bone and the trabeculae will not be lined by osteoblasts<sup>[6]</sup>.

In contrast to FD, COF will show a cellular or sclerotic fibrous connective tissue stroma containing numerous osseous trabeculae of various sizes associated with prominent osteoblasts with a mixture of lamellar or woven bone with cementum like calcifications<sup>[11]</sup>. Osteomyelitis demonstrates sclerotic bone showing alternating areas of apposition and resorption. Between the bony trabeculae lies fibrous connective tissue infiltrated by chronic inflammatory cells. In comparison to FD, CGCG will be showing numerous multinucleated giant cells and numerous areas of hemorrhage. The connective tissue stroma is very cellular consisting of plump cells<sup>[12]</sup>.

### Conclusion

Fibro-osseous lesions is a very vast group of lesions, FD is one of the rare lesions which comes under the above category. The early diagnosis of FD is very important since 1% will turn into malignancy. About 30% of monostotic FD occurs in cranial and facial bones, it becomes a very important differential diagnostic lesions when a dentist is examining any facial asymmetry.

### References

1. Ben hadj Hamida F, Jlaiel R, Ben Rayana N. Craniofacial fibrous dysplasia: a case report. *J Fr Ophtalmol.* 2005; 28(8):e6.
2. Ozek C, Gundogan H, Bilkay U, Tokat C, Gurler T, Songur E. Craniomaxillofacial fibrous dysplasia. *J Craniofac Surg.* 2002; 13(3):382-389.
3. Ameli NO, Rahmat H, Abbassioun K. Monostotic fibrous dysplasia of the cranial bones: report of fourteen cases. *Neurosurg Rev* 1981; 4(2):71-77.
4. Zenn MR, Zuniga J. Treatment of fibrous dysplasia of the mandible with radical excision and immediate reconstruction: case report. *J Craniofac Surg.* 2001; 12(3):259-263.
5. Cholakova RP, Kanasirska N, Kanasirski IV, Chenchev AD. Fibrous dysplasia in the maxillomandibular Region – case report. *JIMAB.* 2010; 16(4):10-13.
6. Ganapathy N. Fibrous dysplasia of the jaw. A case report and update on pathogenesis. *JIADS* 2011; 2(2):54-56.
7. Edgerton MT, Persing JA, Jane JA. The surgical treatment of fibrous dysplasia. With emphasis on recent contributions from cranio-maxillo-facial surgery. *Ann Surg* 1985; 202(4):459-479.
8. McDonald-Jankowski D. Fibrous dysplasia in the jaws of a Hong- Kong population: radiographic presentation and systematic review. *Dentomaxillofac Radiol* 1999; 28(4):195-202.
9. White SC, Pharoah MJ. Oral radiology. Principles and interpretation. 5th ed. St. Louis (MO): Mosby Inc, 2004, 485-515.
10. Revel MP, Vanel D, Sigal R. Aneurysmal bone cysts of the jaws: CT and MR findings. *J Comput Assist Tomogr.* 1992; 16(1):84-86.
11. Slootweg PJ. Maxillofacial fibro-osseous lesions: classification and differential diagnosis. *Semin Diagn Pathol* 1996; 13(2):104-112.
12. Petrikowski CG, Pharoah MJ, Lee L, Grace M. Radiographic differentiation of osteogenic sarcoma, osteomyelitis and fibrous dysplasia of the jaws. *Oral Surg Oral Med Oral Pathol Oral Radio Endod* 1995; 80(6):744-750.