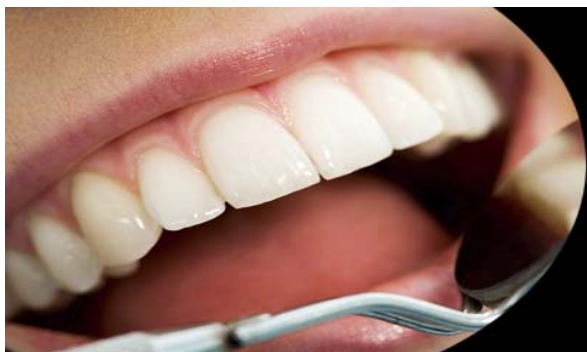



ISSN Print: 2394-7489
ISSN Online: 2394-7497
IJADS 2016; 2(2): 06-10
© 2016 IJADS
www.oraljournal.com
Received: 02-03-2016
Accepted: 03-03-2016

Dr. Rutika R Naik
BDS, MDS Senior Lecturer,
Dept. of Conservative Dentistry
& Endodontics, S B Patil Dental
College, Bidar - 585402,
Karnataka, India.

Dr. Deshpande M Prashanth
BDS, MDS Reader, Dept. of
Conservative Dentistry &
Endodontics, S B Patil Dental
College, Bidar - 585402,
Karnataka, India.

Techniques of root end preparation for the successful peri-radicular surgery: A literature review

Dr. Rutika R Naik, Dr. Deshpande M Prashanth

Abstract

Many approaches to root-end preparation have been advocated, with variations based on access, root anatomy, armamentarium, and surgeon expertise and philosophy. The first is a class I cavity prepared down the long axis of the root within the confines of the canal. Second, a class I cavity is prepared perpendicular to the root face at an approximated angle of 30-45° to the long axis of the root. Third, a vertical slot-type preparation is prepared perpendicular to the long axis of the root with a channel exiting to the facial or buccal. Fourth, a transverse root slot is prepared from either the proximal surface or the buccal surface into the root to the depth of the lingual surface of the root canal before the root end resection. And fifth, reverse canal instrumentation is performed with modified root canal files. These techniques and their variations will be discussed based upon both literature and clinical documentation.

Keywords: Peri-radicular surgery, Root apex, Root end preparation.

1. Introduction

The literature is replete with a myriade of terms describing periradicular surgical procedures. Periradicular is defined as “enclosing or surrounding the root portion of the tooth” [1] The scope of endodontic surgery is not strictly limited to apical procedures, hence the rationale for the term periradicular. Root end preparation and root end filling is a method of sealing the apical extent of the root canal system through cavity preparation in the resected root end and placement of a restorative filling material. The preparation of the resected root to improve the seal of the root canal system is a multiphasic procedure, consisting of hemorrhage control, root isolation and preparation of the root end to receive the filling material. Failure to eliminate the tissue and microorganisms from the canal will invariably lead to failure of the surgical procedure [2].

2. Root End Preparation

2.1 Armamentarium

The ultimate goal of root end preparation is to prepare a class I cavity in the root apex which encompasses the entire visible canal system. Therefore small burs such as # 1/2 or #1 round burs, #33 1/2 or #34 inverted cone burs and #556/700/700R surgical length fissure burs are essential to make the initial cavity outline, depending on the type of preparation chosen. If using a 45° or 90° high speed hand piece, friction grip surgical length burs are recommended for access to the surgical sight. #12 or #14 wheel bur is used to develop mechanical retention in the preparation [3, 4]. Hand instruments such as a small bow type chisel, are especially helpful in preparing of accentuating retention and areas of anastomosis when the proximal root thickness is very thin. A small explorer DG 16 -17: #23, #5 is also essential to evaluate the retention.

Some surgeons prefer the use of a low speed straight hand piece [5-7]. If selected, the same cutting burs are recommended. Also, a good finger rest and stabilization of the handpiece are recommended to control refined cutting in the root apex. The use of a straight handpiece is generally limited to anterior teeth and some premolars. However, usage varies with surgical access and surgeon experience and expertise.

Correspondence

Dr. Rutika R Naik
BDS, MDS Senior Lecturer,
Dept. of Conservative Dentistry
& Endodontics, S B Patil Dental
College, Bidar - 585402,
Karnataka, India.

2.2 Technique of Root – End Preparation

2.2(a): Long Axis Preparation

The ability of the surgeon to prepare a class I preparation into the root canal parallel to the long axis of the canal is dependent on access to the root and availability of proper instrumentation. Invariably, this type of preparation requires the use of miniature handpiece specifically designed for this purpose. These handpiece are angled 2.5 mm high and 4mm wide distal end to facilitate proper root end preparation in the long axis of the canal [8]. Presently available hand pieces require only 10 mm of space above or below the point of entry, thereby making them the instruments of choice when access is limited [9]. Burs available are a #1 round bur and a #34 inverted cone (Fig 1), but sometimes these burs are too large for the root. Failure to consider this lack of anatomical compatibility will lead to root wall perforation or weakening, which may result in an apical fracture.

The preparation begins with a #1 round bur parallel with the long axis, cutting directly into the root canal or filling material present [10]. The recommended depth of preparation has ranged from 1 to 5 mm, with 2 to 3 mm being the most commonly advocated [11].




Fig 1: Miniature handpieces for root-end preparation. Top, micro-handpiece (UBECO); bottom, Dyna Torq (Dyna-Dent).

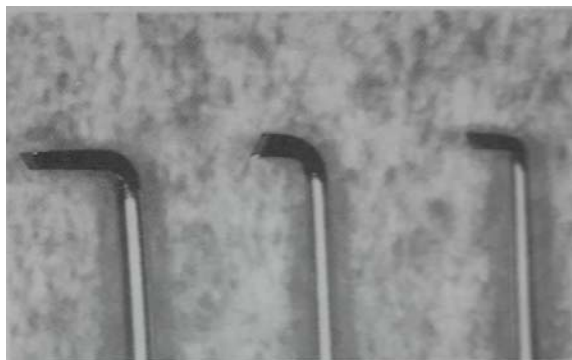


Fig 2: small chisels used to initially prepare a channel in root anastomosis. Left to right, #24, #19, and #25 (Hu-Friedy)




Fig 3: Left, wheel burs used to create mechanical retention. Right, higher magnification of the cutting ends of the wheel bur.

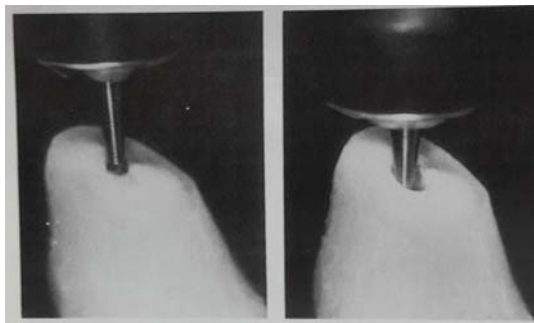


Fig 4: Left, positioning of the bur and handpiece in the long axis of the root. Right, direction and depth of the preparation.

The width of preparation must encompass the visible canal system including anastomoses, when present [12]. Excessive preparation should be avoided and serves no purpose. The ultimate shape of the preparation in cross-section should be an inverted cone [13] with the smallest diameter at the root surface.

Two additional concerns relative to cut dentinal tubules on the resected root surface and the sealing of these entities deserve a brief perspective. In previous years there was a significant concern not only over the potential contamination from micro-organisms and their products leaking from the dentinal tubules [14] but also from the “protoplasmic dentinal fibrillae” [15] which were contained in the dentinal tubules. It was claimed that this material undergo degradation and potentially hinder the healing of the periradicular tissues. The technique recommended sterilization of the cut tubules with silver nitrate to prevent leakage of the toxic material [16]. The silver would combine with the protein contents of the tubules, forming a proteinate of silver, in effect sealing the cut surface. However, studies have questioned the validity of this approach, especially since the silver deposit may interfere with cemental deposition on the cut tubules [17, 18] and serves no antibacterial purpose [19].

A second concern, based on the angle of the resection – Tidmarsh and Arrowsmith [20] have shown that root-ends resected from 45° to 60° have as many as 28,000 tubules/mm² at a point immediately adjacent to the canal. At the cemental-dentin junction, an area which may communicate with the root canal even in the presence of a root-end fill, an average of 13,000 tubules/mm² were found. A variation of the root end preparation technique has been proposed by Sazame [21].

The buccal aspect of the cavity preparation is slanted, created an oblique cut 5 to 6mm into the root end to enhance visibility and access to the root end preparation.

2.2(b): Preparation Perpendicular to the Cut Root Surface

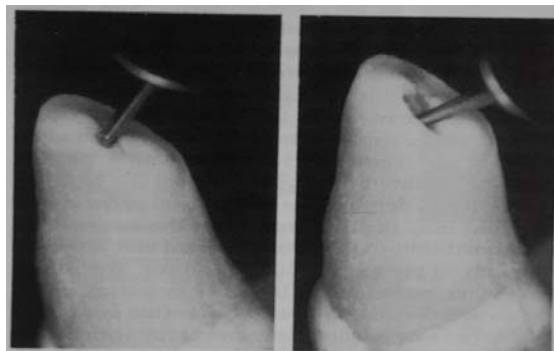


Fig 5: Left, positioning of the bur and handpiece perpendicular to the resected root face, or approximately 45° to the long axis of the root; right, direction and depth of the preparation.

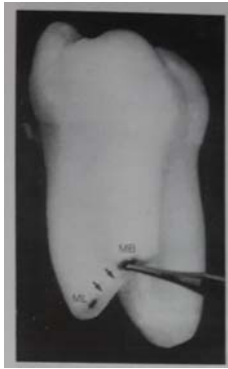

Fig 6 (a): The mesial root of a mandibular molar has been properly beveled towards the buccal exposing the mesial-buccal canal (MB) the mesial-lingual canal (ML), and the uniting anastomosis (arrows). The initial preparation in the root face is made in the MB canal with a small round bur or inverted cone bur.

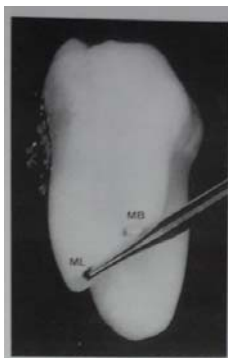


Fig 6 (b): Upon completion of the preparation in the mesial-buccal canal (MB), a long shanked inverted cone bur is positioned at the orifice of the mesial-lingual canal (ML).

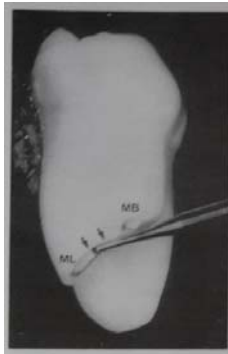


Fig 6 (c): After cutting a preparation in the mesial-lingual orifice (ML), a trough is channeled along the anastomosis (arrows) uniting the MB and ML orifice. Retention is obtained by careful movement of the bur in a mesial or distal direction, slightly undercutting the adjacent walls.

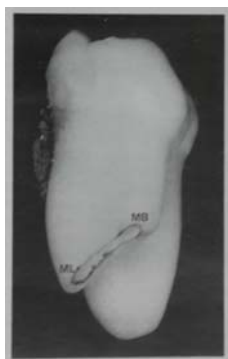


Fig. 6 (d): Lateral view of the finished apical preparation. Note channel uniting MB & ML canals encompasses the anastomoses.

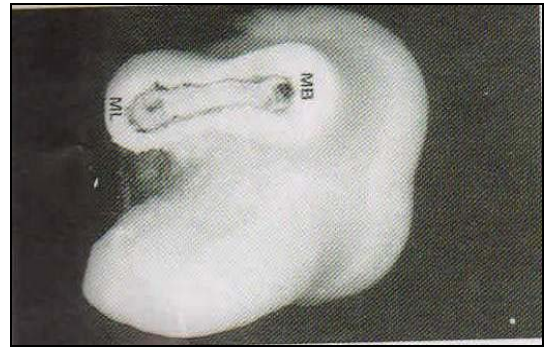


Fig 6 (e): Apical view of the finished preparation in the mesial root prior to placement of a root-end filling. Note dumbbell root shape and preparation of the root within the confines of its external shape to avoid perforation. Reprinted by permission of the publisher from Gutmann JL, Harrison JW. Posterior endodontic surgery: anatomic considerations and clinical techniques. *Int Endod* 1985; 18:8-34.

This technique is probably the most common approach to root end preparation. Its use is dictated by access, root anatomy, armamentarium and surgeon experience. Any style of hand piece can be used with # ½ or #1 round bur to create the initial preparation. This is followed by #33 ½ or #34 inverted cone for retention.

Preparation commences with the placement of the bur perpendicular to the root face. The bur penetrates to an approximate depth of 2 to 3 mm, encompassing the entire outline of the visible canal system. Undercuts are made by lightly rocking the bur in a mesial and distal direction. Buccal retention is achieved with #12 or #14 wheel bur, which can be counter sunk both buccally and proximally along the labial wall of the preparation [22].

On single canalled roots, the preparation will generally be oval to round, or dumbbell-shaped depending on the shape of the cut canal system and root outline. In multiple-canalled roots with distinct foramina, each aperture can be cut as separate class I preparations. When anastomoses are present two approaches can be used. A slot-type preparation is cut from the lingual to the buccal at an approximate angle of 45° to the cut surface [23], exiting at the buccal-most canal flush with the cut root surface. The greatest cavity depth is lingually placed. Retention is achieved moving the bur proximally during the cutting of the slot. However, this approach fails to consider a bulk of reverse filling materials adjacent to the buccal canal and it lacks buccal retention. A second option [24] is to prepare the buccal canal first, perpendicular to the root face, or if possible parallel to the long axis of the root. Subsequently a #33 ½ surgical length bur is used to prepare the slot-type preparation in the manner previously described.

2.2(c): Vertical Slot Preparation

This approach of root-end preparation is often attributed to Matsura in 1962 [25], one has to return to 1914 to discover the true origin and evolution of this technique. According to Martens [26], the development of the vertical slot preparation is attributable to von Hippel [27], with Martens referring to it as the “slitsmethoden”. Von Hippel used this approach to aid in reverse canal instrumentation when a post core was present. In 1950, Ruud [28] modified this technique with the addition of distinct undercut areas for filling retention. Technically, as practiced today, a 5 to 7 mm vertical cut is made with a parallel crosscut, fissure bur (#556/557) from the labial or buccal, to the depth of the lingual wall of the canal. A round bur, slightly larger than the fissure bur, is inserted into the area of the canal and dropped coronally to the base of the vertical cut. The round bur is then pulled out to the labial or buccal,

creating an additional retentive channel. This procedure establishes a dovetailed, retentive cavity with access for placement of a reverse fill from either the buccal root surface or the resected root surface.

Various modifications have been made to the "slitsmetoden". They include the use of a small inverted cone (#34/35) to create lingual retentive undercut, tapered fissure burs to prepare the vertical cut (#700/701), decreasing the depth of the vertical cut from 5 – 7 to 3 – 5 mm, and the elimination of either the labial or the lingual undercut.

2.2(d): Transverse Slot Preparation

This technique is advocated today for periradicular surgery. It was initially advocated Schupfer^[29, 30] and modified by Schoenwolf^[31], although Schuster^[32] performed a similar version of this technique in 1913. A sufficient amount of facial bone is removed to create direct access to the root. A preparation is made prior to root end resection, from the proximal or directly from the buccal into the root to the depth of the lingual wall of the canal, depending on the tooth and its position in the arch. Retention is established internally, similarly to the vertical slot preparation, only rotated 90 degree. Once the preparation is filled the tip of the root is shaved to the amalgam filling at the foramen. Buchs and Reul^[33] Luks,^[34] and Nicholls^[35] have supported the use of roots or lingually placed roots, while Sauveur and Decosne^[36] have recommended it for use with a softened gutta percha technique. Harnisch,^[37] claims this approach should be avoided because it requires the removal of excessive amounts of facial bone. Holland and coworkers^[38], used this technique to evaluate marginal leakage around commonly advocated apical filling materials. They found that root-end preparation techniques down the long axis of the canal provided a better marginal seal than the transverse slot preparation. Few, if any, scientifically sound and clinically appropriate indications exist to support this approach to root-end preparation.

2.2(e): Reverse Canal Instrumentation

This approach to root-end preparation has been advocated when canal cleaning and shaping has not occurred through the crown or the canal space cannot be reached through the crown and periradicular surgery is necessary^[39]. Indications that have been cited include poorly cleaned, shaped, and obturated canals with a post-core present, coronal canal calcification with apical patency, separated instruments in the mid-root, abutment teeth with artificial crowns and short length which require surgery, and a perforation or ledge in the mid-root portion which prevents access to the apical half of the canal. This technique has been suggested for use with or without root-end resection. K-files or Hedstrom files are bent at a 90° angle and held in a hemostat^[40-42] or special holder^[43]. The patent portion of the canal is cleaned and shaped for obturation with gutta-percha point^[44, 45] injected cement,^[46] of reverse silver point fills^[47]. The use of this technique is not recommended to supplant good non-surgical cleaning, shaping, and canal obturation. Furthermore, whenever canal space is visible and accessible, all reasonable attempts to manage this space through the crown and coronal orifice should be used before resorting to reverse instrumentation. Should this technique be indicated, the advent of injectable, thermoplasticized gutta-percha would appear to enhance the surgeon's ability to obturate the canal in a reverse manner, achieving good adaptation to the canal space. However, thorough evaluation of this method of root-end fill is not presently available.

3. Conclusion

The root canal system should be properly cleaned and shaped, thereby removing the major source of irritation for the periradicular tissues coupled with proper obturation, and careful selection of the appropriate apical instrumentation techniques documented above with proper root-end filling along with the removal of necrotic soft and hard tissue in the periradicular area will lead to the successful periradicular surgery. Finally it is essential that the endodontic surgeon be flexible in these surgical approaches, employing various techniques or combinations thereof necessary to achieve the desired results.

4. References

1. An annotated glossary of terms used in endodontics. 4th edition. Chicago: American Association of Endodontists, 1984, 11.
2. Rud J, Andreasen JO. A study of failures after endodontic surgery by radiographic, histologic and stereomicroscopic methods. *Int J Oral Surg.* 1972; 1:311-328.
3. Messing JJ, Stock CJR. A color atlas of endodontics. London: Wolfe Medical Publications Ltd, 1988, 194-224.
4. Gersten H. Surgical endodontics. In: Laskin DN, ed. *Oral and Maxillofacial Surgery.* St. Louis: The CV Mosby Co 1985; 2:143-171.
5. Lubeke RG. *Surgical Endodontics.* DCNA 1974; 18:198-207.
6. Hill TR. Surgical endodontics. In: Harty FG, Roberts DH, eds. *Restorative procedures for the practicing dentist.* Bristol; John Wright and sons Limited, 1974, 204-215.
7. Taylor RG, Doku HC. Root Resection with Amalgam Apical Seal. *Aust Dent J.* 1961; 6:239-242.
8. Tangerud BJ. Den retrograde rotbehandling ved alveotomi. *Nor Tannlaegeforen Tid* 1939; 49:170-175.
9. Arens DE, Adams WR, DeCastro RA. *Endodontic Surgery.* Philadelphia: Harper & Row, 1981, 156-159.
10. Colton MB. A simple rationale root canal therapy employed in conjunction with apical resection and curettage. *J Am Dent Assoc.* 1936; 23:2128-2132.
11. Rud J, Andreasen JO. Operative procedures in periapical surgery with contemporaneous root filling. *Int J Oral Surg.* 1972; 1:297-310.
12. Gutmann JL, Harrison JW. Posterior endodontic surgery: anatomical considerations and clinical techniques. *Int Endod J.* 1985; 18:8-34.
13. Chimenti C, Maggiore C, Palma G, Rossi F. L'apicoectomia con otturazione retrograda: indicazioni e trattamento. *Dent Cadmos* 1986; 54:83-89.
14. Kronfeld R. Zur Frage der Wurzelspitzenamputaion. *Z Stomatol* 1928; 26:1105-1122.
15. Sommer RF, Ostander FD, Crowley MC. Root resection and curettage. In: *Clinical endodontics.* 3rd edition. Philadelphia: WB Saunders Co, 1966, 367-405.
16. Sommer RF. Essentials for successful root resection. *Am J Ortho Oral Surg.* 1946; 32:76-100.
17. Trice F. Periapical Surgery. *Dent Clin North Am* 1959; 3:735-748.
18. Ross WS. Apicoectomy in the treatment of dead teeth. *Br Dent J.* 1935; 58:473-486.
19. Hartzell TB. Apicoectomy – its indications & contraindications and root canal technic. *J Nat Dent Assoc.* 1920; 7:705-716.
20. Tidmarsh BG, Arrowsmith MG. Dentinal tubules at the root ends of apicectored teeth: a scanning electron microscopic study. *Int Endod J.* 1989; 22:184-189.

21. Sazama L. Resekce Korenovych Hrotu. Prague: avicenum, 1978, 1-65.
22. Gerstein H. Surgical endodontics. In: Laskin DN, ed. Oral and Maxillofacial surgery. St Louis: The CV Mosby Co., 1985; 2:143-171.
23. Block RM, Bushell A. Retrograde amalgam procedures for mandibular posterior teeth. *J Endod* 1982; 8:107-112.
24. Guttman JL, Harrison JW. Posterior endodontic surgery: anatomical considerations and clinical techniques. *Int Endod J*. 1985; 18:8-34.
25. Matsura SJ. A simplified root-end filling technique. *J Mich St Dent Assoc*. 1962; 44:40-41.
26. Martens SD. Rotamputasjoner med retrograde rotfilling. *Nor Tannlaegeforen Tid* 1952; 62; 164-171.
27. Von Hippel R. Zur Technik der Granulomoperation. *Dtsch Monatsschr Zahnheilkd* 1914; 32:255-265.
28. Ruud AF. Slitsmethoden ved retrograd rotfylling. *Nor Tannlaegeforen Tid* 1950; 60:471-479.
29. Schupfer C. Uber ein neues Verfahren zur Abdichtung der Wurzelkanale fur Wurzelspitzenresektionen in besonderen Fallen. *DZW* 1935; 38:741-742.
30. Schupfer C. A new method for dense closure of root canals during apical resection in difficult cases. *Dent Items Int* 1936; 58:367-370.
31. Schonwolf H. Beitrag zu der Veroffentlichung von Schupfer: Ueber ein neues Verfahren zur Abdichtung der Wurzelkanale fur Wurzelspitzenresektionen in besonderen Fallen. *DZW* 1935; 38:1029.
32. Schuster E. Die Sektion der Zahnwurzel. *Dtsch Monatsschr Zahnheilkd* 1913; 31:43-47.
33. Buchs H, Reul L. Zur Frage der Knochenregeneration nach Wurzelspitzenresektion mit retrograder Abfullung. *Dtsch Zahnartzl Z* 1962; 17:1635-1644.
34. Luks S. Practical endodontics. Philadelphia: JB Lippincott Co, 1974, 142-155.
35. Nicholls E. Retrograde filling of the root canal. *Oral Surg* 1962; 15:463-473.
36. Sauveur G. Decosne A-M. Etancheite gutta en chirurgie endodontique. *Rev d'Odontol-Stomatol* 1988; 17:239-249.
37. Harnisch H. Apicoectomy. Berlin: Quintessenz Verlag GmbH, 1975, 101-108.
38. Holland R, DeSouza V, Pannian R, Nery MJ, Bernabe PFE, DeMello W. Estudo in vitro da infiltração marginal apos obturacao retrograda ou apicectomia. *Rev Fac Odontol Aracatuba* 1974; 3:23-31.
39. Sommer RF. Essentials for successful root resection. *Am J Ortho Oral Surg* 1946; 32:76-100.
40. Vasiliu D. Technique de l'obturation retrograde du canal radicaire apres La resection apicale. *Rev Stomatol Chir Maxillofac* 1977; 78:483-489.
41. Serota KS, Krakow AA. Retrograde instrumentation and obturation of the root canal space. *J Endod*. 1983; 9:448-451.
42. Reit C, Hirsch J. Surgical endodontic treatment. *Int Endod J* 1986; 19:107-112.
43. Nygaard-Ostby B. Rotspissreskjonens indikasjonsomrade og utforselse. *Nor Tannlaegeforen Tid* 1948; 58:58-86.
44. Garvin MH. Foci of infection in relation to nonvital teeth. *J Nat Dent Assoc* 1919; 6:195-210.
45. Morse D. Clinical endodontology. Springfield, IL; Charles C Thomas, 1974, 469-489.
46. Serota KS, Krakow AA. Retrograde instrumentation and obturation of the root canal space. *J Endod* 1983; 9:448-451.
47. Sommer RF, Ostrander FD, Crowley MC. Root resection and curettage. In: Clinical endodontics. Ed 3. Philadelphia; WB Saunders Co 1966, 367-405.