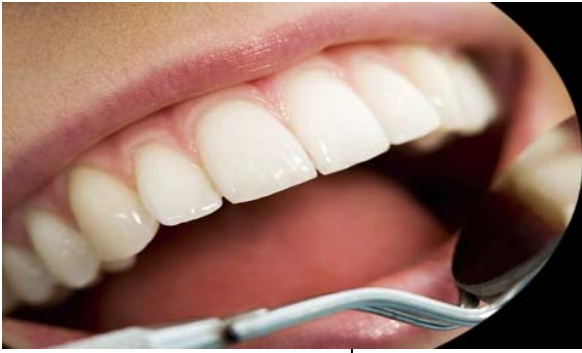



International Journal of Applied Dental Sciences

ISSN Print: 2394-7489
ISSN Online: 2394-7497
IJADS 2016; 2(2): 81-84
© 2016 IJADS
www.oraljournal.com
Received: 12-02-2016
Accepted: 13-03-2016

Dr. Deshpande PM
BDS, MDS Reader, Dept. of
Conservative Dentistry &
Endodontics S B Patil Dental
College & Hospital, Bidar -
585402, Karnataka, India.

Dr. Kirankumar Metta
BDS, MDS, Assistant Professor,
Dept. of Conservative Dentistry
& Endodontics, Ibn Sina
National College for Medical
Studies, Jeddah.

Dr. Prashanth BR
Reader, Dept. of Conservative
Dentistry & Endodontics,
KLE Institute of Dental Sciences
& Research, Bangalore, INDIA.

Dr. Naik RR
Senior Lecturer, Dept. of
Conservative Dentistry &
Endodontics S B Patil Dental
College & Hospital, Bidar -
585402, Karnataka, India.

Adjacent Interproximal caries – The best treatment of choice is mod inlay: A case report

Dr. Deshpande PM, Dr. Kirankumar Metta, Dr. Prashanth BR and Dr. Naik RR

Abstract

The inlay is indicated where in high strength of cast restoration is required. Inlay provides superior control of contact and contours. The cast restoration withstands occlusal forces of mastication and distributes the forces uniformly and directs along the long axis of the tooth structure and thus it prevents tooth fracture. Inlay also conserve the intact facial and lingual enamel and thus the health of the surrounding periodontium is maintained and the gingival attracts less plaque and thus prolongs the longevity of the restoration. In this article a case-report is discussed of MOD cast inlay restoration.

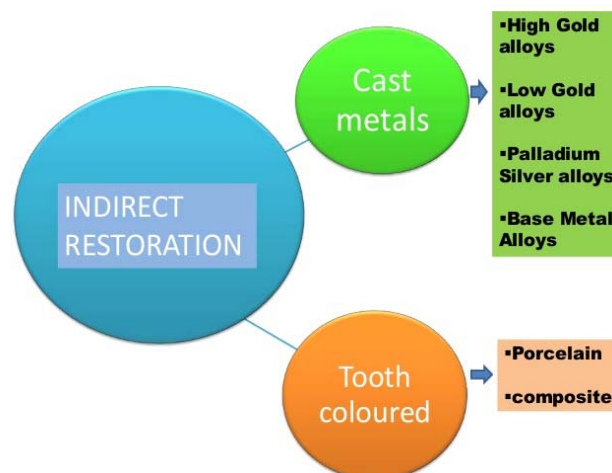Keywords: Adjacent Interproximal, case report, choice

1. Introduction

In the year 1897, Dr. Philbrook was the first to introduce inlay in dentistry who gave the concept of forming an investment around a wax pattern, eliminating the wax, and filling the resultant mold with a gold alloy. And in the year 1907 – Taggart changed the practice of restorative dentistry by introducing his technique for cast gold restorations^[1].

1.1. Definition of Inlay An inlay is defined as a restoration which has been constructed out of the mouth from gold, porcelain or other metal and then cemented into the prepared cavity of the tooth.

2. Classification



3. Indications for Cast Restorations

- A. Extensive tooth involvement.
- B. As an adjunct to successfully periodontal therapy by correction of tooth anomalies which predispose to periodontal problems. Cast restorations can do this by;
 - a. Physiologically restoring and permanently maintaining the dimensions of the contact contour, marginal ridges, and embrasures, which are vital for the health of the periodontium.

Correspondence
Dr. Deshpande PM
BDS, MDS Reader, Dept. of
Conservative Dentistry &
Endodontics S B Patil Dental
College & Hospital, Bidar -
585402, Karnataka, India.

- b. Splinting teeth loosened by periodontitis to a better bone-supported tooth or teeth.
- C. Correction of occlusion
- D. Restoration of endodontically treated teeth.
- E. Support for and preparatory to partial or complete dentures; most removable prostheses will need cast restorations on or in the abutment teeth to hold or accommodate the retainers for the denture.
- F. Retainers for fixed prostheses.
- G. Partial subgingival restorations.
- H. Low incidences of plaque accumulation or decay.
- I. Functionally sound stomato-gnathic system with complete freedom of the mandible to move without any premature contacts.
- J. Cracked teeth (vertically, horizontally, or diagonally).

Contraindications for Cast Restorations

- A. Developing and deciduous teeth.
- B. High plaque/caries indices.
- C. Occlusal disharmony.
- D. Dissimilar metals.

5. Advantages

Cast restorations for single teeth have several advantages over other types of restorations, namely:

- 1. Yield, compressive, tensile and shear strengths of alloys and ceramics used for cast dental restorations are far greater than those of any other materials used intraorally.
- 2. Casting techniques and materials are capable of reproducing precise form and minute detail.
- 3. Any of the metal alloys used for cast restorations contain as one or more of their component metals, a noble or passivated metal.
- 4. The very nature of building a metallic or ceramic restoration instantaneously with a casting procedure, this leads to a strong structure, which is less susceptible to corrosion.
- 5. Cast restorations can be finished, polished or glazed outside the oral cavity.

6. Disadvantages

- 1. Being a cemented restoration, several interphases will be created at the tooth-cement-casting junction.
- 2. Cast restorations necessitate extensive tooth involvement in the preparation.
- 3. The cathodic nature of cast dental alloys toward other metals used in the same mouth may lead to galvanic deterioration.
- 4. The procedure for cast restoration fabrication is lengthy, requiring more than one visit, with temporary coverage between visits.
- 5. Some cast alloys and ceramics have a very high abrasive resistance, much more than that of tooth enamel.

There are five general designs of tooth preparation to accommodate a cast restoration, namely:

- I. Inlays
- II. Onlays
- III. Cast restorations with surface extensions
- IV. Pin-lays
- V. Full veneer cast or cast based restorations.

Tooth preparations for inlay cast restorations

7.1 Indications

These are purely intracoronal restorations, which have limited indications. These are:

- 1. A cavity's width does not exceed one-third the intercuspal distance.
- 2. Strong, self-resistant cusps remain.
- 3. Indicated teeth have minimal or no occlusal facets and if present, are confined to the occlusal surfaces.
- 4. The tooth is not to be an abutment for a fixed or removable prosthesis.
- 5. Occlusion or occluding surfaces are not to be changed by the restorative procedure.

7.2 General shape: (fig 1)

The outline of the occlusal portion of this preparation is dove-tailed. The proximal portion is usually boxed in shape.

7.3 Location of margins

In the occlusal portion, the facial, lingual, and sometimes, proximal margins are located on the inclined planes of the corresponding cusps, triangular ridges or the marginal ridges (crossing ridges). This is designed so that the bucco-lingual width of the cavity preparation (distance measured between the buccal and lingual wall proper), especially at the isthmus portion, does not exceed one-third the intercuspal distance.

Gingival margins should be accomplished with the bevel and not with the wall proper.

7.4 Internal anatomy

In the occlusal portion, the facial and lingual walls and sometimes the proximal walls (if marginal ridge is intact), will be formed of two parts:

- 1. The wall proper, constituting about the pulpal two-thirds of the facial or lingual (proximal) walls, is formed completely of dentin. These walls should taper from each other on the average of 2-5°, or be parallel to each other, if necessary.
- 2. The occlusal bevel, which is a long bevel, constituting almost one-third of the facial and lingual (proximal) walls. This bevelled outer plane of the walls will have an average angulation of 30-45° to the long axis of the crown (or the wall proper).
- 3. In the inlay cavity preparation, the pulpal floor should be flat over most of its extent. Generally speaking pulpal depth should be 1-1.5 mm from the DEJ.
- 4. In the proximal portion of the inlay cavity preparation, the axial wall should be either flat or slightly rounded in the bucco-lingual direction, and either vertical or slightly divergent (5-10°) towards the pulpal floor in the gingivo-occlusal direction. Furthermore, the depth, axially, should ideally be 1-1.5 mm from the DEJ.
- 5. Sometimes it is necessary to impose a third plane in the form of a secondary flare, placed on enamel peripherally. This serves to simplify impressions and wax pattern manipulations and for the other reasons previously mentioned.
- 6. The gingival floor, proximally should be flat in the bucco-lingual direction, making a slightly obtuse angle with the buccal and lingual walls.
- 7. The junction between the occlusal bevel and the secondary or primary flare proximally, and also, the junction between the primary or secondary flares proximally and the gingival bevel should be very rounded and smooth.
- 8. Some of the retention means previously mentioned can be used in this design, in addition to or in lieu of other means, to be described (e.g., facial, lingual and gingival grooves proximally, internal boxes or slots occlusally, capping corners of cusps, etc.).

8. Case Report

A patient of 34yrs age, reported to the Dept. of Conservative Dentistry and Endodontics with the chief complaint of food lodgement in lower right back tooth region. On examination patient had old class I silver fillings on 46 & 47, with frank class II caries in between 46 & 47. Radiograph showed no pulpal involvement. Treatment procedure of cast inlay restoration explained to the patient. Advantages, disadvantages of amalgam, composite restoration and crowns discussed with the patient. Patient wanted Class II Inlay, accordingly Class II Inlay planned & written informed consent taken.

Initial old Class I silver filling removed and extended 1mm into dentin at the central fossa. Burs 169 L used for giving 3-5° divergence and bur no. 7404 for giving bevels. Materials and equipments for forming and spruing the indirect wax pattern include gas burner, articulated casts and die, soft inlay wax, Type II inlay wax, [2] die lubricant and applicator brush, Ward's C carver, No. 7 wax carver, sprue former, sticky wax. Indirect class II cavity prepared, Inlay wax pattern fabricated on the cast with sprue former for 46 & 47.

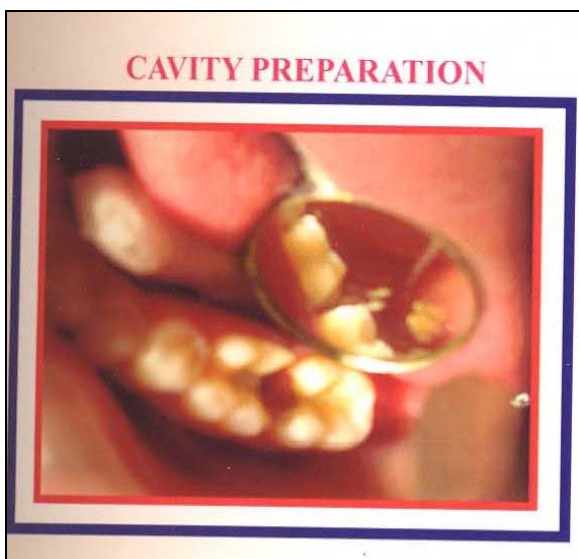


Fig 1: Inlay Cavity Preparation

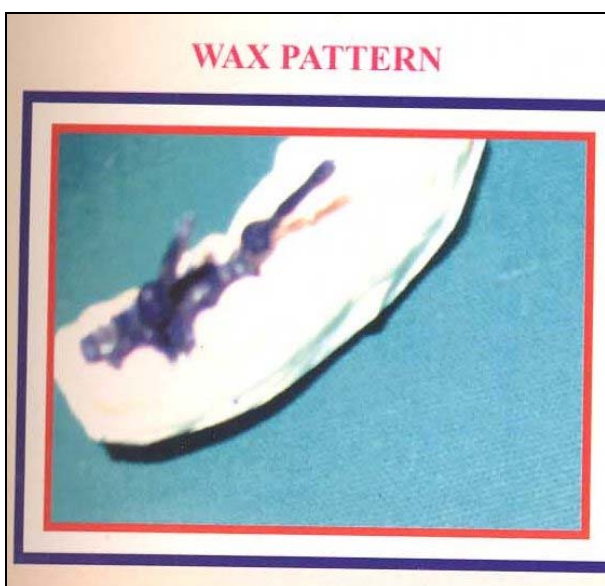


Fig 2: Class II Direct Wax Pattern with sprue attached

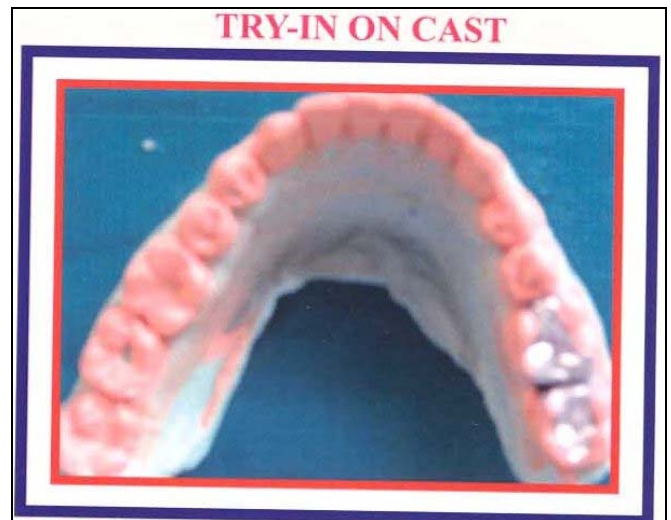


Fig 3: Try-in On Cast for accurate adaptation.

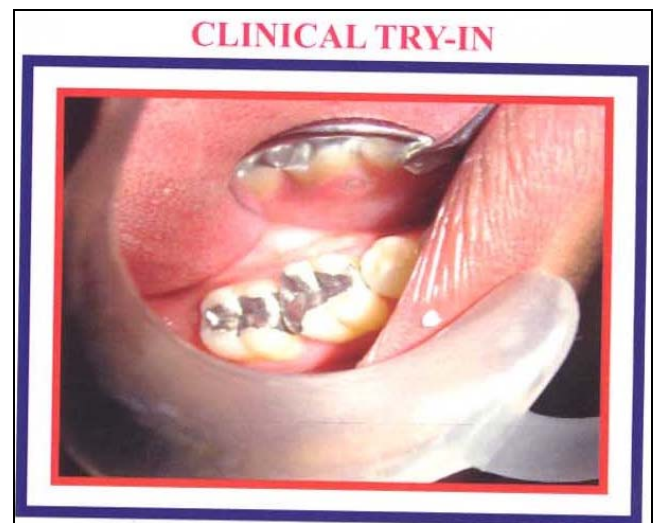


Fig 4: Clinical try-in done and cemented.

9. Case Discussion

9.1 Treatment options for class ii in between two Posterior Teeth

- Silver amalgam restoration
- Composite restoration
- Crowns

The silver amalgam is the oldest restorative material with good compressive strength but has the disadvantage of restoration fracture if it is a large cavity [3]. The composite is a tooth colored restorative material but has the disadvantage of less strength, polymerization shrinkage and hypersensitivity [4]. Stainless steel or porcelain fused to metal or full ceramic are indicated for large cavity but has the disadvantage of not being conservative [5], thus the best treatment for Class II caries occurring in between two teeth (adjacent caries) is Class II Inlay cast restoration. The inlay is considered the best conservative restoration as it has the advantage of good compressive strength to withstand heavy masticatory forces and thus in this case report the same is followed to restore 46 & 47.

10. Conclusion: Cast restoration form an integral link in the dental restorative chain. They are an excellent choice in many demanding situations. Understanding the principles of tooth preparations and the intricacies of cast restorations will enable the dentist to optimally utilize this excellent option, when the clinical situation demands.

11. References

1. Taggart WH. A new and accurate method of making gold inlays. *Dent. Cosmos*, 1907; 49:1117.
2. Phillips RW, Biggs DH. Distortion of wax pattern as influenced by storage time, storage temperature and temperature of wax manipulation. *J Am Dent Assoc*. 1950; 41:28.S
3. Latzel H, Van't Hof MA, Vrijhoef MMA *et al*. A controlled clinical study of amalgam restorations: Survival, failures, and causes of failure. *Dent Mater* 1989; 5:115.
4. Roulet JF. The problems associated with substituting composite resins for amalgam: A status report on posterior composites. *J Dent* 1988; 16:101.
5. Council on dental materials, instruments and equipment: report on base metal alloys for crown and bridge applications: benefits and risks. *J Am Dent Assoc* 1985; 111:479.
6. Art and science of operative dentistry – Sturdevant.
7. Principles and practice of Operative Dentistry – Charbeneau.
8. Fundamentals of Operative Dentistry – Marzouk.
9. Textbook of Operative Dentistry – Summit.
10. Atlas of inlays, onlays, crown and bridges – Shillenberg
11. Inlays, Crowns & Bridges – Cowell and Curson