



ISSN Print: 2394-7489
ISSN Online: 2394-7497
IJADS 2016; 2(4): 68-71
© 2016 IJADS
www.oraljournal.com
Received: 13-08-2016
Accepted: 14-09-2016

Dr. Disha Bansal
Assistant Professor, Department
of Dentistry, Shri Guru Ram Rai
Institute of Medical and Health
Sciences, Dehradun,
Uttarakhand, India

Dr. Mrinalini Mahajan
Professor & HOD, Department
of Dentistry, Shri Guru Ram Rai
Institute of Medical and Health
Sciences, Dehradun,
Uttarakhand, India

Morphological variations in the root canal system of mandibular premolars in the population of Uttarakhand

Dr. Disha Bansal and Dr. Mrinalini Mahajan

Abstract

Aim: The aim of this study was to investigate the variations in root canal morphology of the Mandibular premolars in the population of Uttarakhand using periapical radiographs.

Objective: For the success of the endodontic treatment, shaping and sealing of the root canals in the three dimension is mandatory, for which the thorough understanding of the root canal system and its variation is important.

Methods: A total of 110 mandibular premolars were examined using the periapical radiographs, number of roots and root canals were evaluated.

Results: Among the teeth examined 14.5% (n=16) had more than one root and 21.4% (n=24) had two and more canals, the occurrence of three roots and three canals was rare.

Conclusion: Majority of the mandibular premolars have one root with one canal, but a large fraction of the population presents with the two canals.

Clinical significance: Due to the high incidence of the multiple canals in these teeth, extra attention has to be paid for the successful outcome of the endodontic treatment.

Keywords: Root canal variations, mandibular premolars, radiographs

1. Introduction

Mandibular premolars, often called as “endodontist’s enigma”, are the most difficult teeth to undergo endodontic management ^[1].

The success of the endodontic management solely depends on the knowledge and appreciation of the possible variations in the root canal system and thorough cleaning of these canals, lacking this important knowledge may lead to the endodontic treatment failure ^[2].

The major portion of the population presents with the single root and single canal in the mandibular premolars, but the literature holds the information of multiple canal existence in these teeth. The occurrence of the variations in the root canal system of mandibular premolars is relatively very high when compared to other teeth, due to which they are considered difficult to be treated endodontically ^[3-12]

The least existence of the literature on the morphology of mandibular premolars among the Indian population has convinced us to present this study for the evaluation of the root and root canal morphology in mandibular premolars in the population of Uttarakhand.

2. Materials and Methods

The patients who reported for undergoing endodontic treatment of mandibular premolars were randomly selected, a total of 110 patients (110 mandibular premolars) were evaluated

Image Capture:

A minimum of two radiographs were taken for each tooth, two independent Endodontists assessed these radiographs for the number of roots and canals, the position of canal bifurcation and the canal configuration., Vertucci’s classification was followed for the categorization of the root canals.

3. Results

Out of the 110 cases 56 were females and 54 were males with an age range of 20 to 50 years.

Correspondence

Dr. Disha Bansal
Assistant Professor, Department
of Dentistry, Shri Guru Ram Rai
Institute of Medical and Health
Sciences, Dehradun,
Uttarakhand, India

3.1 Number of roots

Single root was found in 85.5% (94 teeth), two roots in 13.9% (15 teeth) and three roots in 0.6% (1 tooth).

3.2 Number of root canals

Out of all the teeth studied, around 78.6% (86 premolars) of them had single canal, 20.8% (23 premolars) had two canals and 0.6% (1 premolar) had three canals.

4. Discussion

The documentation regarding the normal anatomy of the roots and the root canals well exists in the textbooks but there occurs a very high degree of variation in the anomaly reporting of these canals^[1].

The reports of the variations of mandibular premolars in the anatomic studies and the clinical cases are well mentioned in the literature and states that these are the most difficult teeth to be treated endodontically due to the wider variations in the root canal system^[13] The depending factors counted upon were the age, gender, ethnicity and the history of trauma^[6-7]

The studies done over the years presented the very high degree of occurrence of more than one canal in mandibular premolars. Some studies quoted the incidence of three roots and canals to be 0.4%^[5, 7, 8, 14] depicting the presence of a wide canal lingually and two small canals buccally^[10, 11]

Failure to predict and recognize the existence of the extra root canals might lead to the failure of the endodontic management which may result in acute flare ups during and after the endodontic procedure and retreatment^[15].

The disadvantages of the radiographic technique are well known as it allows the clinician to only view the two dimensional picture and the important findings like the existence of the extra roots and extra canals can be missed, but this is the most commonly available diagnostic aid at the clinical set up and this is the reason that only the radiographs were taken in this study for the purpose of reading the root canal system of these teeth.

In our study two rooted premolars were found in around 13.9% of the cases and 20.8% premolars showed two canals whereas more than two roots and two canals was found in 0.6% of the cases.

The results of this study were in contrast with the previous study done on Indian population by Rakesh *et al* (2013)^[16] which showed single roots in 93.5% and single canal in 93.2% of teeth and more than two roots and two canals in 6.4% and 6.8% of the teeth respectively, this might be due to genetic differences related to the racial background of the population.

Results of the previous studies by Zillich and Dowson (1973)^[13] done on the population of USA and showed single canal in 87.5% and two and more canals in 12.5% of teeth.

Hasheminia and Hashemi (2005)^[17] studied the population of Iran and showed single canal in 88.8% and two and more canals in 11.2% of teeth.

Geider *et al.* (1989)^[18] studied the population of France and showed single canal in 86.6% and two and more canals in 13.4% of the teeth.

The racial background of the population of the Uttarakhand can be explained to an extent as the Kiratas from the south east China settled as the part of the population of the Uttarakhand, and this group of population is regarded ancestral to the tribes who are called Bhotias today, so this explains somewhat the results of this study which were in accordance with the previous study by Tzu-Yi Lu *et al* (2006)^[19] in the Chinese population which showed 22% mandibular premolars with two canals.

The changes take place in the shape and the dimension of the already formed root canals due to aging and the secondary dentin deposition, this is the factor which can be controlled in the clinical study only and not in the *in vitro* studies, this was the reason for the age group selection which ranged between 20 to 50 years^[20]

The careful clinical and radiographic detection of the variation in the number and the morphology of the root canals is must for the endodontic success^[21-23]

The outlines of the tooth both exterior and interior should be traced and read carefully with sufficient magnification on the pre-operative radiograph for the detection of the anomalies in the root canal system^[3].

Scott and Turner describe the accessory root of mandibular first premolar as "TOME'S ROOT"^[24]

The precision in the identification of the root canal system is the primary most step in the success of the root canal treatment^[25].

The broad and flat roots mostly contains multiple canals and intercanal ramifications, the horizontally angulated pre-operative radiographic evaluation is must for detection of presence of extra root canal^[26].

The incidence of the presence of three canals in the mandibular premolars is relatively low in the literature till date but each case should be examined and analysed carefully clinically as well as radiographically for the additional canals for the successful endodontic management^[11].

The suspicion of the presence of a missed canal has to be considered if the patient reports with the pain and sensitivity in the endodontically treated mandibular premolar^[27].

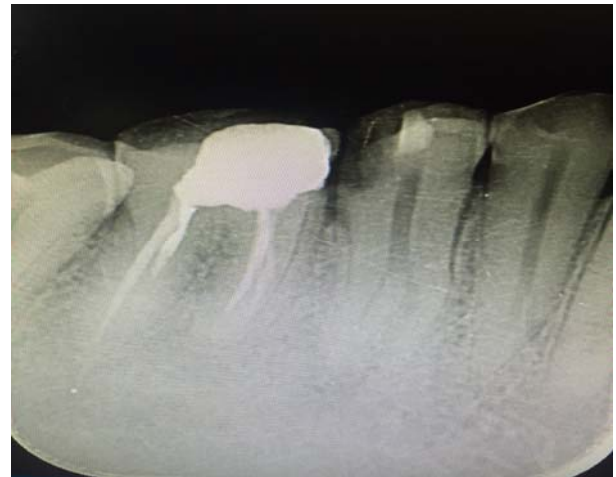

Fig 1: Pre-operative radiographic picture showing mid root bifurcation of the root with two separate canals

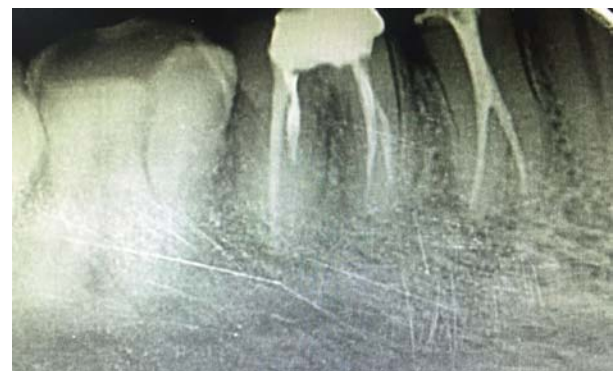

Fig 2: Post obturation radiographic picture

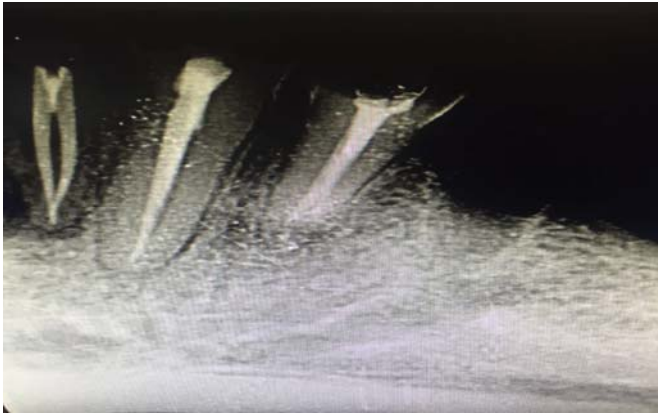

Fig 3: Post obturation radiographic picture

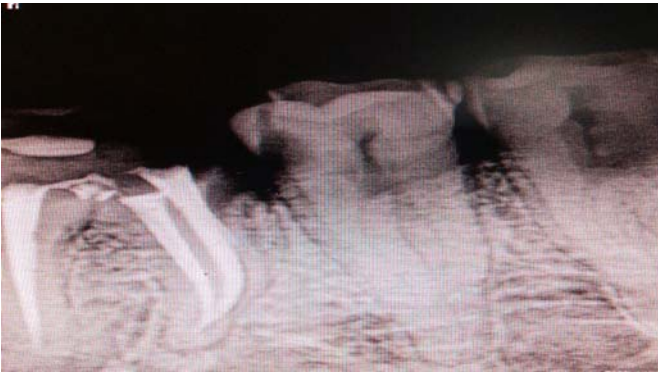

Fig 4: Pre-operative radiographic picture showing three root canals

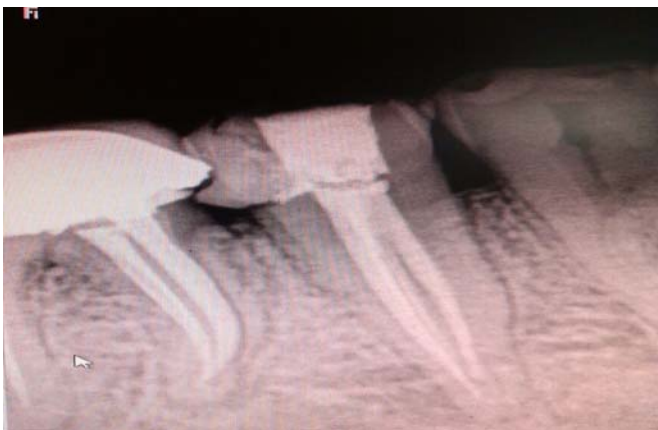

Fig 5: Post obturation radiographic picture

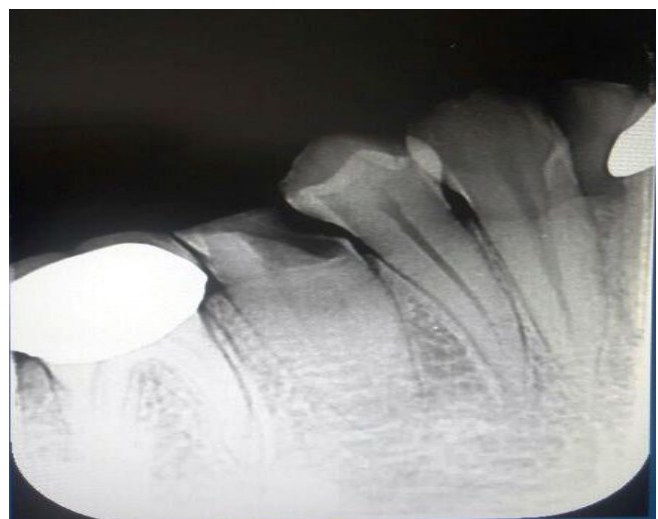


Fig 6: Pre-operative radiographic picture showing two root canals

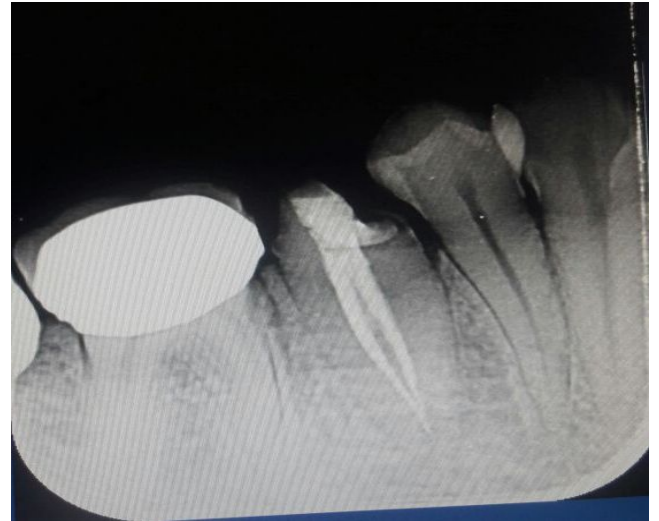

Fig 7: Post obturation radiographic picture

5. Conclusion

Majority of the mandibular premolars presents with one root with one canal, but a large fraction of the population of Uttarakhand presents with the two canals.

5.1 Clinical Significance: Due to the high incidence of the multiple canals in these teeth, extra attention has to be paid for the successful outcome of the endodontic treatment, so clearly the findings of this study are important in assisting all dental practitioners in providing successful endodontic treatment.

6. References

1. Ingle J, Bakland L. Endodontics, 5th edition, Hamilton: BC Decker, 2002.
2. Rahimi S, Shahi S, Lotfi M, Zand V, Abdolrahimi M, Es'haghi R. Root canal configuration and the prevalence of C-shaped canals in mandibular second molars in an Iranian population. *J Oral Sci.* 2008; 50(1):9-13.
3. Rodig T, Hulsmann M. Diagnosis and root canal treatment of a mandibular second premolar with three root canals. *Int Endod J.* 2003; 36:912-919.
4. Cleghorn BM, Christie WH, Dong CCS. Anomalous mandibular premolars: a mandibular first premolar with three roots and a mandibular second premolar with a C-shaped canal system. *Int Endod J* 2008; 41:1005-1014.
5. Gandhi B, Patil AC. Root canal treatment of a mandibular second premolar with three roots and canals-an anatomic variation. *J Dent.* 2013; 10(6):569-574.
6. Cleghorn BM, Christie WH, Dong CCS. The root and root canal morphology of the human mandibular second premolar: a literature review. *J Endod.* 2007; 33:1031-1037.
7. Kottoor J, Albuquerque D, Velmurugan N, Kuruvilla J. Root anatomy and root canal configuration of human permanent mandibular premolars: a systematic review. *Anat Res Int* 2013, 1-14.
8. Mokhtari H, Niknami MZV. Managing a mandibular second premolar with three-canal and taurodontism: a case report. *Iranian Endod J.* 2013; 8(1):25-28.
9. Singh S, Pawar M. Root canal morphology of South Asian Indian mandibular premolar teeth. *J Endod.* 2014; 40(9):1338-1341.
10. Lotfi M, Vosoughhosseini S, Zand V, Fatemi A, Shyezadeh V, Ranjkesh B. A mandibular second premolar with three canals and atypical orifices. *J Oral Sci.* 2008; 50(3):363-6.

11. Soares LR, Arruda M, De Arruda MP, Rangel AL, Takano E, De Carvalho Jr JR *et al.* Diagnosis and root canal treatment in a mandibular premolar with three canals. *Braz Dent J.* 2009; 20(5):424-427.
12. Chauhan R, Singh S. Management of a 3-canal mandibular premolar in a patient with unusual root canal anatomy in all mandibular premolars. *Gen Dent* 2013; 61(6):16-18.
13. Zillich R, Dowson J. Root canal morphology of mandibular first and second premolars *Oral Surg Oral Med Oral Pathol.* 1973; 36(5):738-44.
14. Hariharavel VP, Kumar AA, Ganesh C, Annamalai S, Ramar K, Aravindhan R. Root canal treatment of mandibular second premolar with three separate roots and canals using spiral computed tomographic. *Case Reports Dent* 2014, 1-4.
15. Weine F. *Endodontic Therapy.* 6th Edition. Boston, MA, USA: Mosby; 2004, 366.
16. Rakesh. Root Canal Morphology of Mandibular second Premolars in North Indian Sub Population. *International Journal of Scientific and Research Publications.* 2013; 3(8):1-4.
17. Hasheminia M, Hashemi A. Frequency of canal configuration in maxillary first premolars and mandibular second premolars. *J Isfahan Dent School.* 2005; 1:59-64.
18. Geider P, Perrin C, Fontaine M. Endodontic anatomy of lower premolars: apropos of 669 cases. *J Odontol Conserv.* 1989, 11-5.
19. Tzu-Yi Lu, Shue-Fen Yang, Sheng-Fang Pai. Complicated Root Canal Morphology of Mandibular First Premolar in a Chinese Population Using the Cross Section Method *JOE—2006; 32(10):931-936*
20. Rózyło TK, Miazek M, Rózyło-Kalinowska I, Burdan F. Morphology of root canals in adult premolar teeth. *Folia Morphol (Warsz)* 2008; 67:280-5.
21. Trope M, Elfenbein L, Tronstad L. Mandibular premolars with more than one root canal in different race groups. *J Endod.* 1986; 12:343-5.
22. Frank j, Vertucci. Root canal morphology and its relationship to endodontic procedures; *Endodontic Topics.* 2005; 10:3-29
23. Kala M, Chandki R, Lodha E, Shaktidar P. C shaped canal configuration: a diagnostic dilemma; *AOSR* 2011; 1(2):79-83.
24. Scott R, Turner C. *The anthropology of modern human teeth.* Cambridge: Cambridge university press, 2000.
25. Nallapati S. Three canal mandibular first and second premolars: a treatment approach. *J Endod.* 2005; 31:474-476.
26. Gulabivala K, Aung TH, Alavi A, Ng YL. Root and canal morphology of Burmese mandibular molars. *Int Endod J* 2001; 34:359-72.
27. Chen J, Li X, Su Y, Zhang D, Wen X, Nie X *et al.* A micro-computed tomography study of the relationship between radicular grooves and root canal morphology in mandibular first premolars. *Clin Oral Investig.* 2015; 19(2):329-334.