



International Journal of Applied Dental Sciences

ISSN Print: 2394-7489
ISSN Online: 2394-7497
IJADS 2016; 2(4): 65-67
© 2016 IJADS
www.oraljournal.com
Received: 12-08-2016
Accepted: 13-09-2016

Dr. Panna Mangat

Professor, Divya Jyoti College of
Dental Sciences and Research,
Modinagar, Ghaziabad,
Uttar Pradesh, India

Dr. Anil K Tomer

Professor HOD, Divya Jyoti
College of Dental Sciences and
Research, Modinagar,
Ghaziabad, Uttar Pradesh,
India

Dr. Gaurav Bhardwaj

PG Students, Divya Jyoti
College of Dental Sciences and
Research, Modinagar,
Ghaziabad, Uttar Pradesh,
India

Dr. Amteshwar Singh

PG Students, Divya Jyoti
College of Dental Sciences and
Research, Modinagar,
Ghaziabad, Uttar Pradesh,
India

Dr. Sagarika Muni

PG Students, Divya Jyoti
College of Dental Sciences and
Research, Modinagar,
Ghaziabad, Uttar Pradesh,
India

Dr. Sneha

PG Students, Divya Jyoti
College of Dental Sciences and
Research, Modinagar,
Ghaziabad, Uttar Pradesh,
India

Correspondence

Dr. Panna Mangat

Professor, Divya Jyoti College of
Dental Sciences and Research,
Modinagar, Ghaziabad,
Uttar Pradesh, India

Pre-endodontic rehabilitation of badly mutilated teeth with canal projection technique

**Dr. Panna Mangat, Dr. Anil K Tomer, Dr. Gaurav Bhardwaj,
Dr. Amteshwar Singh, Dr. Sagarika Muni and Dr. Sneha**

Abstract

Broken down molars or perforations are common findings and their comprehensive rehabilitation prior to endodontic therapy is an issue that needs to be addressed. Currently, rubber dam is the Standard of Care for isolation during endodontic treatment.

Grossly destructed teeth always pose a problem to the operator during the rubber dam isolation. This case report describes the innovative concept of using 'Projector Endodontic Instrument Guidance System' (PEIGS) known as projector using hollow plastics as sleeves.

Alternatives, such as Hypodermic needles as sleeves were tried with similar outcome.

Keywords: Canal projection technique, hollow metallic needle, pre endodontic restoration

1. Introduction

Access in Endodontics is synonymous to creating the means by which we locate and identify root canals and remove diseased pulp. However, the definition of success goes further...! Adequate access not only indicates a straight-line visual access to all the canals but also includes the maintenance of a consistent pathway throughout the endodontic treatment procedure, until the completion of obturation of the root canal system. By ensuring proper access to the root canal system, the prospect for success improves immeasurably.

Isolating a severely mutilated teeth and coronal perforations with open pulp chambers often pose a hindrance to the endodontist during clamp placement. A bonded coronal restoration not only will simplify the endodontic procedure but also strengthens the tooth^[1].

Therefore, placing a restoration without hampering canal patency prior to commencing endodontic treatment is important during their management. This can be effectively achieved by an innovative technique as suggested by Gerald N Glickmann and Robert Pileggi also known as "Projector Endodontic Instrument Guidance System" wherein hollow plastic sleeves were used to maintain the patency of canal along with bringing them to the cavosurface margin^[2, 3].

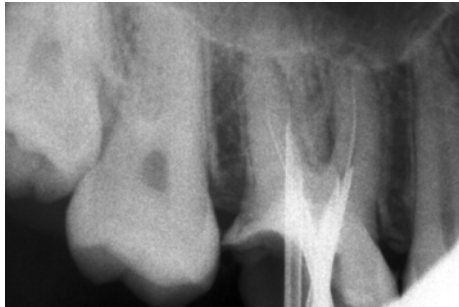Our articles focuses on the Canal projection technique for management of a few cases, all of which have been successfully rehabilitated using the hypodermic needles as projector sleeves.

These case reports demonstrate the use of these metallic hollow sleeves that are easily available and more economic yet an effective alternative.

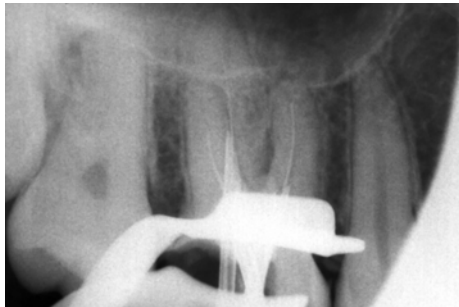
Case report 1

A 32 year old male patient reported to our department with a complaint of pain in upper right posterior region since 1 month. Clinical examination revealed a grossly carious tooth with pulpal exposure and tenderness to percussion. Radiographically pulpal involvement was observed and initial apical changes. A diagnosis of apical periodontitis was made and endodontic therapy was initiated. Patency of canals was confirmed with size 10 K file and coronal 3mm of orifices were enlarged with orifice shapers. A hypodermic needle with an outer diameter of 1mm and inner diameter of .75mm cut at the hub and the bevel was used as sleeve for canal projection. Three sleeves for three canals each with a k file inserted in them. The crown surface for bonding was acid etched for 15 seconds and rinsed. The sleeves coated with separating media along with the respective k files were inserted in the canal to the maximum depth possible.

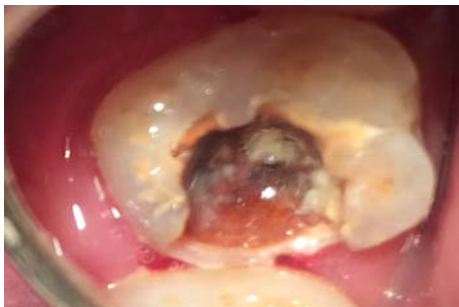
Bonding agent (prime and bond) was applied to the etched surface and light cured for 20 seconds. A layer of SDR composite was placed and light cured for 40 seconds. The restoration is up to the level of cavosurface margin offering visualization and convenience for instrumentation as straight line access is achieved and also provides a strong core and coronal seal and effective rubber dam placement. The projectors are now removed and working length is determined following which the root canal procedure is completed. Integrity of composite build up is maintained throughout the treatment. The gutta percha is sealed off at the orifices and the remaining projected space restored with composite



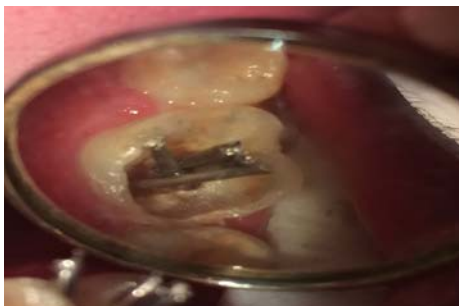With the hypodermic needles



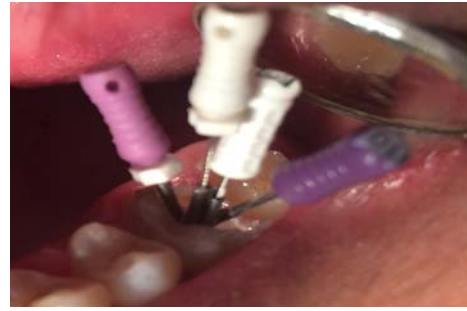After the Core build up



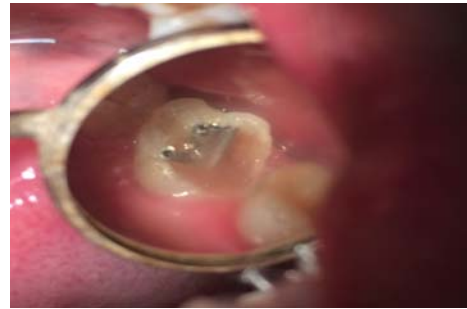Preoperative view



With Hypodermic needles



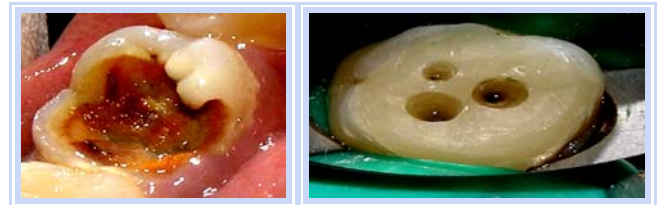
Files In canal orifices



Core build up

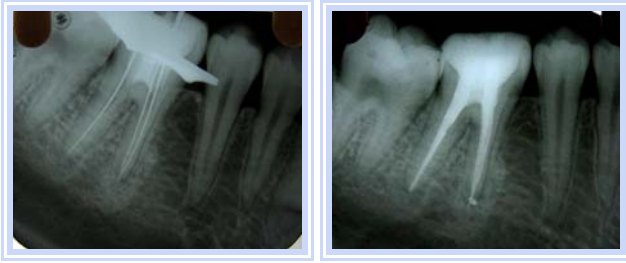Case 2

A 38 years old patient reported to our department with the complaint of constant pain in lower left first molar since 15 days. She gave history of attempted root canal treatment somewhere else. Clinical examination revealed grossly carious tooth with huge temporary restoration which on removal exposed bleeding site in lingual region and tenderness to percussion. Radiographically widening of pdl was observed. A diagnosis of incomplete root canal treatment, perforation at the palatal site was observed. The root canal treatment was initiated. Occlusal surfaces were made flat to provide endodontic references points. The perforation was sealed necessary modifications of access preparation were done to locate all the canal orifices. The patency of all the canals was confirmed with the k files. The pre endodontic restoration was done that resulted in a stable coronal tooth structure, at the same time sealing the perforation site giving it convenience form for the instrumentation by providing straight line access to each canal and easier rubber dam isolation. Once core build up is done working length was determined and further treatment was carried out.



Case 3

Another 30 years old patient came with badly mutilated tooth with chief complaint of pain. Examination revealed loss of tooth structure which was treated with the same methodology as described in earlier cases.



2. Discussion

Preservation of grossly mutilated tooth by endodontic treatment, if possible is universally preferred mode of treatment to tooth extraction and replacement^[4].

Coronal leakage is one of the major contributors to endodontic failure. A bonded core restoration prior to endodontic treatment with open root canal orifices at times, may result in blockage of the orifices as some amount may get unintentionally pushed into the root canals, resulting in suboptimal final outcome.

Isolation of the tooth can pose a bit challenge to the operator when minimal tooth structure remains and endodontic therapy is indicated for successful rehabilitation. Reinforcement of the coronal tooth structure following endodontic treatment has been addressed quite often but very less focus is drawn on the bonded core build up prior to endodontic phase.

Canal projection technique as describes by Gerald N Glickmann and Robert Pileggi also known as “Projector Endodontic Instrument Guidance System” uses plastic sleeves for Pre endodontic rehabilitation of a badly mutilated teeth. Due to limited availability of these sleeves in market and cost effectiveness alternatives such as Hypodermic needles were tried with effective outcomes.

This indigenous technique not only reduces the complexity during the endodontic treatment by elevating the orifice margins to the cavosurface for easy visualization, providing straight line access with proper orientation, better sealing of the pulp chamber and effective rubber dam clamp placement. Further the chamber acts as a reservoir for the irrigant during instrumentation^[3].

In addition to simplifying the endodontic phase the procedure strengthens the tooth structure, decreasing the possibility of further damage to the tooth during and post treatment. The canal projector allows isolation of the individual canals by surrounding them with bonded core. There by reducing the coronal leakage potential during and following the endodontic treatment.

It also aids in sealing the furcal perforations as well as its care during the subsequent visits. Another advantage it offers is the immediate post endodontic restoration and should the restoring dentist wish to place post for the case, it simplifies the placement by providing proper orientation preventing misdirection to minimal^[1].

So to conclude, in our article we describe the indigenous technique of canal projection with hypodermic needles offering the similar benefits of conventional PEIGS, in addition to being easily available, cost effective, no learning curve and yet equally effective.

3. Conclusion

The article describes the application of an innovative technique “PEIGS” using hypodermic needles as sleeves to maintain canal patency and for successful rehabilitation of grossly mutilated teeth.

4. References

1. Gregori M. kurtzman Improving endodontic success through coronal leakage prevention. Inside dentistry Nov /Dec 2005; 1(2).
2. Tanikonda R. Canal projection using gutta percha points: A novel technique for pre-endodontic build up of grossly destructed tooth. J Conserv Dent. 2016; 19(2):194-197
3. Velumurugan N. Restoration of a vertical tooth fracture and a badly mutilated tooth using canal projection. Indian Journal of dental research. 2007; 18(2):87-89.
4. Roda RS. Non surgical retreatment In: Cohen S, HargreavesK, editors. Pathways of pulp 9th edition. St Louis, MO, USA: Mosby, 2006, 944-1010.