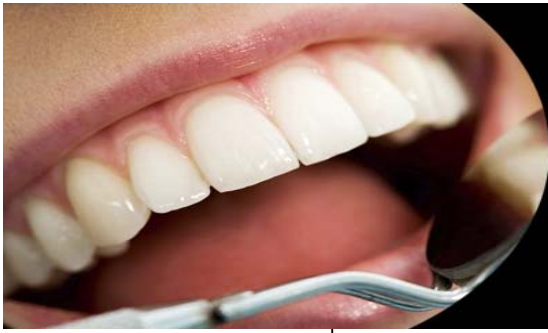



ISSN Print: 2394-7489  
ISSN Online: 2394-7497  
IJADS 2017; 3(1): 68-70  
© 2017 IJADS  
www.oraljournal.com  
Received: 12-11-2016  
Accepted: 13-12-2016

**Mahendra Patait**

Professor and Head of  
Department, Department of Oral  
Medicine Diagnosis and  
Radiology, S.M.B.T. Dental  
College and Post graduate  
Research Center, Amrutnagar,  
Sangamner, Maharashtra, India

**Deepali Nipunge**

Post Graduate Student,  
Department of Oral Medicine  
Diagnosis and Radiology,  
S.M.B.T. Dental College and  
Post graduate Research center,  
Amrutnagar, Sangamner,  
Maharashtra, India.

**Amol Thorat**

Prof and Head Dept. of  
Prosthodontia, Aditya Dental  
College, Beed, Maharashtra,  
India.

**Sameer Narkhede**

Prof., Dept. of Orthodontia, DY  
Patil dental College, Mumbai.  
Dept. of Orthodontia, Al-Ameen  
Medical, Campus, Vijayapura,  
Karnataka, India

**Shrinivas Amberkar**

Prof., Dept. of Orthodontia, DY  
Patil dental College, Mumbai,  
Maharashtra, India.

**Correspondence**

**Mahendra Patait**

Professor and Head of  
Department, Department of Oral  
Medicine Diagnosis and  
Radiology, S.M.B.T. Dental  
College and Post graduate  
Research Centre, Amrutnagar,  
Sangamner, Maharashtra, India.

## Diagnosis of osteoma of mandible with 3D cone beam CT

**Mahendra Patait, Deepali Nipunge, Amol Thorat, Sameer Narkhede and Shrinivas Amberkar**

### Abstract

Osteoma is a benign tumour of mature compact or cancellous bone that increases in size by continuous formation of bone. The majority of cases has been documented as osteoma occur in the craniofacial bones most commonly in paranasal sinuses and jaw bones, rarely seen in other bones and in soft tissues such as muscle. Two variants of osteoma are documented which be different in the origin in relation to cortical plates: Peripheral (periosteal) osteomas are masses attached to cortical plates and central osteomas arise from endosteal bone surface.

The lesion is found more frequently in the mandible than maxilla and most common sites are lingual aspect of body of mandible and lower border in the region of angle.<sup>2</sup>Other locations include paranasal sinuses, orbits, temporal bone, external auditory canal and pterygoid process.

Peripheral osteoma appears clinically as unilateral, well circumscribed, sessile or pedunculated, mushroom like mass measured about 10 to 40 mm in diameter. There is no predilection for age, sex.

In present case, we discuss about the characteristic features and diagnosis of osteoma and differentiate from another bony lesions and treatment modalities of this.

**Keywords:** Benign tumour, osteoma, Gardner's syndrome

### 1. Introduction

Osteoma is a benign tumour composed of mature compact or cancellous bone that increases in size by continuous formation of bone<sup>[1]</sup>.

The majority of cases occur in the craniofacial bones most frequently in paranasal sinuses and jaw bones, although rare cases in other bones and in soft tissues such as muscle have been documented<sup>[1]</sup>.

Two variants of osteoma are recognized which differ in the origin in relation to cortical plates: Peripheral (periosteal) osteomas develop as masses attached to cortical plates and central osteomas arise from endosteal bone surface<sup>[1, 2]</sup>.

The lesion is found more often in the mandible rather than in the maxilla with the lingual aspect of the body of mandible and lower border in the region of angle being the most common sites<sup>[2]</sup>.

Other locations include paranasal sinuses, external auditory canal, orbits, temporal bone and pterygoid process<sup>[3, 4]</sup>.

Clinically, peripheral osteoma appears as a unilateral, sessile or pedunculated, well circumscribed, mushroom like mass larger from 10 to 40 mm in diameter. There is no predilection for age, sex<sup>[3-7]</sup>.

The compact osteoma comprises of dense, compact bone with a few marrow spaces and with only a few osteons.

The cancellous osteoma is characterized by bony trabeculae and a fibro fatty marrow enclosing osteoblast and with an architecture resembling mature bone<sup>[4, 5, 15]</sup>.

Patients with osteomas should be evaluated for Gardner's syndrome (GS)<sup>[2]</sup>. This syndrome is an autosomal dominant disease characterized by gastrointestinal polyps, multiple osteomas, skin and soft tissue tumors, and multiple impacted or supernumerary teeth. It is also called as familial multiple polyposis.

While a solitary osteomas of the jaw is a common incidental findings in OPG, if more than three such lesions are found this is highly suggestive of Gardner syndrome.

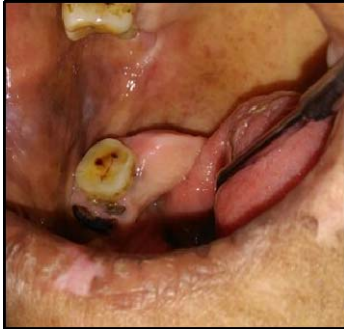In addition, dental abnormalities such as supernumerary, absent or unerupted teeth and odontoma are often determined in routine OPG.

**2. Case report**

A 65 year-old female patient reported to dental outpatient department (OPD) with a complaint of a painless swelling in the right lower back region of jaw for the past 10 years and was having discomfort to the tongue.



**Fig 1:** Facial profile



**Fig 2:** A bony hard swelling

Patient was apparently normal before 10 years and then she developed a swelling on the same jaw region, which is of gradual onset which slowly increases in size to attain the present size.

Patient has undergone extraction of tooth under local anaesthesia without any complications 2 years ago. On extraoral examination, patient’s face was grossly symmetrical and TMJ movements were normal.

Diffuse whitish scars seen on upper and lower lip involving vermillion border. Patient ascribed the lesion to fever.

On intraoral examination, generalized attrition was seen and periodontal status was poor.

On intraoral examination, on inspection, a single well-defined swelling seen with relation to 48 of size approximately 2 × 2.5 cm, roughly spherical in shape, which extends from the lingual side involving attached gingiva distal to 48 and extends more posteriorly.

The surface over the swelling appears smooth and mucosa appears normal. On palpation, inspeitory findings are confirmed with respect to number, size, shape, and extent. The swelling is bony hard in consistency and nontender roughly triangular grey-white areas seen at corner of mouth on both the sides. Right commissural mucosa revealed firm, non tender, non scrapable, red and white patch measuring 2 x 1.5 cm. Surface appears rough and slightly elevated which clinically resembled “mud crack” in appearance. The lesion was not scrapable.

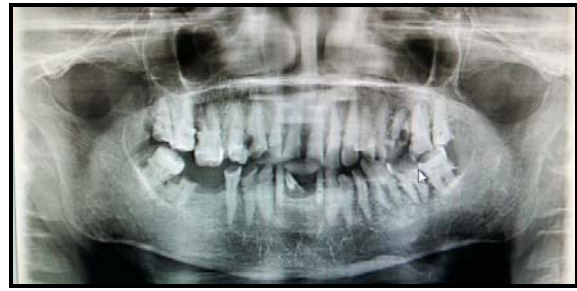Based on history and clinical examination, provisional diagnosis osteoma was made.

**3. Differential diagnosis:** Exostoses, Mandibular tori, osteoid osteoma, ossifying fibroma.

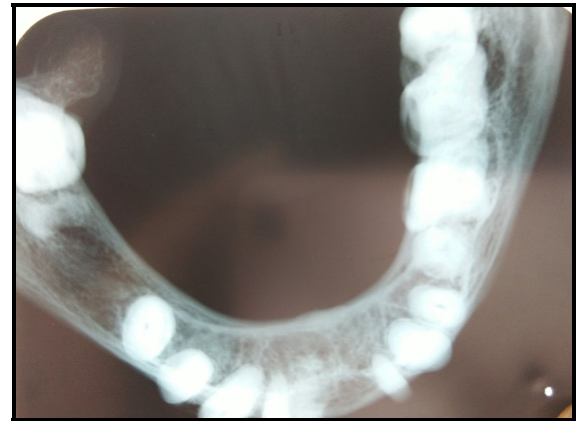An intraoral radiograph and panoramic radiograph revealed no abnormalities. [Figure 3, 4]



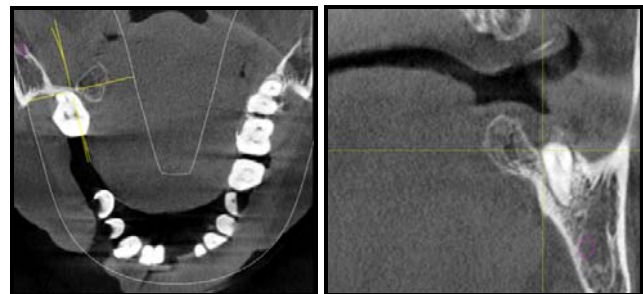
**Fig 3:** IOPA



**Fig 4:** OPG



**Fig 5:** Occlusal radiograph



**Fig 6:** CBCT

A mandibular occlusal radiograph revealed well defined radiopaque lesion of 1.5 X 1.5 cm in size adherent to lingual aspect of cortical plate of right mandibular posterior region shows trabeculation. [Figure 5]

CBCT revealed well defined radiopacity measuring about 9.8mm to 6.3mm, on lingual aspect of mandibular posterior region with trabeculation. [Figure 6], according to radiographic findings diagnosis was made as peripheral Osteoma of right mandibular posterior region.

The patient underwent surgical intervention under local anaesthesia, where osseous contouring was done.

**4. Discussion**

Osteomas are benign, slow-growing, well- defined osteogenic lesions developing from mature bone. They are characterized by the proliferation of compact or cancellous bone [5].

The etiology of osteomas remains unknown. Some authors consider such lesions as true neoplasms, while others classify them as developmental anomalies [6-8].

The continuation of growth after adulthood is the most characteristic feature that distinguishes these lesions from other bony exostoses, and this pattern signifies the neoplastic nature of the lesion [9, 10].

Traumas and infections are considered to trigger excessive bone activity [7, 10].

However, present case did not have any history of trauma but infection was there because of poor oral hygiene.

Osteomas can occur at any age. However, they are most commonly diagnosed in the third and sixth decades of life and the present case was also in the sixth decade of her life.

These lesions occur in the paranasal sinuses and most commonly involve the frontal and ethmoid sinuses [5]. External auditory tract, orbita, temporal bone, and pterygoid processes are other sites of involvement [12]. The peripheral osteomas rarely occur in the mandible [13].

The mandibular peripheral osteomas are often located in the mandibular condyle and angulus, and also involve the ramus or molar area [13].

In the present case, the lesion was located in the posteriorly and lingual aspect of the mandible, which is a rare site of involvement.

Clinically, these lesions are characterized by slow and continuous growth patterns, unilateral involvement, well-defined margins, and mushroom-shaped masses with or without a stalk, and with a diameter between 1.5 and 4 cm. [14]. Clinical characteristics of our case were consistent with these findings.

Osteomas are usually asymptomatic, and they are detected during routine radiographic examinations, unless they enlarge enough to cause facial asymmetry or functional impairment [4, 15]. In the present case, the enlargement of the lesion caused disturbances in tongue movements.

On radiological examination, peripheral osteomas appear as an oval-shaped radioopaque mass with well-defined margins and growing on a broad base or a stalk on the cortex. These lesions usually do not cause destruction of the adjacent bone tissue [15]. In the present case, the lesion was limited to the cortex and did not cause destruction in the neighboring tissues.

Multiple osteomas were associated with Gardner's syndrome characterized by intestinal polyposis, cutaneous sebaceous cysts, and multiple supernumerary teeth [8]. The present case did not have any gastrointestinal complaints or dental anomaly. Clinical examination did not show any finding suggestive of Gardner's syndrome.

Surgical excision is the ideal treatment for osteomas. The lesions rarely show recurrence, and malignant transformation has not been reported.

## 5. References

1. Burket's Text book of Oral Medicine 10<sup>th</sup>ed and 11<sup>th</sup> ed.
2. Shafer's, Hine, Levy Text book of Oral Pathology, 6<sup>th</sup> Edition.
3. Wood & Goaz, Text book of DD of oral and maxillofacial lesions, 5<sup>th</sup>ed.
4. Woldenburg Y, Nash M, Bodner I. Peripheral osteom of the maxillofacial region. Diagnosis and management: A study of 14 cases. Med Oral Patol Oral Cir Bucal, 2005; 10(2):E139-142.
5. Kaplan I, Calderon S, Buchner A. Peripheral osteoma of the mandible: A study of 10 new cases and analysis of literature. J Oral maxillofac Surg 1994; 52:467-470.
6. Srinivasan P, Khaja Khalid Nawaz M, Mohan Shanker. Journal of Indian Academy of Dental Specialist Researchers. 2014; 1(1).
7. Johann AC, de Freitas JB, de Aguiar MC *et al*. Peripheral osteoma of mandible: case report and review of the literature. J Cranio Maxillofacial Surg. 2005; 33:276-281.
8. Bodner I, Gatot A, Sion-Vardy N, Fliss DM. Peripheral

osteoma of the mandibular ascending ramus. J Oral Maxillofac Surg. 1998; 56:1446-1449

9. Sayan NB, Ucok C, Karasu HA, Gunhan O. Peripheral osteoma of the oral and maxillofacial region: A study of 35 new cases. J Oral Maxillofac Surg. 2002; 60:1299-301.
10. Bhargava A. Department of Dental Surgery, Gandhi Medical College, Bhopal Revisiting Peripheral Osteoma of the Mandible with Case Series and Review of Literature, 2014.
11. Kaplan I, Calderon S, Buchner A. Peripheral osteoma of the mandible: a study of 10 new cases and analysis of the literature. J Oral Maxillofac Surg. 1994; 52(5):467-470.
12. Wanyura H, Kamiński A, Stopa Z. Treatment of osteomas located between the anterior cranial base and the face. J Craniomaxillofac Surg. 2005; 33(4):267-275.
13. Johann AC, de Freitas JB, de Aguiar MC, de Araújo NS, Mesquita RA. Peripheral osteoma of the mandible: case report and review of the literature. J Craniomaxillofac Surg. 2005; 33(4):276-281.
14. Neville BW, Damm DD, Allen CM, Bouquot JE. Oral & maxillofacial pathology. 2nd ed., Philadelphia: W. B. Saunders Co, 2002, 567.
15. Aghabeigi B, Evans AW, Crean SJ, Hopper C. Simultaneous repair of an orbital floor fracture and removal of an ethmoid osteoma: case report and review of the literature. Int J Oral Maxillofac Surg. 2003; 32(1):94-96.
16. Kerckhaert A, Wolvius E, van der Wal K, Oosterhuis JW. Giant osteoma of the mandible: case report. J Craniomaxillofac Surg. 2005; 33(4):282-285.