



ISSN Print: 2394-7489
ISSN Online: 2394-7497
IJADS 2017; 3(2): 23-25
© 2017 IJADS
www.oraljournal.com
Received: 07-02-2017
Accepted: 08-03-2017

Dr. Aditi Jain

Sr. Lecturer, MDS, Department of Conservative Dentistry and Endodontics, Maitri College of Dentistry and Research Center, Anjora, Durg, Chhattisgarh, India.

Dr. Abhinav Chand Singhal

Sr. Lecturer, MDS, Department of Pedodontics and Preventive Dentistry, Maitri College of Dentistry and Research Center, Anjora, Durg, Chhattisgarh, India.

Dr. Ankita Ukey

PG Student, Department of Pedodontics and Preventive Dentistry, Maitri College of Dentistry and Research Center, Anjora, Durg, Chhattisgarh, India.

Dr. Kritika Jaiswal

PG Student, Department of Pedodontics and Preventive Dentistry, Maitri College of Dentistry and Research Center, Anjora, Durg, Chhattisgarh, India.

Correspondence

Dr. Aditi Jain

Sr. Lecturer, Mds, Department Of Conservative Dentistry And Endodontics, Maitri College Of Dentistry And Research Center, Anjora, Durg, Chhattisgarh, India.

Endodontic management of second mesiobuccal canal in permanent first maxillary molar a case report

Dr. Aditi Jain, Dr. Abhinav Chand Singhal, Dr. Ankita Ukey, Dr. Kritika Jaiswal

Abstract

It is basic that the clinician ought to have extensive knowledge about the normal anatomy and its variations of the teeth as the deviations from the usual are extremely normal. An expanded attention of unusual anatomy and a superior comprehension of the root canal system guide the clinician in precise diagnosis and treatment of such variations so as to accomplish a fruitful endodontic result. The maxillary first molar has been appeared to have a wide variety in regard to the number of canals particularly noted in the mesiobuccal root. The present case report demonstrates the successful management of a maxillary molar in which the mesiobuccal root had two canals.

Keywords: maxillary molar, permanent, second mesiobuccal canal, variation

1. Introduction

The success of endodontic therapy is dependent on the quality of cleaning of the entire root canal system with three dimensional obturation [1]. Therefore it is almost important to have a thorough knowledge of the dental anatomy and its variation prior to initiation of treatment. Presence of additional canal must be confirmed in radiograph at different horizontal angulations [2].

Learning of canal morphology and its frequent varieties is an essential for endodontic treatment. These morphological varieties in root canal system play a significant role in the outcome of root canal therapy. The foremost common reasons for treatment failures in permanent maxillary first molars have been ascribed to failure in identifying extra canals particularly in the mesiobuccal root.

The present article reports the successful management of a permanent maxillary first molar with four canals in which the mesiobuccal root has two canals.

2. Case report

A 34 year old male patient reported to the department with chief complaint of severe pain in the upper right first molar teeth since 15 days. On clinical examination a deep occlusal carious lesion with right maxillary first molar was seen. The tooth was found to be tender on percussion. Radiographic examination revealed pulp exposure. After locating the MB2 orifice, inclining the dental or ultrasonic handpiece to the distal, as far as the access preparation permits, allows the first few millimeters of this overlying "roof" of calcified tissue to be safely eliminated. After this refinement of the access preparation, a more desired straight line access can be achieved. To facilitate location and instrumentation of MB2 canal, the access has to be rhomboidal in shape to allow the necessary mesially directed shaping. To treat maxillary second molar properly, an understanding of the morphology of the mesiobuccal canal system is mandatory. Initially the canal in the mesiobuccal root is the shape of a kidney bean. With continued deposition of secondary dentin, the isthmus between the poles become narrower and eventually may even close resulting in two canals. Because the mesiolingual segment of canal surrounds the smaller of the poles of the kidney bean, it will close off leaving a small space, thus making it more difficult to locate.

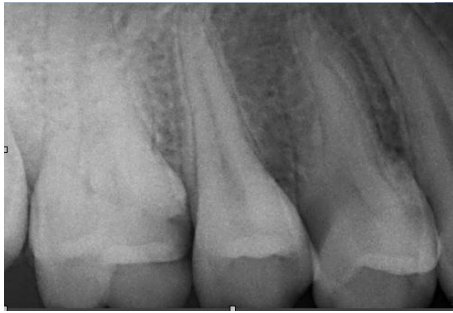


Fig 1: preoperative radiograph showing the right maxillary first molar had a deep carious lesion.

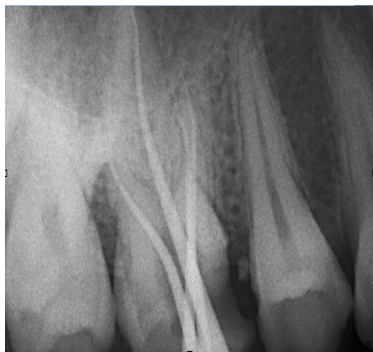

Fig 2: Master cone radiograph showing two mesiobuccal canals

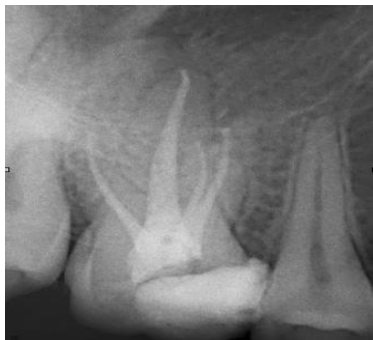

Fig 3: postoperative radiograph

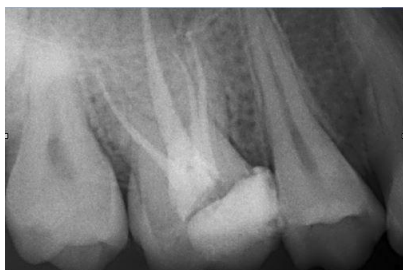

Fig 4: Follow up at 6 months

3. Discussion

In vitro studies of the mesiobuccal root canal system are slightly more likely to report two canals in the maxillary first molar than *in vivo* clinical studies [3] Pomeranz and Fishelberg found MB2 canals in 69% of the 100 teeth examined *in vitro* but could demonstrate its presence in only 31% of 100 teeth examined *in vivo* [4-7] The incidence of two canals in the mesiobuccal root was higher in laboratory studies (60.5%) compared to clinical studies (54.7%) [8] *In vitro* studies of the mesiobuccal root canal system are slightly more likely to report two canals in the maxillary first molar than *in vivo* clinical studies [9]. Pomeranz and Fishelberg found MB2 canals in 69% of the 100 teeth examined *in vitro* but could

demonstrate its presence in only 31% of 100 teeth examined *in vivo* [10, 11] The incidence of two canals in the mesiobuccal root was higher in laboratory studies (60.5%) compared to clinical studies (54.7%) [12]

Studies specifically addressing the mesiobuccal root have reported that the rate of additional root canals *in vitro* is more than *in vivo*. Many of these *in vitro* investigations of the mesiobuccal root canal anatomy reported the presence of a second canal but very few mentioned a third canal [2]. Two such reviews reported their rate to be in the vicinity of 1.1% and 10% [7] However, its presence has been documented in a few case reports. A case study of 140 extracted maxillary teeth has reported presence of three mesiobuccal canals in one tooth [7, 8] Ferguson and Favieri et al. detailed maxillary molars with three mesiobuccal canals with help of surgical operating microscope [13] Adanir likewise detailed a comparative case with four roots and six canals [14]. Martinez-Berna and Ruiz-Badanelli and Beatty reported the maxillary first molar with three separate mesiobuccal canals with separate foramina [15]. Kottoor et al. reported two maxillary first molars with three mesiobuccal canals in every tooth with the guide of Cone Beam Computed Tomography (CBCT) [16].

4. Conclusion

Thorough knowledge and careful learning of unpredictability of complexity of the root canal system and its varieties expanded operator experience and increased time per appointment with adequate illumination help in recognizable and treatment of these additional canals.

5. References

1. Fogel HM, Peikoff MD, Christie WH. Canal configuration in the mesiobuccal root of the maxillary first molar: A clinical study. *J Endod.* 1994; 20:135-7.
2. Görduysus MO, Görduysus M, Friedman S. Operating microscope improves negotiation of second mesiobuccal canals in maxillary molars. *J Endod.* 2001; 27:683-6.
3. Al Omer OE, Glennon J, Jennings M, Claffey NM. Root canal anatomy of maxillary first and second permanent molars. *Int Endod J.* 2000; 33:405-14.
4. Pomeranz HH, Fishelberg G. The secondary mesiobuccal canal of maxillary molars. *J Am Dent Assoc.* 1974; 88:119-24.
5. Imura N, Hata GI, Toda T, Otani SM, Fagundes MI. Two canals in mesiobuccal roots of maxillary molars. *Int Endod J.* 1998; 31:410-4.
6. Ibarrola JL, Knowles KI, Ludlow MO, McKinley IB. Jr Factors affecting the negotiability of second mesiobuccal canals in maxillary molars. *J Endod.* 1997; 23:236-8.
7. Stropko JJ. Canal morphology of maxillary molars: Clinical observations of canal configurations. *J Endod.* 1999; 25:446-50.
8. Wolcott J, Ishley D, Kennedy W, Johnson S, Minnich S. Clinical investigation of second mesiobuccal canals in endodontically treated and retreated maxillary molars. *J Endod.* 2002; 28:477-9.
9. Kulild JC, Peters DD. Incidence and configuration of canal systems in the mesiobuccal root of maxillary first and second molars. *J Endod.* 1990; 16:311-7.
10. Seidberg BH, Altman M, Guttuso J, Suson M. Frequency of two mesiobuccal root canals in maxillary permanent first molars. *J Am Dent Assoc.* 1973; 87:852-6.
11. Fogel HM, Peikoff MD, Christie WH. Canal configuration in the mesiobuccal root of the maxillary

- first molar: A clinical study. *J Endod.* 1994; 20:135-7.
12. Cleghorn BM, Christie WH, Dong CC. Root and root canal morphology of the human permanent maxillary first molar: A literature review. *J Endod.* 2006; 32:813-21.
 13. Favieri A, de Barros FGB, Campos LC. Root canal therapy of a maxillary first molar with five root canals: case report, *Brazilian Dental Journal.* 2006; 17(1):75-78,
 14. Adanir N. An unusual maxillary first molar with four roots and six canals: a case report, *Australian Dental Journal.* 2007; 52(4):333-335.
 15. Martinez-Berna A, Ruiz-Badanelli P. Maxillary first molars with six canals, *Journal of Endodontics.* 1983; 9(9):375-381.
 16. Kottoor J, Velmurugan N, Sudha R, Hemamalathi S. Maxillary first molar with seven root canals diagnosed with cone-beam computed tomography scanning: a case report, *Journal of Endodontics.* 2010; 36(5):915-921.