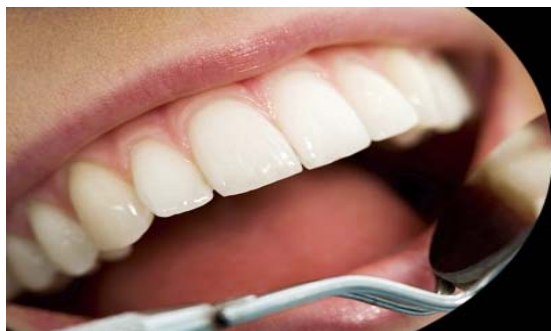



ISSN Print: 2394-7489  
ISSN Online: 2394-7497  
IJADS 2017; 3(2): 104-106  
© 2017 IJADS  
www.oraljournal.com  
Received: 20-02-2017  
Accepted: 21-03-2017

**Levent Demiriz**  
Bülent Ecevit University  
Faculty of Dentistry,  
Department of Pediatric  
Dentistry, Zonguldak, Turkey

**Baran Can Sağlam**  
Bülent Ecevit University  
Faculty of Dentistry,  
Department of Endodontics,  
Zonguldak, Turkey

## Root canal treatment of a mandibular second premolar with three roots and four canals: A case report

Levent Demiriz and Baran Can Sağlam

### Abstract

Comprehensive knowledge about the variations of morphology and anatomy of the roots and root canal systems in permanent teeth is an important factor to reach successful outcome. The aim of this case report was to explain nonsurgical endodontic treatment and long term follow-up of a mandibular second premolar with unusual root and root canal morphology. 10-year-old girl was referred with a complaint of severe toothache in her right mandibular second premolar tooth. During the endodontic treatment, it was observed by the radiographic evaluations that the tooth had three roots and four canals. In the 36<sup>th</sup> month follow-up session, complete healing of the tooth was determined. It was concluded that the variation of the mandibular second premolar tooth in the present case has never been reported. Therefore, the present case may be considered as a rare case by its unusual root and root canal morphology.

**Keywords:** Mandibular second premolar, root, root canal, variation

### 1. Introduction

One of the most important factors to gain success in root canal treatment is adequate knowledge of the clinician about the morphology and anatomy of the root canal systems [1, 2]. In permanent teeth, root and canal morphology may show variations and this situation is considered as a reason of endodontic failures [3]. The etiology of the variations is explained by the factors such as age, gender, and ethnicity [4]. The common knowledge about the mandibular second premolar is that the most of these teeth have one single root with a single canal [2, 4, 5]. On the other hand, several studies [5-7] reported the root and canal morphology of mandibular premolars having more than one root and canal. In 1978, Vertucci [6] reported eight different root canal morphologies of mandibular premolars, and the frequency of multiple root canals such as three or four canals was extremely rare. Additionally, Cleghorn *et al* [5] reported the rate of three rooted premolars as only 0.1% of all mandibular premolars. The aim of this case report was to explain nonsurgical endodontic treatment and long term follow-up of a mandibular second premolar with three roots and four canals.

### 2. Case Report

A systemically healthy, 10-year-old girl was referred to Bulent Ecevit University Faculty of Dentistry, Department of Pediatric Dentistry with a toothache in her right mandibular premolar region. The clinical examination revealed that the crown of the right mandibular second premolar tooth had a temporary filling material like Cavit. According to the parents, the patient was taken to a special clinic with the same complaint and the tooth was temporarily treated following the patient was directed to our clinic. The radiographic examination revealed an unusual situation that all mandibular premolars had more than one root, and the right mandibular second premolar tooth had three roots. Two of these roots located at buccal whereas one root located at lingual side. Additionally, the tooth had a periapical lesion which could be observed as a radiolucent area in periapical tissues (Fig. 1).

The treatment protocol was planned at the same session and root canal treatment of the right mandibular second premolar was decided. Following local anesthesia and placement of rubber dam, temporary filling material and caries lesion below the filling material was removed by using round #5 tungsten carbide burs in low speed. After this process, access cavity was prepared with water-cooled #4 round diamond burs in high speed, and four canal orifices were detected by using magnifying glasses (×2). Of them, two orifices were located at mesio-buccal

**Correspondence**  
**Levent Demiriz**  
Bülent Ecevit University  
Faculty of Dentistry,  
Department of Pediatric  
Dentistry, Zonguldak, Turkey

root, one orifice was located at disto-buccal, and one orifice was located at lingual root. The pulp tissue was extirpated from each root canal and working length of each root canal was determined using an apex locator (Root ZX; Morita, Tokyo, Japan). These lengths were confirmed by conventional intraoral periapical radiography. (Fig. 2) All root canals were cleaned and shaped up to the final size of 0.06/25 by using NiTi rotary files (Protaper Universal; Dentsply, Maillefer, Ballaiques, Switzerland). During the preparation process, each root canal was irrigated with copious 2.5% sodium hypochlorite (NaOCl). The final irrigation was carried out by using 5 ml 2,5% NaOCl and 5 ml 17% ethylene diamine tetra acetic acid (EDTA) solutions, respectively. Then all root canals were dried with sterile paper points (Dentsply, Maillefer, Ballaiques, Switzerland), and filled with AH Plus sealer with 0.06/25 sized gutta-percha single cone. After the root canal filling process, a periapical radiograph was taken to see the last situations of the fillings, and it was noticed that the filling of the disto-buccal root canal was unintentionally extruded during the cutting of the gutta-percha cones. The extrusion of the gutta-percha in the disto-buccal root was approximately 1 mm (Fig. 3). After the check-out process, it was decided to follow the clinical and radiographic outcomes of the endodontic treatment without any further intervention. Finally, coronal restoration was carried out by using adhesive composite resin. In the 36<sup>th</sup> month follow-up session, complete healing of periapical lesion was observed (Fig. 4) without retreatment. During these sessions, no clinical symptoms were observed.

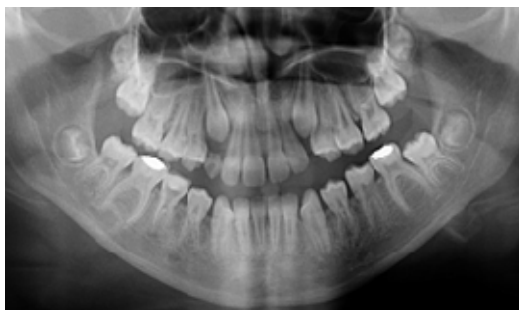

Fig 1: Panoramic radiograph of the case at the baseline.

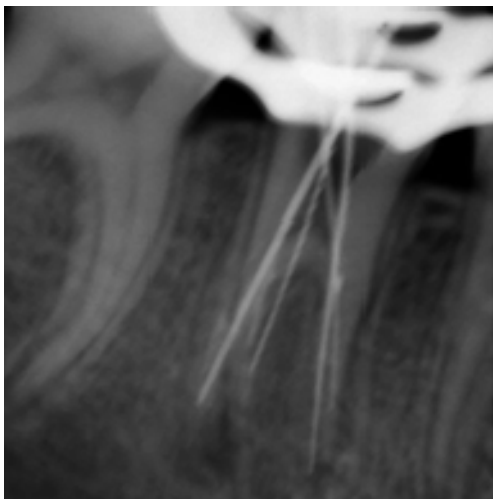


Fig 2: Periapical radiograph of the tooth during the calculation of the working lengths.

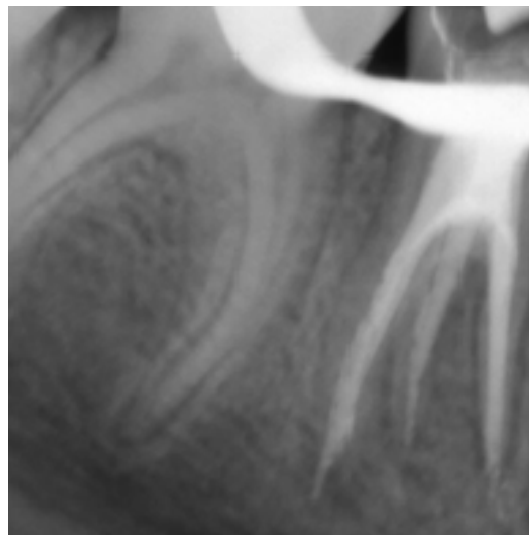


Fig 3: Periapical radiograph of the tooth with filled root canals.

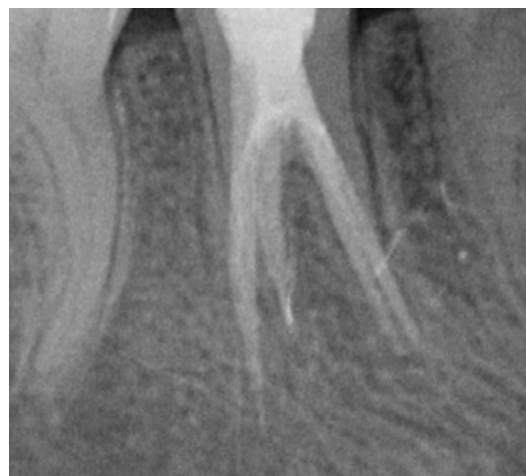


Fig 4: Periapical radiograph of the tooth at the session of 36th month

### 3. Discussion

In endodontic treatment, to reach successful treatment outcome requires comprehensive knowledge of root and root canal anatomy. Additionally, detailed and attentive radiographic examinations such as parallel and angled periapical radiographs largely contributes to determine number of roots and root canals [8]. On the other hand, unnoticed and untreated root canals are addressed for one of the major reasons of failure in endodontic treatment [9]. In the literature, it is well described that the mandibular second premolar tooth is typically of a single-rooted tooth [8]. On the other hand, different variations of root and root canal numbers were previously described for mandibular premolars [5-7]. At the meantime, it was stated that the variation of having three roots was extremely rare (0.1%) for the mandibular second premolar tooth [5]. Although, the appearance of these variations are rare, the present case showed that clinicians may encounter with these situations in any time, and Slowey [10] has highlighted that the mandibular premolars are the most difficult teeth for root canal treatment since their complicated and various root canal anatomy.

When the reported root canal variations of mandibular second premolars were evaluated in the literature, it was observed that the variations were more related with the number of the root canals than the numbers of the roots [2]. However, three rooted mandibular second premolars as seen in the present case were previously reported in several case reports [1, 2, 4, 11-13]. Differently, in 2008, Sachdeva *et al* [14] reported the endodontic management of a mandibular second premolar with four roots and four root canals, and they have stated that the occurrence of this variation has never been reported in the literature. In the present case, the treated mandibular second premolar tooth had three roots and four root canals, and we concluded that the variation in the present case has never been reported either. Therefore, the present case may be considered as a rare case by its unusual root and root canal morphology.

#### 4. Conclusion

The present case showed an unusual root canal morphology of a mandibular second premolar tooth. Understanding of the presence of unusual root canal morphologies contributes to the successful outcome of the root canal treatment.

#### 5. References

1. Fathi Z, Rahimi S, Tavakoli R, Amini M. A Three-rooted Mandibular Second Premolar: A Case Report. *Journal of Dental Research, Dental Clinics, Dental Prospects* 2014; 8(3): 184-186.
2. Gandhi B, Patil AC. Root canal treatment of a mandibular second premolar with three roots and canals - an anatomic variation. *Journal of Dentistry (Tehran, Iran)* 2013; 10(6): 569-574.
3. Cantatore G, Berutti E, Castellucci A. Missed anatomy: frequency and clinical impact. *Endodontic Topics* 2006; 15: 3-31
4. Saberi EA, Rasooli H, Movassagh Z. Retreatment of a mandibular second premolar with three roots: a case report. *Iranian Endodontic Journal* 2014; 9(2): 158-160.
5. Cleghorn BM, Christie WH, Dong CC. The root and root canal morphology of the human mandibular second premolar: a literature review. *Journal of Endodontics* 2007; 33(9): 1031-1037.
6. Vertucci FJ. Root canal morphology of mandibular premolars. *The Journal of the American Dental Association* 1978; 97(1): 47-50.
7. De Moor RJ, Calberson FL. Root canal treatment in a mandibular second premolar with three root canals. *Journal of Endodontics* 2005; 31(4):310-313.
8. Balakasireddy K, Kumar KP, John G, Gagan C. Cone Beam Computed Tomography Assisted Endodontic Management of a Rare Case of Mandibular First Premolar with Three Roots. *Journal of International Oral Health* 2015; 7(6): 107-109.
9. Hoen MM, Pink FE. Contemporary endodontic retreatments: an analysis based on clinical treatment findings. *Journal of Endodontics* 2002; 28(12):834-836.
10. Slowey RR. Root canal anatomy. Road map to successful endodontics. *Dental Clinics of North America* 1979; 23(4): 555-573.
11. Rödiger T, Hülsmann M. Diagnosis and root canal treatment of a mandibular second premolar with three root canals. *International Endodontic Journal* 2003; 36(12): 912-919.
12. Paul B, Dube K. Endodontic treatment of a mandibular second premolar with three roots and three canals. *Case Reports in Dentistry* 2014; 2014: 973410.
13. Hariharavel VP, Kumar AA, Ganesh C, Annamalai S, Ramar K, Aravindhyan R. Root canal treatment of mandibular second premolar with three separate roots and canals using spiral computed tomographic. *Case Reports in Dentistry* 2014; 2014: 816576.
14. Sachdeva GS, Ballal S, Gopikrishna V, Kandaswamy D. Endodontic management of a mandibular second premolar with four roots and four root canals with the aid of spiral computed tomography: a case report. *Journal of Endodontics* 2008; 34(1): 104-107.