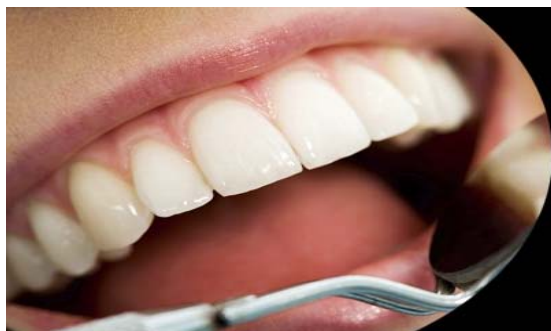



International Journal of Applied Dental Sciences

ISSN Print: 2394-7489
ISSN Online: 2394-7497
IJADS 2017; 3(3): 100-103
© 2017 IJADS
www.oraljournal.com
Received: 15-05-2017
Accepted: 16-06-2017

Dr. Nikita Sarraf
PG Student, Department of
Conservative Dentistry &
Endodontics, Mahatma Gandhi
Dental College & Hospital,
Jaipur, Rajasthan, India

Dr. Deepak Raisingani
MDS, PROF & HEAD,
Department of Conservative
Dentistry & Endodontics,
Mahatma Gandhi Dental College
& Hospital, Jaipur, Rajasthan,
India

Dr. Ashwini B Prasad
MDS, READER, Department of
Conservative Dentistry &
Endodontics, Mahatma Gandhi
Dental College & Hospital,
Jaipur, Rajasthan, India

Dr. Rakesh Singla
MDS, Professor, Department of
Conservative Dentistry &
Endodontics, J.C.D. Vidyapeeth
Dental College, Sirsa, Haryana,
India

Dr. Nidha Madan
MDS, Department of
Conservative Dentistry &
Endodontics, Mahatma Gandhi
Dental College & Hospital,
Jaipur, Rajasthan, India

Correspondence

Dr. Nikita Sarraf
PG Student, Department of
Conservative Dentistry &
Endodontics, Mahatma Gandhi
Dental College & Hospital,
Jaipur, Rajasthan, India

Oral lichenoid contact lesion to amalgam restoration and its management: A case report

Dr. Nikita Sarraf, Dr. Deepak Raisingani, Dr. Ashwini B Prasad, Dr. Rakesh Singla and Dr. Nidha Madan

Abstract

Dental amalgam has been used as a dental restoration for more than 165 years. However, the disadvantages of dental amalgam comprise poor aesthetics, local degradation, occasional allergic responses to some of its components or degradation products, and the toxicity of mercury. Amalgam and/or its components may cause type IV hypersensitivity reactions on the oral mucosa. Most patients with oral lichen planus (OLP) have no evidence of any association with dental restorative materials. However, some patients in contact or proximity to restorations involving amalgam or other materials causes these restorations may present oral lichenoid lesions (OLL) or Amalgam Contact Hypersensitive Lesion (ACHL). The diagnosis usually is based on the direct contact of the affected mucosa with the amalgam restorations, clinical appearance, and lack of migrations. The present case report presents a patient with unilateral oral lichenoid reactions (OLRs) to an amalgam restoration in the left mandibular molar region.

Keywords: Oral lichenoid reactions, oral lichen planus, dental amalgam, oral mucosa, Amalgam Contact Hypersensitive Lesion.

1. Introduction

Human oral mucosa is often subjected to many noxious stimuli, either hot or cold, acidic or alkaline substances, spiced or not so spicy foods. Among substance misusers, the oral mucosa is also in constant contact with tobacco, alcohol, or other substances taken through the mouth [1]. Many dental materials and medicaments contain substances that can cause hypersensitivity reactions of the oral mucosa or the skin [2-4]. Generally, the allergenic substances in the dental environment are local anaesthetic agents [5], antibiotics [6], restorative materials [7] and latex [8]. In people with restored teeth, one material that is present in significant amounts is dental amalgam [1]. Dental amalgam has been used as a material for dental restoration for more than 165 years [9]. However, some disadvantages of amalgam in comparison with adhesive composite restorations include problems with aesthetics; lack of adhesiveness, which requires removal of sound dental tissue to properly prepare the restoration cavity; and the potential toxicity of mercury for patients and the environment [9]. Most of the toxic injuries are associated with the mercury content of amalgam restorations, their symptoms are normally classified as delayed hypersensitivity reactions (type IV), and they were called oral lichenoid reactions (OLRs) by Finne *et al* [10]. These OLL are frequently observed in the tongue, gingiva, and buccal mucosa that are in direct contact with amalgam restorations [11], being classified in four types: lesions related to direct contact (OLLC), most commonly associated with amalgam restorations; lesions related to drugs (OLLG); lichenoid lesions in chronic graft versus host disease (cGVHD); and lesions associated with systemic diseases such as lupus erythematosus, the oral lichen planus [12]. OLRs affect oral mucosa in direct contact with amalgam restorations represent a delayed, type IV, cell-mediated immune response to mercury or many metals, such as gold, palladium, nickel, chrome, and cobalt, may induce OLRs [10, 13], and but the material most frequently associated with OLRs is dental amalgam, and the lesions are the consequence of a hypersensitivity to one of its components, often mercury, but sometimes copper, zinc, or tin [10, 14] and is also known as Amalgam Contact Hypersensitive Lesions (ACHL). The clinical occurrence of OLRs is similar to oral lichen planus. OLRs are often seen in direct topographic relation to the offending agent and are generally unilateral, and they can be reticular,

in the form of plaques, atrophic and erosive or a combination of the foregoing. However, classical OLP presents as bilateral and symmetrical, white, papular/reticular or red atrophic/ulcerative lesions affecting all areas of the oral mucosa [14-16].

The delayed and immediate reactions to mercury associated with amalgam disappear or improve after removal of the restoration and do not recur if similar materials are avoided. This report describes a case of hypersensitivity reaction associated with the mercury component of amalgam restorations in a female patient.

Case report

A 48-year-old woman was referred to our clinic with a complaint of soreness affecting the left buccal mucosa, which was worsened by consuming spicy foods. She had received an amalgam restoration 3 years back, and she first noticed symptoms 6 months before presentation, with the symptoms becoming progressively worse with time. Her medical history was non-contributory; she was taking no medications and had no known allergies. Intraoral examination disclosed the presence of a reticular, atrophic, lightly erythematous lesion affecting the buccal mucosa of left mandibular molar side. The lesion was in direct contact with the amalgam restoration (Figure 1). The remainder of the oral mucosa was normal. Given the close association of the lesions with the amalgam restorations, a provisional diagnosis of a lichenoid reaction to amalgam was made and the patient was patch tested using the European Standard and Dental Materials Series (Trolab Biodiagnostics Ltd, Worcestershire, UK) patch test allergens. A mix patch [Alloy + Hg] was placed on the fore arm and held in place for 48-72 hours with tape. After 72 hrs patient returned with the complaint of itching on the mix patch [Alloy + Hg]. Patch was removed and examined. A slight erythematous reaction was noted on mix patch area. The patient received local anesthesia of 2% lidocaine with 1:100,000 epinephrine. The amalgam restoration was removed under a rubber dam with copious irrigation and a high aspiration volume. The amalgam restoration of 36 & 38 was replaced with an interim restoration of Zinc Oxide Eugenol (DPI) and was kept on follow up for. After 15 days major signs and symptoms subsided (Figure 2) and the cavity was restored with light-cured posterior composite resin (Filtek p60, 3M ESPE, Seefeld, Germany). The patient was reviewed after 1 month, and the lesion was resolved (Figure 3). At the 6-month follow-up, no lesion was seen, and the patient had no discomfort (Figure 4).

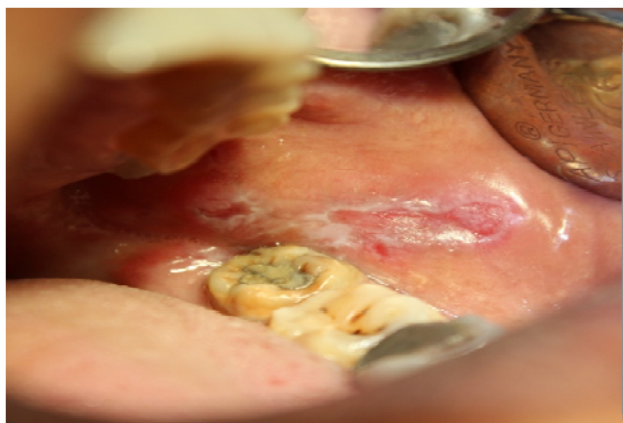


Fig 1: The lesion in direct contact with the amalgam restoration irt 36, 38

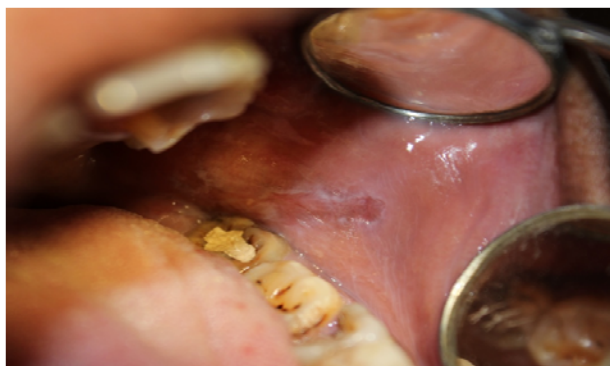

Fig 2: 15 days after temporising 36 & 38 with Zinc Oxide Eugenol, all the major signs and symptoms subsided

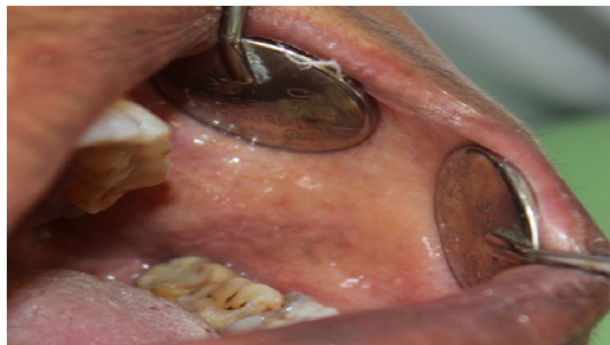

Fig 3: Complete resolution of lesion after 1 month follow up after restoration with composite irt 36 & 38

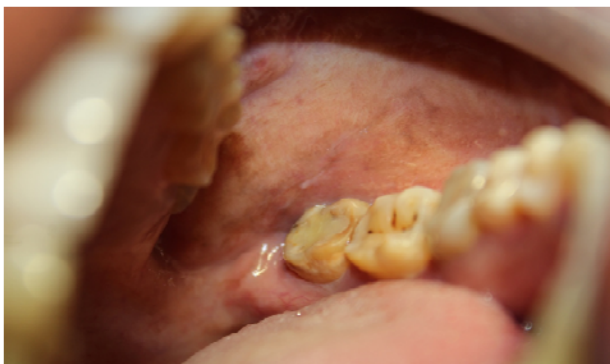

Fig 4: 6-month follow-up, no lesion was seen and no discomfort to patient

Discussion

Despite the common use of amalgam as a posterior restorative material, there have been a few reported cases of hypersensitivity to amalgam, and the most common type reported is delayed oral lichenoid reaction [17, 18]. OLRs caused by amalgam restorations can be found in the literature, with symptoms such as eczema, urticaria, wheals on the face and limbs, rashes and sometimes pink or Kawasaki disease [3, 14, 19]. In several cases, systemic reactions have been noted [20]. OLRs are not usually seen, likely because of amalgam's insolubility and the saliva's washing function [21, 22]. The pathophysiology of type IV hypersensitivity is complex. When haptens contact the oral mucosa, the reaction starts. A hapten is an incomplete antigen that binds to proteins/counterparts to produce complete antigens [23]. Sensitization usually occurs through contact of hapten with the oral mucosa. Rarely, sensitization may also occur by contact of hapten with skin. Memory T cells are activated soon after the

initial exposure. On re-exposure to the same allergen, a type IV hypersensitivity reaction occurs [19, 20]. This reaction may be delayed by at least

48 hours and the clinical presentation may vary depending on the severity of the reaction. These reactions can be either acute or chronic [20, 24, 25].

Clinical presentations vary based on the nature of reaction, type of allergen site and duration of contact. After removal of the offending amalgam restoration and with a filling made of composite restorations the lesion was completely disappeared. Patients with acute lesions may present with burning or redness [10, 20]. Vesicles are rarely seen and if present rupture in a short while after formation. Chronic lesions typically present as areas of erythema, oedema, desquamation and occasionally ulceration. In addition, allergic contact stomatitis can also present as erosions with rough surface and irregular borders, often surrounded by a red halo [10, 20, 24, 25]. In this case, the corrosion products of amalgam, including mercury, tin, copper and zinc, might have acted as haptens and started the inflammatory process, leading to a delayed oral lichenoid reaction.

The lesions of OLRs are similar to OLP. However, OLRs can be differentiated from OLP lesions. OLR lesions are usually in close proximity to amalgam restorations, and they are usually localized asymmetrically [26]. However, OLP lesions are more widespread and bilateral, with symmetrical occurrence attracting attention. A detailed medical history and clinical and histopathological examinations are important in diagnosing an OLR. The differential diagnosis of OLRs from other oral diseases, such as bullous diseases, leukoplakia, lupus erythematosus, etc., can be performed by histopathological examination.

The first step in recognition of allergy induced diseases is a detailed history of the present complaint and the clinical course. Various reports show the use of patch test and MELISA (memory lymphocyte immunostimulation assay) and in determining mercury sensitivity. Hypersensitivity reactions which are cell mediated such as contact dermatitis are demonstrated by using patch testing [27]. The method includes the epicutaneous application of a specific allergen at a defined concentration and in a defined vehicle which will induce a cutaneous inflammatory reaction in a sensitised person, but will cause no reaction in a non-sensitised person. Fregert [24] and many others [25, 28, 29] described a standard series of dental materials applied to the skin to carry out the epicutaneous test. Hensten-Apaetersen and Holland composed a standard series of allergens for use in epicutaneous tests to elucidate possible contact allergy to amalgam [24]. Dental series epicutaneous test batteries of patch test (Trolab® allergens, Trolab Biodiagnostics Ltd, Worcestershire, UK) are also commonly used [30]. MELISA (memory lymphocyte immuno stimulation assay test) is a modified lymphocyte stimulation test, based on evaluation of the proliferation of peripheral blood memory cells. It is used to measure immunological sensitisation induced by metals and to screen such individuals [31, 32]. Using MELISA®, Podzimek *et al.* [33] found that the lymphocytes of patients with mercury allergy produce less gamma interferon and more anti-sperm antibodies in supernatants after mercury stimulation of their lymphocytes. Various studies had shown that MELISA® is of diagnostic value in determining sensitivity to mercury and other amalgam associated metals and show correlation with the patch test.

In the present case the restorations were removed under rubber dam and high suction and were replaced with an

intermediate restorative material. The lesions healed up after removal of the stimuli. This clearly differentiates the lesion from the OLP, which is usually without aetiology. In patients of OLR, a positive patch test to components of amalgam may help to confirm the diagnosis. Final confirmation, however, depends upon resolution of the lesion after removal of the offending amalgam restoration. When the amalgam restoration has to be removed, it should always be done using rubber dam, abundant irrigation, and high aspiration volume, to diminish the exposition of the material [34-36].

Conclusion

It is recommended that patch tests should be performed in patients with OLR if the lesions are in close contact with amalgam fillings. Replacement of such restorations is recommended if there is a positive patch test reaction to mercury or components of amalgam and if there are no signs of concomitant generalized lichen planus.

References

- McParland H, Warnakulasuriya S. Oral Lichenoid Contact Lesions to Mercury and Dental Amalgam-A Review. *Journal of Biomedicine and Biotechnology*, 2012.
- Athavale PN, Shum KW, Yeoman CM, Gawkrödger DJ. Oral lichenoid lesions and contact allergy to dental mercury and gold. *Contact Dermatitis*. 2003; 49:264-5.
- Laeijendecker R, Dekker SK, Burger PM, Mulder PG, Van Joost T, Neumann MH. Oral lichen planus and allergy to dental amalgam restorations. *Arch Dermatol*. 2004; 140:1434-8.
- Udoye C, Aguwa E. Amalgam safety and dentists' attitude: a survey among a Subpopulation of Nigerian dentists. *Oper Dent*. 2008; 33:467-71.
- Wildsmith JA, Mason A, McKinnon RP, Rae SM. Alleged allergy to local anaesthetic drugs. *Br Dent J*. 1998; 184:507-10.
- Norris LH, Papageorge MB. The poisoned patient. Toxicologic emergencies. *Dent Clin North Am*. 1995; 39:595-619.
- Kaaber S. Allergy to dental materials with special reference to the use of amalgam and polymethylmethacrylate. *Int Dent J*. 1990; 40:359-65.
- Shah M, Lewis FM, Gawkrödger DJ. Delayed and immediate orofacial reactions following contact with rubber gloves during dental treatment. *Br Dent J*. 1996; 181:137-9.
- Bharti R, Wadhvani KK, Tikku AP, Chandra A. Dental amalgam: An update. *J Conserv Dent*. 2010; 13:204-8.
- McGivern B, Pemberton M, Theaker ED, Buchanan JA, Thornhill MH. Delayed and immediate hypersensitivity reactions associated with the use of amalgam. *Int J Oral Surg*. 1982; 11:236-9.
- Grossman S, Garcia BG, Soares I, Monteiro L, Mesquita R. Amalgam-associated oral lichenoid reaction: case report and management. *Gen Dent* 2008; 56:e9-11.
- Fardal O, Johannessen AC, Morken T. Gingivo-mucosal and cutaneous reactions to 5. amalgam fillings. *J Clin Periodontol* 2005; 32:430-3.
- Duxbury AJ, Ead RD, McMurrough S, Watts DC. Allergy to mercury in dental amalgam. *Br Dent J*. 1982; 152:47-8.
- Dunsche A, Kastel I, Terheyden H, Springer IN, Christophers E, Brasch J. Oral lichenoid reactions associated with amalgam: improvement after amalgam

- removal. *Br J Dermatol* 2003; 148:70-6.
15. Thorn JJ, Holmstrup P, Rindum J, Pindborg JJ. Course of various clinical forms of oral lichen planus. A prospective follow-up study of 611 patients. *J Oral Pathol*. 1988; 17:213-8.
 16. Eisen D, Carrozzo M, Bagan Sebastian JV, Thongprasom K. Number V Oral lichen planus: clinical features and management. *Oral Dis*. 2005; 11:338-49.
 17. Eley BM. The future of dental amalgam: a review of the literature. Part 6: Possible harmful effects of mercury from dental amalgam. *Br Dent J*. 1997; 182:455-9.
 18. Jolly M, Moule AJ, Bryant RW, Freeman S. Amalgam-related chronic ulceration of oral mucosa. *Br Dent J*. 1986; 160:434-7.
 19. Laine J, Kalimo K, Forssell H, Happonen RP. Resolution of oral lichenoid lesions after replacement of amalgam restorations in patients allergic to mercury compounds. *Br J Dermatol*. 1992; 126:10-5.
 20. McGivern B, Pemberton M, Theaker ED, Buchanan JA, Thornhill MH. Delayed and immediate hypersensitivity reactions associated with the use of amalgam. *Br Dent J*. 2000; 188:73-6.
 21. De Rossi SS, Greenberg MS. Intraoral contact allergy: a literature review and case reports. *J Am Dent Assoc*. 1998; 129:1435-41.
 22. Dunsche A, Frank MP, Luttes J, Acil Y, Brasch J, Christophers E *et al* Lichenoid reactions of murine mucosa associated with amalgam. *Br J Dermatol*. 2003; 148:741-8.
 23. Aggarwal V, Jain A, Kabi D. Oral lichenoid reaction associated with tin component of amalgam restorations: a case report. *Am J Dermatopathol*. 2010; 32:46-8.
 24. Holmstrup P. Oral mucosa and skin reactions related to amalgam. *Adv Dent Res*. 1992; 6:120-4.
 25. Djerassi E, Berova N. The possibilities of allergic reactions from silver amalgam restorations. *Int Dent J*. 1969; 19, 481-8.
 26. Lamey PJ, McCartan BE, MacDonald DG, MacKie RM. Basal cell cytoplasmic autoantibodies in oral lichenoid reactions. *Oral Surg Oral Med Oral Pathol Oral Radiol Endod*. 1995; 79:44-9.
 27. Adams S. Allergies in the workplace. *Curr Opin related to amalgam*. *Adv Dent Res, Allergy Clin Immunol*. 2006; 19:82-86.
 28. Lundstrom IM. Allergy and corrosion of dental materials in patients with oral lichen planus. *Int J Oral Surg*. 1984; 13:16-24.
 29. White IR, Smith BG. Dental amalgam dermatitis. *Br Dent J*. 1984; 156:259-60.
 30. Ismail SB, Kumar SK, Zain RB. Oral lichen planus and lichenoid reactions: etiopathogenesis, diagnosis, management and malignant transformation. *J Oral Sci*. 2007; 49:89-106.
 31. Stejskal V. MELISA - an *in vitro* tool for the study of metal allergy. *Toxicol In Vitro* 1994; 8:991-1000.
 32. Strejskal VDM, Danersund A, Lindvall A, Hudecek R. Metal-specific lymphocytes: biomarkers of sensitivity in man. *Neuro Endocrinol Lett*. 1999; 20:289-298.
 33. Podzimek S, Prochazkova J, Bultasova L, Bartova J. Sensitisation to inorganic mercury could be a risk factor for infertility. *Neuro Endocrinol Lett*. 2005; 26:277-282.
 34. Atesagaoglu A, Omurlu H, Ozcagli E, Sardas S, Ertas N. Mercury exposure in dental practice. *Oper Dent*. 2006; 31:666-9.
 35. Gordan VV, Riley JL, Blaser PK, Mjor IA. 2-year clinical evaluation of alternative treatments to replacement of defective amalgam restorations. *Oper Dent*. 2006; 31:418-25.
 36. Szep S, Baum C, Alamouti C, Schmidt D, Gerhardt T, Heidemann D. Removal of amalgam, glass-ionomer cement and compomer restorations: changes in cavity dimensions and duration of the procedure. *Oper Dent*. 2002; 27:613-20.