



## International Journal of Applied Dental Sciences

ISSN Print: 2394-7489  
ISSN Online: 2394-7497  
IJADS 2017; 3(4): 258-260  
© 2017 IJADS  
www.oraljournal.com  
Received: 04-08-2017  
Accepted: 05-09-2017

**Lalitha Chintala**  
Department: Oral Medicine and  
Radiology, MallaReddy Institute  
of Dental Sciences, Suraram,  
Quthbullapur, Hyderabad,  
Telangana, India

**Bhavya B**  
Department: Oral Medicine and  
Radiology, MallaReddy Institute  
of Dental Sciences, Suraram,  
Quthbullapur, Hyderabad,  
Telangana, India

**YC Chaitanya**  
Department: Oral Medicine and  
Radiology, MallaReddy Institute  
of Dental Sciences, Suraram,  
Quthbullapur, Hyderabad,  
Telangana, India

**P Vinil Chaitanya**  
Department: Oral Medicine and  
Radiology, MallaReddy Institute  
of Dental Sciences, Suraram,  
Quthbullapur, Hyderabad,  
Telangana, India

**D Mamatha**  
Department: Oral Medicine and  
Radiology, MallaReddy Institute  
of Dental Sciences, Suraram,  
Quthbullapur, Hyderabad,  
Telangana, India

**G Sathwik**  
Department: Oral Medicine and  
Radiology, MallaReddy Institute  
of Dental Sciences, Suraram,  
Quthbullapur, Hyderabad,  
Telangana, India

### Correspondence

**Lalitha Chintala**  
Department: Oral Medicine and  
Radiology, MallaReddy Institute  
of Dental Sciences, Suraram,  
Quthbullapur, Hyderabad,  
Telangana, India

## Dense bony islands of the maxillofacial region: A radiological study

**Lalitha Chintala, Bhavya B, YC Chaitanya, P Vinil Chaitanya, D  
Mamatha and G Sathwik**

### Abstract

**Aims:** To determine the prevalence of dense bony islands in the jaw by radiographic evaluation and to investigate the relationship between the findings in relation to age, gender, and localization.

**Methods and Material:** The study included 2305 panoramic radiographs obtained from the patients whose ages ranged from 10 to 89 and who visited the Department of Oral medicine and Radiology in the Malla Reddy institute of dental sciences, Hyderabad, Telangana over a period of 1 year.

**Results:** Of 2,305 patients, 72 patients (3.12) had DBI. The prevalence obtained in our study was in the range reported in the literature. DBI was detected more often in mandible rather than the maxilla. In addition, mandibular molar localization was the most common localization, and most of the lesions were associated with root apices.

**Conclusion:** DBI can be defined as developmental variations of normal bony architecture, which are unrelated to local stimuli. The lesions can arise at any age, any location with no sex predilection, and DBI usually requires no treatment other than diagnosis. In addition, it is important to recognize this anomaly, evaluate radiographs carefully and distinguish it from other bone variations such as primary or metastatic tumours, which is much more significant clinically in dental examinations.

**Keywords:** dense bony island, orthopantomograph, mandible

### Introduction

A "Dense Bone Island" (DBI) is a localized, well defined, radiopaque mass in the jaw with a round, elliptical or irregular shape and a variable size. Most of these lesions are asymptomatic. Dense Bony Island (DBI) is defined as a focus of compact bone within the spongiosa, probably representing a developmental error of endochondral ossification. BIs typically manifest as an incidentally discovered, well-defined homogenous radiopacity that is of unknown cause and cannot be attributed to any inflammatory, dysplastic, neoplasia, or systemic disorder<sup>[2]</sup>.

These lesions may be accepted as developmental intraosseous anatomic variations and should be classified separately from the cases resulting from inflammatory origin or systemic disease. These asymptomatic lesions are generally discovered as incidental findings on radiographs taken for other reasons.

In the present study DBI of various sizes, ranging from 2 or 3 mm to 1 or 2 cm in diameter were observed. DBI may occur at root apexes, between the roots, or in a separate location away from the teeth, primarily in the premolar/molar region and with a predilection for the mandibular arc. The purpose of this study was to determine the prevalence and distribution of DBI in the jaws of the patients attending our department by examining the panoramic radiographs of the patient and to investigate the relationship of the findings to the age and gender in the Hyderabad

### Materials and methods

A total of 2305 dental patients attended the Department of Oral Medicine and Radiology, Malla Reddy Institute of Dental Sciences, Hyderabad, Telangana in the year of 2016 participated in the study, which was based on the panoramic radiographs of the patients taken during routine dental examination, and all the digital radiographs were viewed on the same LCD (liquid crystal display) monitor.

Two well-trained examiners observed the radiographs. All the radiographs (OPG) were obtained with PLANMECA PROMAX machine (Finland). The radiographs that displayed the jaws without asymmetry, distortion or error in patient positioning or exposure were included in the study.

For the diagnosis, DBI was defined as a localized, well defined, radiopaque mass in the jaw with a round, elliptical or irregular shape and a variable size. Most of these lesions are asymptomatic vary in size from a minimum of 3 mm to more than 2 cm. The patients who had a questionable DBI and who met the following criteria were excluded from this study.

- Radiopacities directly associated with deep caries or large restorations;
- The characteristics of the lesion were mixed with radiopaque-radiolucent areas in the form of periapical cemental dysplasia and other benign fibro-osseous lesions or an odontome;
- The remnants of deciduous or permanent teeth were clearly identifiable;

- The radiopacities were interpreted as a tori or exostoses, salivary calculus, tonsillolith, or calcified lymph node;
- Solitary radiopacities in edentulous regions.

DBI were classified according to site and internal characteristics as noted as follows<sup>[3]</sup> [figures: 1-4]

- Type I. Interradicular: Limited to the area between the roots
- Type II. Apical and interradicular: At the apices with extension between the roots;
- Type III. Separate: Apical and clearly separated from teeth and lamina dura;
- Type IV. Apical: Predominantly located around the apices of the roots
- Type V. Completely separate: DBI present in other than teeth bearing areas

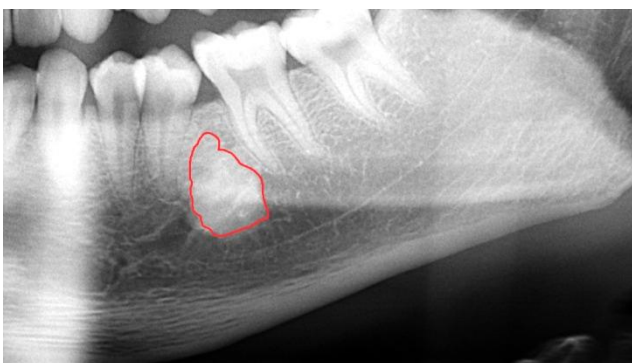


Fig 1: type I

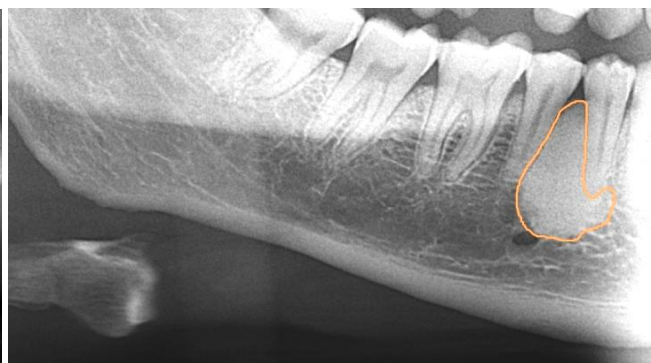

Fig 2: type II

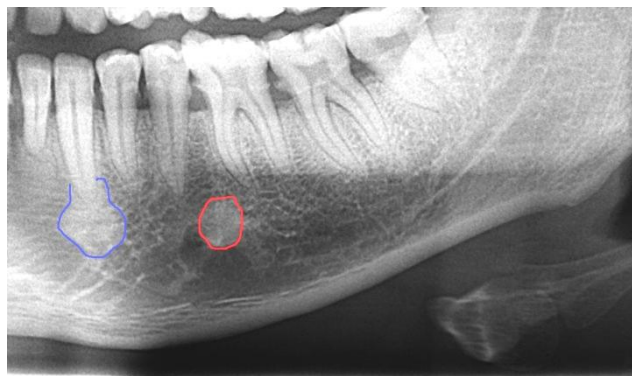

Fig 3: type III

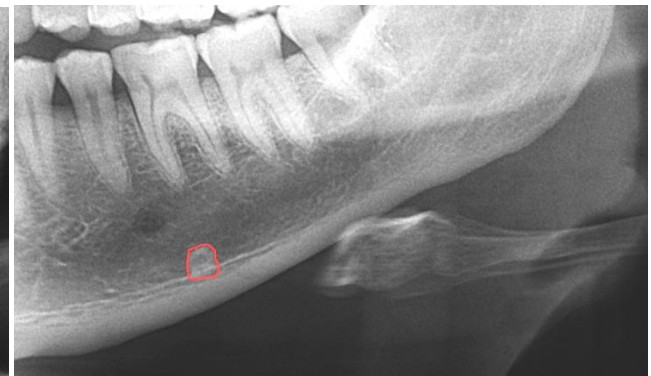

Fig 4: type IV

For assessment of the study sample all the digital radiographs were viewed on the same LCD (liquid crystal display) monitor. Two well-trained examiners observed the radiographs without the knowledge of age and gender of study group. Chi-square test was performed to evaluate the difference in the prevalence of DBIs between gender groups and radiographic appearance of DBIs. All statistical analyses were performed by using the SPSS 17.0 (SPSS Inc., Chicago, IL, USA) for Windows. Reproducibility to test intra- and inter-examiner reliabilities, two different examiners staged the prevalence of DBIs on 100 randomly selected radiographs. Each examiner repeated the process after 1 month (intra-examiner), and Cohen's kappa test was performed to calculate the intra- and inter-examiner agreements.

**Results:** Intra and inter observer differences were not found

in the repeated observing of a sub-sample of 100 radiographs ( $P > 0.05$ ). Intra-observer consistency was rated at 94%, whereas inter-observer agreement was 89%.

**Incidence**

A total of 72 patients in the DBIs group were identified from a total sample population of 2305 patients with a prevalence of 3.12

**Gender and age predilection**

The patient population as a whole consisted of approximately 49.3 % females and 50.7% males. The prevalence of DBIs among females was 62.5% (45 females) and 37.5% (27 males) among males. There was significant difference in the prevalence of DBIs between the males and females. In our study, a high prevalence of DBI is noted in females.

The ages of the study group ranged from 10 years to 89 years with a median of 42 years. The earliest age at which a DBI was detected is 16 years. The number of DBIs in the present study was found to be significantly higher in the 5<sup>th</sup> and 6<sup>th</sup> decades in life (40-49, 50-59) than in other periods [Table 1].

**Distribution and Presentation**

In our study all the DBIs were found in mandible. There were 82 variations detected of 72 patients, all the DBIs (100%) noted in mandible. Of the subjects with multiple variations, 8 patients had 2 DBIs, and 1 patients had 3DBIs. Pre-molar and molar localization in the mandible was the most common localization [Table 2].

**Table 1:** Age and Sex distribution of patients with DBI

Age in years	Male	Female	Total	All patients	Percentage
10-19	0	1	1	151	0.05
20-29	5	9	14	402	0.61
30-39	5	6	11	508	0.47
40-49	9	8	17	568	0.73
50-59	5	15	20	360	0.86
60-69	1	6	7	233	0.31
70-79	1	0	1	63	0.05
80-89	1	0	1	20	0.05
Total	27	45	72	2305	3.12

**Table 2:** Location of DBIs in the mandible.

Location	Type of Dense Bony Island				
	I	II	III	IV	V
Incisor – canine region	1	3	3	9	-
Premolar – molar region	5	4	21	30	-
Other regions	-	-	-	-	6

**Discussion**

BIs, congenital or developmental in origin, are developmental variations of normal bone architecture unrelated to a local stimulant. None showed bony expansion buccolingually, nor did they displace adjacent teeth or bony anatomic structures. They can be found in the most parts of the skeleton with a frequency reported to be approximately 1% [4].

The prevalence of DBI in previous studies ranged from 1.84 to 6.1<sup>2</sup>, in our study it is 3.12. The difference in prevalence in various studies can be attributed mainly to ethnic diversity for example mongoloid group shows decreased prevalence of DBI when compared to other groups. One other reason being, the different ways in which DBI is defined.

In our study there was significant difference in the prevalence of DBIs between the males and females. This finding agrees Geist and Katz [5] and McDonnell [6] reported a higher prevalence among women than among men. The main cause might be closely related to the sample size and age. However, Yonetsu *et al.* [7] and Kawai *et al.* [8] reported no difference in the prevalence between males and females.

The ages of the study group ranged from 10 to 89 years with a median of 42 years. DBIs can arise at any age, and furthermore the number of DBIs was found to be significantly higher in the 5<sup>th</sup> and 6<sup>th</sup> decades of life (40-49 and 50-59 years) than in other periods [Table 1]. However, Miloglu [9] found that there is marked frequency in the 3<sup>rd</sup> and 4<sup>th</sup> decades of life. Based on the present study, the sample size and following criteria are the major factors behind the phenomenon. For instance, we excluded radiopacities occurring in edentulous regions, and these regions might also be areas of condensing osteitis that remained after tooth

extraction. As another reason, the high prevalence of DBIs lesions in the 5<sup>th</sup> and 6<sup>th</sup> decades of life (40-49 and 50-59 years) coincides with the maximum bone mass acquisition in these periods.

In our study all the DBIs were found in mandible 100% with presentation primarily in the pre-molar/ molar region (62.1%). [Table: 2] Reason might be the differences in blood supply and anatomy of the jaws. In our study 77% of DBI were found in the categories of III and IV. These findings agree with Sisman [10], traumatic occlusion and traumatic movement of teeth is known to be a possible explanation for their higher prevalence in these regions. Among 72 patients with DBI, 9 patients presented with more than one DBI, of which 8 had 2 DBIs and 1 had 3 DBIs.

**Conclusion**

DBI is a developmental variations of normal bony architecture unrelated to local stimuli. The lesions can arise at any age, at any location, and with no sex predilection, and usually requires no treatment other than diagnosis by recognition. Generally, the lesions are likely to remain for years, and surgical intervention is not recommended. To be sure that the clinical diagnosis is correct, periodic follow-up of the lesions is necessary.

**References**

1. Cerulli Mariani G, Favaretti F, Lamazza L, De Biase A. Dense Bone Island Of The Jaw: A Case Report, Oral & Implantology - Anno I - N. 2, 2008.
2. Li N, You M, Wang H, Ren J, Zhao S, Jiang M *et al.* Bone islands of the craniomaxillofacial region. J Cranio Max Dis, 2013; 2:5-9.
3. Wood NK, Goaz PW. Differential diagnosis of oral lesions and maxillofacial lesions. Mosby St. Louis; 1997.
4. Onitsuka H. Roentgenologic aspects of bone Islands. Radiology. 1977; 123:607-12.
5. Geist JR, Katz JO. The frequency and distribution of idiopathic osteosclerosis. Oral Surg Oral Med Oral Pathol. 1990; 69:388-93.
6. McDonnell D. Dense bone island. A review of 107 patients. Oral Surg Oral Med Oral Pathol. 1993; 76:124-8.
7. Yonetsu K, Yuasa K, Kanda S. Idiopathic osteosclerosis of the jaws: Panoramic radiographic and computed tomographic findings. Oral Surg Oral Med Oral Pathol Oral Radiol Endod. 1997; 83(13):517-21.
8. Kawai T, Hirakuma H, Murakami S, Fuchihata H. Radiographic investigation of idiopathic osteosclerosis of the jaws in Japanese dental outpatients. Oral Surg Oral Med Oral Pathol. 1992; 74:237-42.
9. Miloglu O, Yalcin E, Buyukkurt MC, Acemoglu H. The frequency and characteristics of idiopathic osteosclerosis and condensing osteitis lesions in a Turkish patient population. Med Oral Patol Oral Cir Bucal. 2009; 14:e640-5.
10. Yildiray Sisman, Elif Tarim Ertas, Huseyin Ertas, Ahmet Ercan Sekerci. The Frequency and Distribution of Idiopathic Osteosclerosis of the Jaw. European Journal of Dentistry. 2011; 5:409-413.