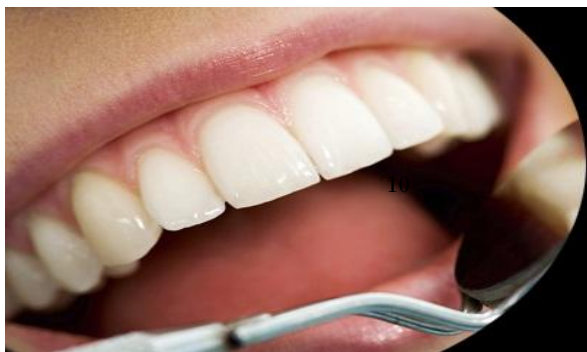



ISSN Print: 2394-7489
ISSN Online: 2394-7497
IJADS 2018; 4(1): 98-100
© 2018 IJADS
www.oraljournal.com
Received: 24-11-2017
Accepted: 26-12-2017

Dr. Imtiyaz Ahmed Magray
Senior Resident,
Dept. Of Prosthodontics,
Government dental college &
hospital, Srinagar, Jammu and
Kashmir, India

Dr. Raisa Rashid
Resident, Dept. Of
Prosthodontics, Govt. Dental
College and Hospital, Srinagar,
Jammu and Kashmir, India

Dr. Jyoti Paliwal
Professor, Dept. Of
Prosthodontics, Govt. Dental
College and Hospital, Jaipur,
Rajasthan, India

Survey of impression materials and techniques in fixed partial dentures among the practitioners in Kashmir

Dr. Imtiyaz Ahmed Magray, Dr. Raisa Rashid and Dr. Jyoti Paliwal

Abstract

Objective: Evidence suggests that impression materials and techniques used in general dental practice for fixed partial dentures vary from those taught in dental schools. The aim of this survey was to integrate impression techniques evolved all over the years for fixed partial dentures and to know the techniques and materials which are used in the present day by the practitioners.

Materials and Methods: A total of 120 questionnaires were sent to various practitioners in Kashmir, out of which 100 questionnaires were filled.

Results: The results showed that 80% of dentists (65%, urban areas) use elastomeric impression materials as well as irreversible hydrocolloids and 15% use irreversible hydrocolloid only. Elastomeric impression technique practiced most commonly is putty reline with/without spacer (77%); other techniques are multiple-mix and monophasic techniques.

Conclusion: The ideal materials, technique, and armamentarium are required for the long-term success of the treatment for fixed partial denture. Also, if the ideal procedure is not followed, it will lead to a compromised fit of the final prosthesis and failure of the treatment.

Keywords: Survey, impression materials, fixed partial dentures among, Kashmir

1. Introduction

Prosthodontics, as a specialty, has evolved abundantly in past few years. Materials and technological advances keep changing every day. Twentieth century witnessed remarkable changes with regard to human longevity worldwide, and the twenty-first century is set to carry forward the gains in longevity further, both in the developing world and the developed world [1]. Various impression materials and techniques came into use since times earlier till today for fixed partial dentures, and all of them have some advantages and disadvantages and are suitable for specific conditions.

This study used a questionnaire-based survey to assess and know the impression materials and techniques for fixed partial dentures that are being followed by the practitioners of Kashmir.

2. Materials and Methods

A questionnaire was designed to assess the details of the impression materials and techniques in fixed partial denture. This questionnaire was initially sent to a group of dentists in Kashmir through e-mail, and handing it personally as well. An accompanying letter described the aims of the study and how the data would be used.

3. Results

A total of 120 questionnaires were sent to various practitioners all over Kashmir out of which 100 questionnaires were filled the data were collected anonymously.

Out of the 100 dentists who responded to the questionnaire, 20% were prosthodontists and 80% were nonprosthodontists. The survey results show the following:

1. There are 29% practitioners who do not take diagnostic impressions and proceed with the tooth preparation after the clinical intraoral examination, (Figure 1).
2. Amongst the prosthodontists, 28% use only full arch impression trays, 62% use full arch and special trays, and 10% use full arch, partial arch, and special trays. Amongst the other practitioners, 49% use only full arch impression trays, 12% use full arch and special trays,

Correspondence

Dr. Imtiyaz Ahmed Magray
Senior Resident,
Dept. Of Prosthodontics,
Government dental college &
hospital, Srinagar, Jammu and
Kashmir, India

and 39% use full arch, partial arch, and special trays (Figure 2).

3. 72% of practitioners use gingival retraction cord, 24% use gingival retraction cord and Expasyl. (Figure 3).
4. Amongst the prosthodontists 63% use addition silicone, 21% use addition silicone and alginate, and 15% use only alginate. Amongst other practitioners, 41% use addition silicone, 26% use addition silicone and alginate, and 55% use only alginate (Figure 4).
5. Amongst the prosthodontists, 76% use putty relin technique with and without spacer and 23% use putty relin with/without spacer and single-mix technique. Amongst the other practitioners, 78% use putty relin technique with and without spacer and 21% use putty relin with/without spacer and single-mix technique (Figure 5).
6. Amongst the prosthodontists, 84% use type IV stone and 15% use type III stone. Amongst the other practitioners, 44% use type IV stone and 55% use type III stone (Figure 6).

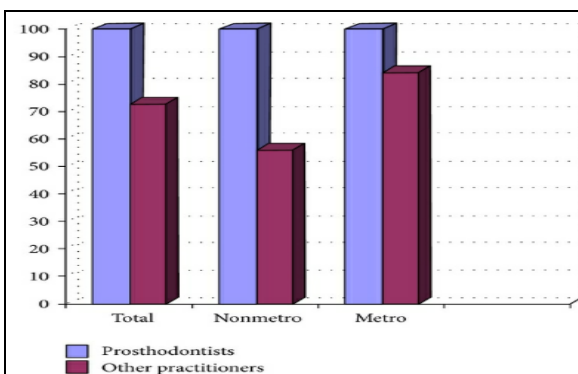


Fig 1: Graph showing the % of practitioners using alginate for diagnostic impressions.

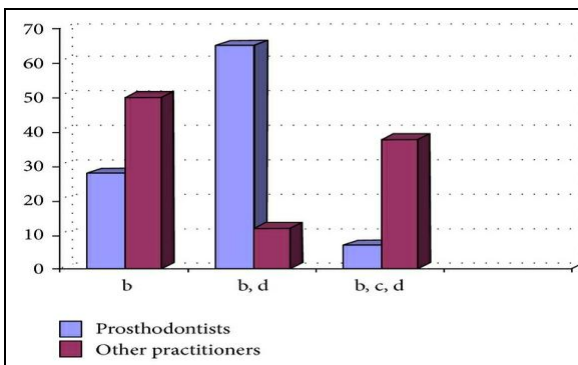


Fig 2: Graph showing the type of impression tray being used by the practitioners in %.

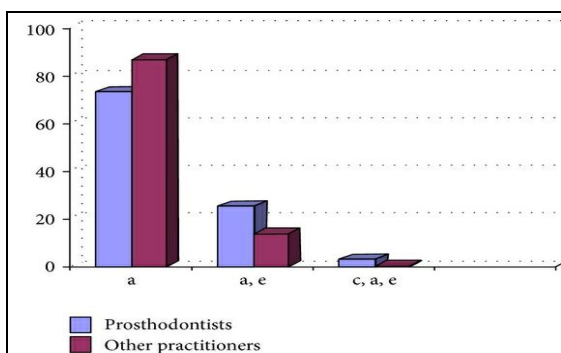


Fig 3: Graph showing the usage of gingival retraction materials by the practitioners in %.

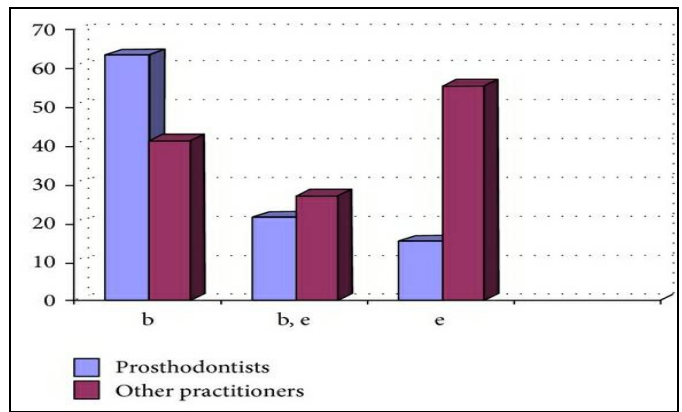


Fig 4: Graph showing the impression material being used by the practitioners (in %)

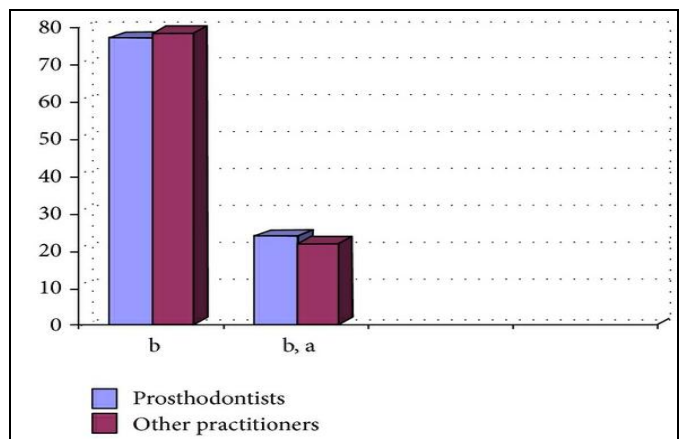


Fig 5: Graph showing the impression technique being followed by the practitioners (in %) for elastomeric impression materials.

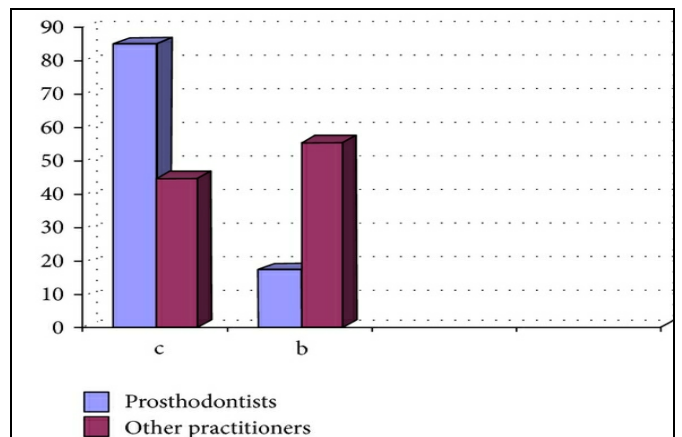


Fig 6: Graph showing the material used for pouring the impressions by the practitioners (in %).

4. Discussion

The questionnaire results were assessed in general, and it was found that the recommended materials and techniques were followed by most of the prosthodontists but not by most of the general practitioners.

Diagnostic impressions are of utmost importance for the treatment planning in fixed partial dentures. The diagnostic models when assessed will give the treatment outcome that is planned and any other treatment if required before proceeding with the fixed partial denture treatment, for example, enameloplasty of the opposing supraerupted tooth or up righting of the abutment tooth, and so forth.

The impression trays used by many practitioners are the full arch impression trays. The full arch impression tray has many

advantages as it records complete arch and the practitioner can make the impression with proper control over the setting time of the impression material unlike the dual arch impression tray. The dual arch impression tray is technique sensitive as the clinician needs to record both arches in the limited working time with the proper recording of the prepared teeth with the light body material. But the advantage is less time required for impression making as both arches are recorded simultaneously. Special trays are the best impression trays with the advantages of good confirmation to the arch, requirement of lesser material, and being economical as well. The partial arch tray is a poor choice for impression making as full arch recording is mandatory for proper mounting of the models, and further fabrication of the prosthesis depends on this mounting ^[2].

Gingival retraction cord is being used since times earlier for gingival retraction to make impressions in FPD. The hemostatic agents are also used along with it to achieve desired hemostasis. The advantage of using a cord is that it is inexpensive and can achieve varying degrees of retraction. But, cords can be painful and uncomfortable for the patient. Also the sulcus collapses soon after the removal of the cord; that is, it might rupture the epithelial attachment. Hemostasis achieved is limited, and the placement of the cord in the sulcus takes time. An electrosurgery unit may be used for tissue removal before impression making. Electrosurgery is not recommended as the concentrated electrical current at the tip of electrodes can generate heat, which may cause osseous or mucosal necrosis, and also there is a potential for gingival recession after treatment ^[3, 4]. The consistency of Expasyl is especially formulated so as not to damage the healthy periodontium; the phenomena of gingival recession or bone resorption are thus avoided. Gingival retraction is obtained by a single application of Expasyl in the sulcus. On contact with crevicular fluid, this material provides mild displacement of the gingiva within two minutes ^[5, 6]. Expasyl, easily visible owing to its color, is simply eliminated by an air and water spray, and a dry and widely opened sulcus is then obtained. It is painless when used on a healthy periodontium. Absence of bleeding or oozing allows achieving a perfectly dry sulcus ^[7]. For impression making, elastomeric impression materials are the most superior in terms of recording finish lines and the surface detail of the prepared teeth; the disadvantages are delayed poring for addition silicone, difficulty in recording the arches with undercuts for polyether, and so forth ^[8-14]. Amongst the hydrocolloids, laminate technique, that is, the agar alginate technique, is better than using agar or alginate individually as agar will record the prepared teeth accurately and the remaining arch is recorded with alginate ^[15].

For the technique of impression making, the single-phase (monophase) technique is faster and easier to use. The putty reline with spacer technique requires the use of spacer and is faster than using the putty reline without the spacer as in the latter; the space needs to be created for the light body syringe material using a putty cutter.

The impressions should be poured in type IV stone owing to its obvious higher mechanical properties as compared to type III stone. The final prosthesis accuracy of fit depends on this factor as well.

5. Conclusion

The ideal materials, technique, and armamentarium are required for the long-term success of the treatment for fixed partial denture. Single tooth when prepared and cemented with crown is at 3% risk for caries and endodontic failure and

the abutment teeth prepared for multiple-unit FPD, are at 15% risk for caries and endodontic failure. Also, if the ideal procedure is not followed, it will lead to a compromised fit of the final prosthesis and failure of the treatment.

6. References

1. Talwar M, Chawla H. "Geriatric dentistry: is rethinking still required to begin undergraduate education?" *Indian Journal of Dental Research*. 2008; 19(2):175-177.
2. Mitchell ST, Ramp MH, Ramp LC, Liu PR. "A preliminary survey of impression trays used in the fabrication of fixed indirect restorations," *Journal of Prosthodontics*. 2009; 18(7):582-588.
3. Wilhelmsen NR, Ramfjord SP, Blankenship JR. "Effects of electro surgery on the gingival attachment in rhesus monkeys," *Journal of Periodontology*. 1976; 47(3):160-170.
4. Lampert SH. "Combined electrosurgery and gingival retraction," *The Journal of Prosthetic Dentistry*. 1970; 23(2):164-172.
5. Al Hamad KQ, Azar WZ, Alwaeli HA, Said KN. "A clinical study on the effects of cordless and conventional retraction techniques on the gingival and periodontal health," *Journal of Clinical Periodontology*. 2008; 35(12):1053-1058.
6. Poss S. "An innovative tissue-retraction material," *Compendium of Continuing Education in Dentistry, supplement*, 2002; 23(1):13-19.
7. Pescatore C. "A predictable gingival retraction system," *Compendium of Continuing Education in Dentistry*, 2002; 23(1):7-18.
8. Mandikos MN. "Polyvinyl siloxane impression materials: an update on clinical use," *Australian Dental Journal*. 1998; 43(6):428-434.
9. International Standards Organization, "Dental elastomeric impression material. ISO, Section 5. 11 Detail reproduction," Stand Alone Document, American Dental Association Department of Standards Administration, Chicago, Ill, USA, 1992, 4823-1992
10. Chee WWL, TE Donovan. "Polyvinyl siloxane impression materials: a review of properties and techniques," *The Journal of Prosthetic Dentistry*. 1992; 68(5):728-732.
11. Panichuttra R, Jones RM, Goodacre C, Munoz CA, Moore BK. "Hydrophilic poly (vinyl siloxane) impression materials: dimensional accuracy, wettability, and effect on gypsum hardness," *The International Journal of Prosthodontics*. 1991; 4(3):240-248.