



ISSN Print: 2394-7489  
ISSN Online: 2394-7497  
IJADS 2018; 4(1): 131-135  
© 2018 IJADS  
www.oraljournal.com  
Received: 26-11-2017  
Accepted: 27-12-2017

**Avinash Tejasvi ML**  
Associate Professor, Department  
of Oral Medicine and Radiology,  
Kamineni Institute of Dental  
Sciences, Narketpally,  
Telangana, India

**Harsha Bhayya**  
Assistant Professor, Department  
of Oral Medicine and Radiology,  
Kamineni Institute of Dental  
Sciences, Telangana, India

**Correspondence**  
**Harsha Bhayya**  
Assistant Professor, Department  
of Oral Medicine and Radiology,  
Kamineni Institute of Dental  
Sciences, Telangana, India

## *Original Research*

# **Evaluation and comparison of various methods for assessing Multiple Taurodontism: A clinical study**

**Avinash Tejasvi ML and Harsha Bhayya**

### **Abstract**

Taurodontism is a morphologic feature of generally multi-rooted teeth with large pulp chambers and shortened roots. As it is a developmental disturbance of a tooth that lacks constriction at the level of the cement-enamel junction (CEJ). It is characterized by vertically elongated pulp chamber, apical displacement of the pulpal floor and bifurcation or trifurcations of the roots. Although permanent molar teeth are most commonly affected, this change can also be seen in both the permanent and deciduous dentition, unilaterally or bilaterally, and in any combination of teeth or quadrants. In the present case we have used Shifman and Chanannel method as well as Seow WK, Lai PY method of calculation to diagnose various types of taurodont teeth which is a unique feature of this report.

**Keywords:** Taurodontism, pulp chamber, dentition, tooth

### **Introduction**

The term "Taurodontism" was first introduced in 1908 and is defined as a morphologic change of generally multi-rooted teeth with large pulp chamber which its pulpal floor and furcation is apically displaced. This anomaly is the result of Hertwig's epithelial sheath inadequacy to invaginate at the proper horizontal level. Taurodontisms can be seen unilaterally or bilaterally, in any quadrants, and in both permanent and deciduous dentition<sup>[1]</sup>. Depending on the level of furcation, taurodontism has been divided into mild "hypotaurodontism, moderate "mesotaurodontism and severe "hypotaurodontism. In case of taurodontism radiographic evaluation plays a vital role in diagnosis and further treatment planning in cases required with endodontic treatment.

There are few reports of multiple taurodontism not related to syndromes, here we report such rare case of multiple taurodontism diagnosed with the aid of digital Orthopantomogram.

### **Case Report**

A female patient aged around 24 year came with a chief complaint of missing tooth in the lower anterior region was examined and sent for further treatment to prosthodontia and conservative dentistry for the prosthesis of missing teeth and restoration of decayed teeth. Patient was referred to department of oral radiology for Orthopantomogram for preoperative implant assessment. An Orthopantomogram (Fig-1) was made which revealed an edentulous area i.r.t teeth 31, 32, 41, 42 few decayed teeth in relation to 13, 14, 17, 24, 28, rotated teeth in relation to 22, missing teeth in relation to 24, impacted teeth in relation to 18, 48 and few restored teeth were present. Tooth in relation to 17, 16, 26, 27, 36, 37, 38, 46, and 48 showed developmental abnormality showing large pulp chambers, bifurcation of these teeth were pushed apically hence teeth had more apico occlusal height than the normal teeth and had lack of constriction at the level of CEJ. Distance from the bifurcation of the root to the CEJ is greater than the occluso-cervical distance was observed. Based on Shifman and Chanannel method and Seow WK, Lai PY method individual tooth were calculated for assesment of various types of taurodont teeth (Table-1 and Table 2).

The measurements made to diagnose taurodontism was based on Taurodontic index (TI) as (Fig 2) which was calculated as  $TI = \frac{X}{Y} \times 100$ . Degrees of taurodontism are categorized as: Hypotaurodontism: TI 20-30; Mesotaurodontism: TI 30-40; Hypertaurodontism: 40-75. With this mentioned calculations the results are tabulated in Table 1.

**Table 1:** Results achieved by Shifman and Channanel <sup>[2]</sup> index.

Tooth number	AB ( x ) In mm	AC ( y ) In mm	AB/AC ( x/y ) by shifman <i>et al.</i> , method	Taurodontic index (TI): AB/AC X 100	Diagnosis CB/R Kim soew <i>et al.</i> , Method
17	9.15	13.41	0.68 mm.	68 %	Hypertauodontism
16	11.34	13.25	0.85 mm	85%	Hypertauodontism
26	7.4	11.80	0.62 mm	62%	Hypertauodontism
27	8.03	11.32	0.70 mm	70%	Hypertauodontism
36	5.15	11.43	0.45 mm	45%	Hypertauodontism
37	4.18	9.97	0.41 mm	41%	Hypertauodontism
38	4.53	9.84	0.46 mm	46%	Hypertauodontism
46	4.06	12.25	0.33 mm	33%	Mesotauodontism
47	2.79	10.06	0.27 mm	27%	Hypotauodontism
48	6.10	10.57	0.57 mm	57%	Hypertauodontism

**Point A:** Lowest point at the occlusal end of the pulp chamber.

**Point B:** Highest point at the apical end of the chamber.

**Point C:** Apex of the root.

**X:** distance from A to B

**Y:** Distance from A to C

A tooth is considered as taurodont if X divided by Y is equal to or greater than 0.2mm.

**Table 2:** Results achieved by Seow WK, Lai PY <sup>[3]</sup> Index.

Tooth number	CB In mm	R In mm	CB/R by Kim soew <i>et al.</i> , Method	Diagnosis
17	28.70	5.16	4.32	Hypertauodontism
16	36.04	8.33	5.56	Hypertauodontism
26	31.00	8.30	3.73	Hypertauodontism
27	28.44	5.21	5.45	Hypertauodontism
36	24.21	9.55	2.53	Hypertauodontism
37	21.44	9.24	2.32	Hypertauodontism
38	23.46	5.91	3.96	Hypertauodontism
46	23.51	10.40	2.26	Hypertauodontism
47	21.85	8.59	2.56	Hypertauodontism
48	24.51	4.96	4.94	Hypertauodontism

The parts of each tooth comprising the crown, body, and root were identified using the following definitions: Crown (C) - from the deepest part occlusal surface to the cemento-enamel junction (CEJ); Body (B)-from the CEJ to the root furcation; Root (R) from the root furcation to the apices according to Shaw 1928.

A tooth is considered as taurodont if CB divided by R (Fig-3 and Fig-4) ratio ranges from 1.10 - 1.29 be classified as the Hypotauodont group, those in the range from 1.30 - 2.00 as the Mesotauodont group, and those > 2.00 as the Hypertauodont group. With this calculation the ratio achieved and diagnosis was made accordingly and is tabulated in Table-2.

## Discussion

Though a taurodont tooth is a morphologic abnormality, clinically cannot be differentiated from a normal tooth because its body and roots lie below the alveolar margin. Taurodont tooth can be identified only through routine radiographic examination. This developmental anomaly most of the time an isolated one, but it is also seen in association with several syndromes, familial inheritance, and genetic malformation and it has been reported in literature. The term 'taurodontism' was however first stated by Sir Arthur Keith in 1913. The origin of this term is from Greek "tauros" which means "Bull" and "odontos" which means "Tooth" <sup>[4]</sup>.

Taurodontism may affect primary or permanent dentition, although permanent is more prominent, and primarily affect the molar teeth and rarely premolars. Only few cases are reported, where multiple teeth are affected by taurodontism.

Theories concerning the etiology of taurodontism have been diverse and is commonly attributed to the failure of invagination of the epithelial root sheath sufficiently early to

form the Cynodont. This alteration in the Hertwig's epithelial root sheath involves failure of the epithelial diaphragm to form a bridge prior to dentin deposition resulting in large pulp chambers. It has been indicated that the anomaly typify a primitive pattern, a specialized or retrograde character, a mutation, an X-linked trait, an atavistic feature, an autosomal dominant trait or familial. Although it has been described that it can be associated with genetic defects, certain syndromes.

Pathogenesis revolves around several theories

- An unusual developmental pattern, a delay in the calcification of pulp chamber.
- An odontoblastic deficiency and an alteration in Hertwig's epithelial root sheath.
- Some believe that taurodontism is most likely the result of disrupted developmental homeostasis <sup>[5]</sup>.

How much displacement and/or morphologic change that constitutes taurodontism always leads difference of opinion. In literature there exists an objective analysis of cases presented, more preferred is subjective diagnosis. it is not only the size that matters in pulp chamber and roots, but also the position of the body of the tooth in relation to the alveolar margin. Various authors have proposed various categorization indices.

In 1928 Shaw classified this condition as hypotauodontism, mesotauodontism and hypertauodontism based on the relative displacement of the floor of the pulp chamber. This subjective, arbitrary classification led normal teeth to be misdiagnosed as taurodontism. In 1977, Feichfinger and Rossiwall stated that the distance from the bifurcation or trifurcation of the root to the cemento-enamel junction should be greater than the occluso-cervical distance for a taurodontic tooth. Shifman and Chanannel in 1978 proposed a new classification and is the widely used system till now. The

distance between the Lowest point at the occlusal end of the pulp chamber roof (A), to the highest point of the floor (B), divided by the distance from A to the root apex is 0.2mm or greater and distance from B to CEJ is greater than 2.5 mm [4]. In our presented case the calculations were done for individual molar teeth to evaluate the exact diagnosis which is presented in (Table 1 and Table 2). Both the methods revealed the similar values for assessing taurodontism, hence both the methods are validated for diagnosing taurodont tooth. Clinically, a Taurodont appears as a normal tooth because the body and roots of a Taurodont tooth are not clinically seen and they are present below the alveolar margin, so diagnosis of taurodontism is usually a subjective determination made from diagnostic radiographs. Involved teeth assume a rectangular shape rather than tapering towards the roots. The pulp chamber is extremely large with a greater apico-occlusal height than normal and lacks the usual constriction at the cervical region of the teeth with exceedingly short roots. The bifurcation or trifurcation may be only a few millimetres (mm) above the apices of the roots [6].

#### **Syndromes associated with taurodontism [5]**

Amelogenesis imperfecta, Down's syndrome, Aperts syndrome, Focal dermal hypoplasia or goltzgorlin syndrome, Ectodermal dysplasia, Hypophosphatasia, Hyperphosphatasia-oligophrenia - taurodontism, Microcephalic dwarfism - taurodontism Microdontia - taurodontia-dens invaginatus, Oculo-dento-digital dysplasia, Oral-facial-digital, Type II, Rapp-hodgkin syndrome, Dyskeratosis congenital, Klinefelter syndrome, Tricho-dento-osseous syndrome, Mohr syndrome, Wolf-hirschhorn syndrome, Lowe syndrome, Smith-magenis syndrome, Williams syndrome, Mccune-albright syndrome, Van der woude syndrome. Many of these disorders which are mentioned above will be having oral manifestations, with taurodontism as one of the feature which can be detected on dental radiographs as alterations in the morphology or chemical composition of the teeth.

#### **Differential diagnosis**

Metabolic conditions such as Pseudo hypoparathyroidism, hypophosphatasia, and hypophosphatemic vitamin D-resistant and dependent rickets, the pulp chamber may be enlarged but the teeth are of relatively normal form. Early stages of dentinogenesis imperfecta, where the appearance may resemble the large pulp chambers. Moreover, the developing

molars may appear similar to taurodonts; however, an identification of wide apical foramina and incompletely formed roots may also be considered [6].

#### **Clinical Considerations**

The clinical implications of taurodontism have potentially increased chance of pulp exposure due of decay and dental procedures. It may complicate prosthetic and/or orthodontic treatment planning. Taurodontism, although not very common have to be highlighted due to its influence on diverse dental treatments.

#### **Endodontic considerations**

An Endodontist's view, taurodontism presents a challenge during negotiation, instrumentation and obturation in root canal therapy. Because of the complexity of the root canal anatomy and proximity of buccal orifices, complete filling of the root canal system in taurodont teeth is challenging [7].

#### **Surgical considerations**

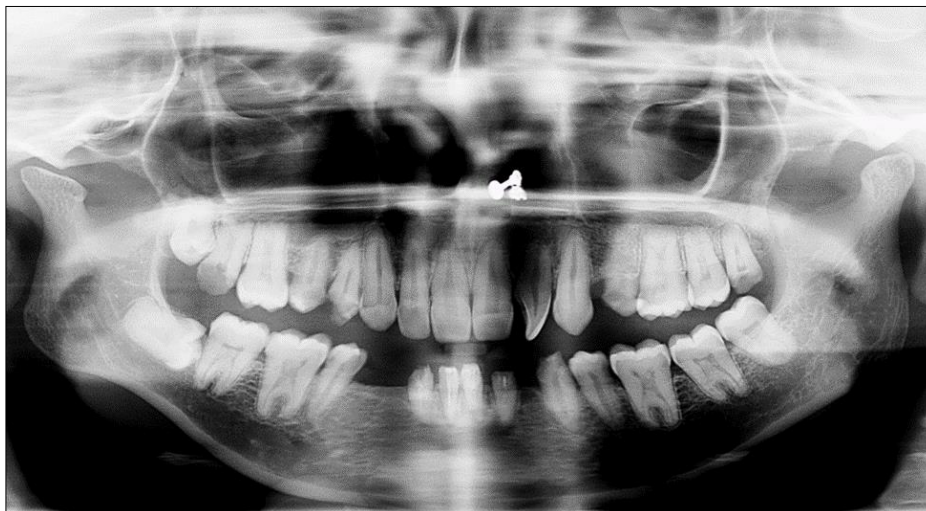The extraction of a taurodont tooth is usually complicated because furcation is shifted more to the apical third. It has also been reported in literature that the large body with little surface area of a taurodont tooth is embedded in the alveolus. This feature would make extraction less difficult as long as the roots are not widely divergent [8].

#### **Prosthetic considerations**

For the prosthetic treatment of a taurodont tooth, it has been recommended that post placement be avoided for tooth reconstruction. Because less surface area of the tooth is embedded in the alveolus, a taurodont tooth may not have as much stability as a Cynodont when used as an abutment for either prosthetic or orthodontic purposes. Lack of a cervical constriction would deprive the tooth of the buttressing effect against excessive loading of the crown [9].

#### **Periodontal considerations**

Taurodont teeth may, in specific cases, offer favorable prognosis. Where periodontal pocketing or gingival recession occurs, the chances of furcation involvement are considerably less than those in normal teeth because taurodont teeth have to demonstrate significant periodontal destruction before furcation involvement occurs [10].



**Fig 1:** OPG showing multiple taurodont teeth

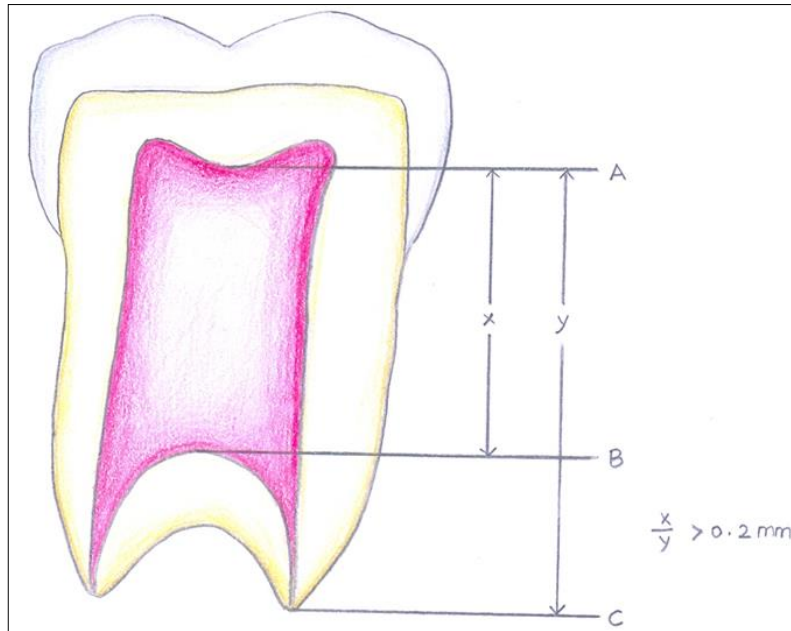


Fig 2: Measurements for taurodontic teeth by Shifman and Channanel method

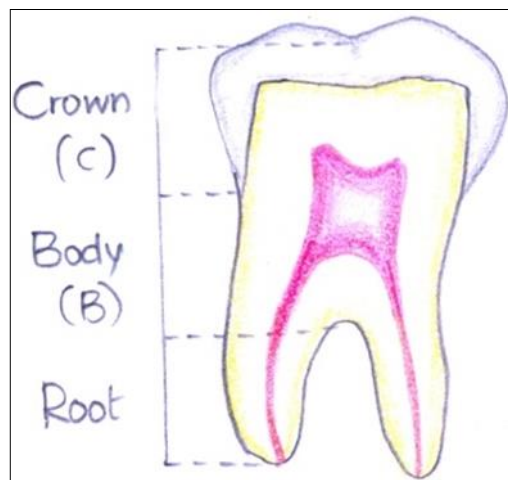


Fig 3: Measurements of crown body and root length measured in millimeters on a mandibular first permanent molar as shown by Seow and Lai.

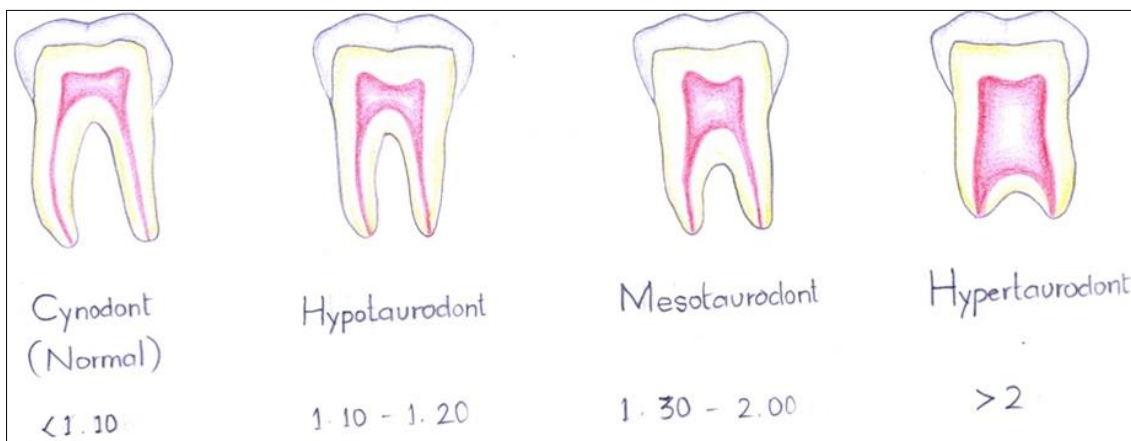

Fig 4: Diagrammatic representation of normal (cynodontic) tooth and three subtypes of taurodontic teeth as proposed by Shaw (1928).

**Conclusion**

Knowing about taurodontism is very important for a dentist not only in respect to clinical and radiographic features but also in regard to clinical implications and their management. Taurodontism also provides a valuable clue in detecting its association with many syndromes and other systemic conditions.

**References**

1. Gandhi M, Asthana G. Taurodontism an endodontic challenge: Three case reports. Endodontology, 2012; 24(1):136-142.
2. Shifman A, Chanannel I. Prevalence of taurodontism found in radiographic dental examination of 1,200 young

- adult Israeli patients. *Community Dent Oral Epidemiol.* 1978; 6:200-203.
3. Seow WK, Lai PY. Association of taurodontism with hypodontia: a controlled study. *Pediatr Dent.* 1989; 11:214-219.
  4. Manjunatha BS, Suresh Kumar Kovvuru. Taurodontism- A Review on its etiology, prevalence and clinical considerations. *J Clin Exp Dent.* 2010; 2(4):e187.
  5. Dineshshankar J, Sivakumar M, Balasubramaniam AM, Kesavan G, Karthikeyan M, Prasad VS. Taurodontism. *J Pharm Bio all Sci.* 2014; 6:S13-5.
  6. Jafarzadeh H, Azarpazhooh A, Mayhall JT. Taurodontism: a review of the condition and endodontic treatment challenges. *International Endodontic Journal.* 2008; 41:375-388.
  7. Tsesis I, Shifman A, Kaufman AY. Taurodontism: an endodontic challenge: report of a case. *J Endod.* 2003; 29:353-5.
  8. Bharti R, Chandra A, Tikku AP, Wadhvani KK. Taurodontism an endodontic challenge: a case report. *J Oral Sci.* 2009; 51:471-4.
  9. Durr DP, Campos CA, Ayers CS. Clinical significance of Taurodontism. *J Am Dent Assoc.* 1980; 100:378-81.
  10. Shifman A, Buchner A. Taurodontism. Report of sixteen cases in Israel. *Oral Surg Oral Med Oral Pathol.* 1976; 41:400-405.