



ISSN Print: 2394-7489
ISSN Online: 2394-7497
IJADS 2018; 4(2): 206-209
© 2018 IJADS
www.oraljournal.com
Received: 03-02-2018
Accepted: 04-03-2018

Jesús Israel Rodríguez-Pulido
Graduate Periodontics Program,
School of Dentistry, Universidad
Autónoma de Nuevo León,
Monterrey, Nuevo León, México

Delia Eunice Gutiérrez-Rivas
Graduate Periodontics Program,
School of Dentistry, Universidad
Autónoma de Nuevo León,
Monterrey, Nuevo León, México

Ana Cristina Chávez-Villegas
Graduate Periodontics Program,
School of Dentistry, Universidad
Autónoma de Nuevo León,
Monterrey, Nuevo León, México

Norma Idalia Rodríguez-Franco
Graduate Periodontics Program,
School of Dentistry, Universidad
Autónoma de Nuevo León,
Monterrey, Nuevo León, México

Gloria Martínez-Sandoval
Graduate Periodontics Program,
School of Dentistry, Universidad
Autónoma de Nuevo León,
Monterrey, Nuevo León, México

María Gabriela Chapa-Arizpe
Graduate Periodontics Program,
School of Dentistry, Universidad
Autónoma de Nuevo León,
Monterrey, Nuevo León, México

Correspondence

Jesús Israel Rodríguez-Pulido
Graduate Periodontics Program,
School of Dentistry, Universidad
Autónoma de Nuevo León,
Monterrey, Nuevo León, México

Clinical diagnosis and treatment of infrabony defects with enamel matrix derivative and autogenous bone graft: A case report

Jesús Israel Rodríguez-Pulido, Delia Eunice Gutiérrez-Rivas, Ana Cristina Chávez-Villegas, Norma Idalia Rodríguez-Franco, Gloria Martínez-Sandoval and María Gabriela Chapa-Arizpe

Abstract

Today alternatives have been sought for surgical periodontal treatment such as the use of bone grafts and enamel matrix derivative, which facilitates regeneration and periodontal healing including a gain in clinical attachment level and reduction of probing depth.

Case report: A 40-year-old female patient with moderate generalized chronic periodontitis, who was treated with debridement flaps in the four quadrants with enamel matrix derivative and autogenous bone graft, obtaining total remission of the periodontal pockets.

Conclusion: The use of enamel matrix derivative in combination with autogenous bone graft is effective to treat containing bone defects. The success of the treatment consists of constant maintenance and periodontal evaluation every three months to avoid recurrence.

Keywords: Periodontitis, enamel matrix derivative, autograft

1. Introduction

Periodontal disease is an inflammatory disease caused by dentobacterial plaque, which is present in 11% of the global adult population [1], being the second most common oral disease in Mexico with a prevalence of 78% among people of ≥ 60 years [2].

One of the main causes of periodontitis is the accumulation of dentobacterial plaque, where the periodontopathogenic bacteria frequently associated are *P. gingivalis*, *T. forsythia* and *T. Dentícola*³. The infectious process results in the presence of gingival inflammation, bleeding on probing, bone loss, dental mobility, loss of clinical attachment level (CAL) and the presence of intra-osseous defects according to the degree of severity [4].

The objective of the periodontal treatment consists of the elimination of microorganisms, where it has been demonstrated that it can be successfully treated by means of surgical and non-surgical periodontal treatment. Both treatment modalities seek the mechanical elimination of the causal factor of periodontal disease [5].

Today alternatives have been sought for surgical periodontal treatment, such as the use of different bone graft materials and enamel matrix derivative (EMD) [6-8], where it has been demonstrated that the application of this matrix substantially facilitates regeneration and periodontal healing, including a gain of CAL and the reduction of probing depth for more than 20 years [9].

The EMD is a porcine extract, composed of amelogenins, stimulating cellular proliferation of the periodontal ligament [10], as well as containing propylene glycol alginate, as an alloplastic material for the restoration of periodontal defects [11, 12].

The objective of the present study is to report a clinical case of a female patient of 40 years, diagnosed with moderate generalized chronic periodontitis, which was treated by surgical treatment with the use of EMD and autogenous bone graft.

2. Case Report

A 40-year-old female patient, who attended at the Graduate Periodontics Program, School of Dentistry, Universidad Autónoma de Nuevo León, Monterrey, Nuevo León, México.

In the clinical history the patient refers to not present any medical condition or be under any medical treatment, so it was classified as ASA I.

In dental history the patient presents amalgam and resin fillings in the posterior segment, in addition to mentioning a previous orthodontic treatment fifteen years ago, with a duration of four years. At the intraoral physical examination the patient presents dentobacterial plaque and calculus, gingival inflammation, generalized probing depth of 5-7 mm and loss of CAL, bleeding on probing, also presents pathological migration of the upper lateral incisors and physiological pigmentation in the keratinized gingiva of both arcades.

In the radiographic analysis moderate horizontal and vertical bone loss were found in the posterior segment of both arches and advanced located in 1.2 and 2.2. Due to the clinical and radiographic findings, it was diagnosed as moderate generalized chronic periodontitis and mucogingival deformities around teeth: Miller class III gingival recession in 1.6 and class IV in 1.2 and 2.2 [13].

After the diagnosis, the hygienic phase was carried out, which consisted of a scaling and root planning, and instruction of oral physiotherapy with soft bristle brush and dental floss.

Subsequently, the patient was re-evaluated four weeks later, where loss of CAL and periodontal pockets >6 mm were found in the upper arch and in the posterior segment of the lower arch, due to the presence of periodontal defects. Periodontal flaps were indicated with EMD (Emdogain, Straumann®) and autogenous bone graft.

The flaps were made by intrasulcular incisions and reflected to full thickness, later it was debrided and carried out scaling and root planing, to later condition the roots adjacent to the intraosseous defects with EDTA for two minutes, rinsed with serum and placed EMD, subsequently, vertical mattress sutures were placed with Vicryl 4-0 in I and III quadrants and black silk 4-0 in II and IV quadrants. The flap was performed from the distal line angle of 1.8 to the mesial line angle of 1.1, where osteoplasty was performed with bone collection and EMD placement and autograft (Fig. 1), in quadrant II was performed distal line angle from 2.8 to mesial line angle of 2.1, performing osteoplasty and emdogain placement (Fig. 2), the quadrant III was performed from distal line angle 3.8 to mesial line angle of 3.5 using the curtain technique with EMD (Fig. 3), and in quadrant IV of the distal line angle of 4.8 to mesial line angle of 4.5, eliminating enamel projections, later osteoplasty with bone collection was performed and was placed with EMD in the bony defects (Fig. 4).

2.1 Postoperative indications

Were prescribed 500 mg of amoxicillin every 8 hours for 7 days and ibuprofen of 400 mg every 6 hours for 5 days. Sutures were removed seven days later and after three months the Roth Slot 0.022" orthodontic appliance was placed in order to align and level the teeth and intrude the 1.2 and 2.2.

Maintenance was performed every three months, and due to the healing provided by the EMD it was reevaluated at nine months, where CAL gain and good control of dentobacterial plaque was found (Fig. 4).

3. Discussion

Losada *et al*, demonstrated that the use of the EMD with and without bone graft in non-containment defects provides a significant gain of CAL, a reduction in probing depth and a reduction in the infrabony components in both cases treated [14]. The use of the EMD in combination with a lyophilized alloplastic material, resulted in bone gain radiographically. The narrow angular defects and depth of the infraosseous component have a significantly positive correlation to radiographic bone gain as well as grade II furcation defects [15-17].

Studies with different results have been reported during the application of EMD, where Pilloni *et al*, have evaluated the regeneration potential of the EMD together with the application of nanohydroxyapatite in periodontal defects where they were found after a follow-up of 24 months a reduction on probing depth and without showing CAL loss [11], however Raghianti *et al*, reported that after 24 months of follow-up of a debridement flap associated with the EMD, showed significant loss of the bone crest alveolar (1.01 mm) and there was no significant reduction of the bone defect (0.04 mm) [12].

Currently there is controversy about the time of reevaluation after surgical treatment with autograft and EMD, however one study has reported that stable periodontal parameters can be found for its evaluation six months after surgery, although they suggest a longer evaluation interval to assess its clinical efficacy [18].

3.1 Figures

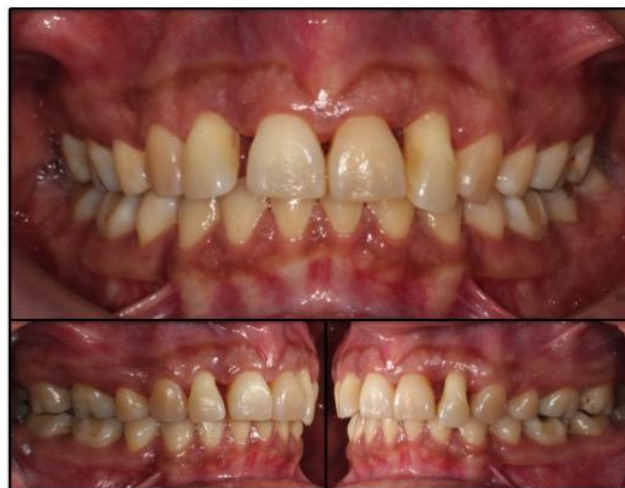

Fig 1: Initial Clinical Photographs.

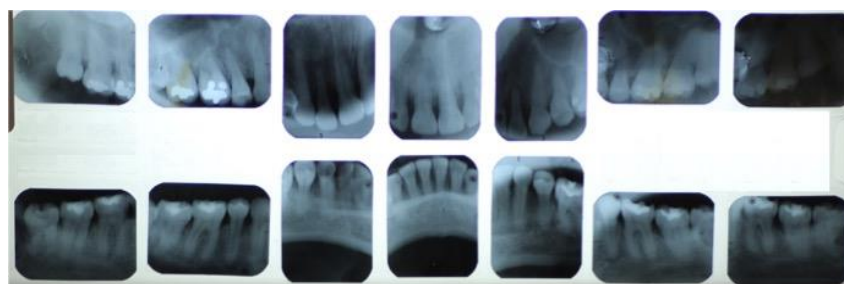


Fig 2: Periapical radiographs.

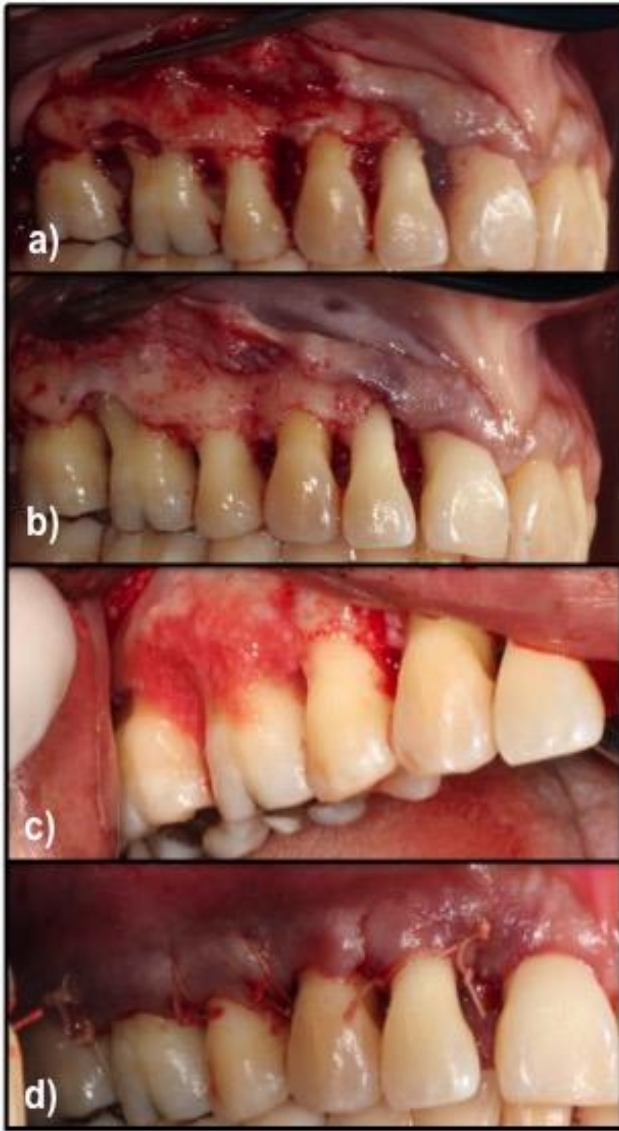


Fig 3: Quadrant I Debridement flap. a) Flap elevation, b) Debridement, c) Emdogain and autograft, d) Suture with external vertical mattress.

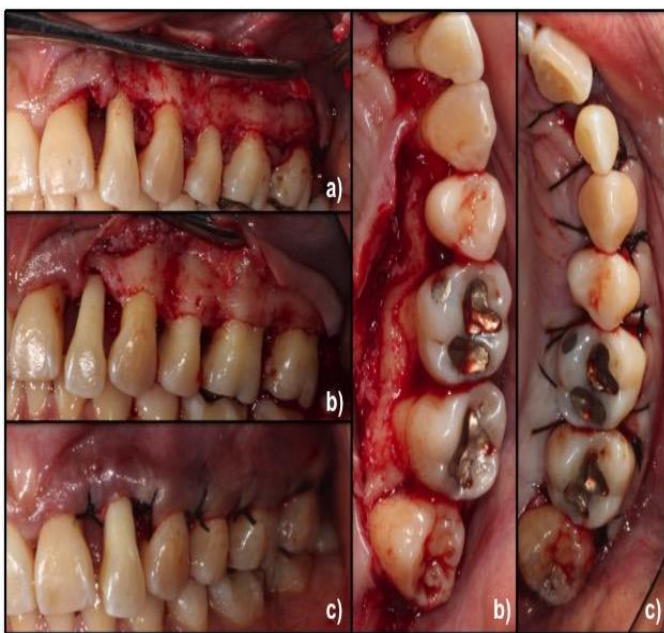

Fig 4: Quadrant II Debridation flap. a) Flap elevation, b) Debridement, c) Suture with external vertical mattresses.

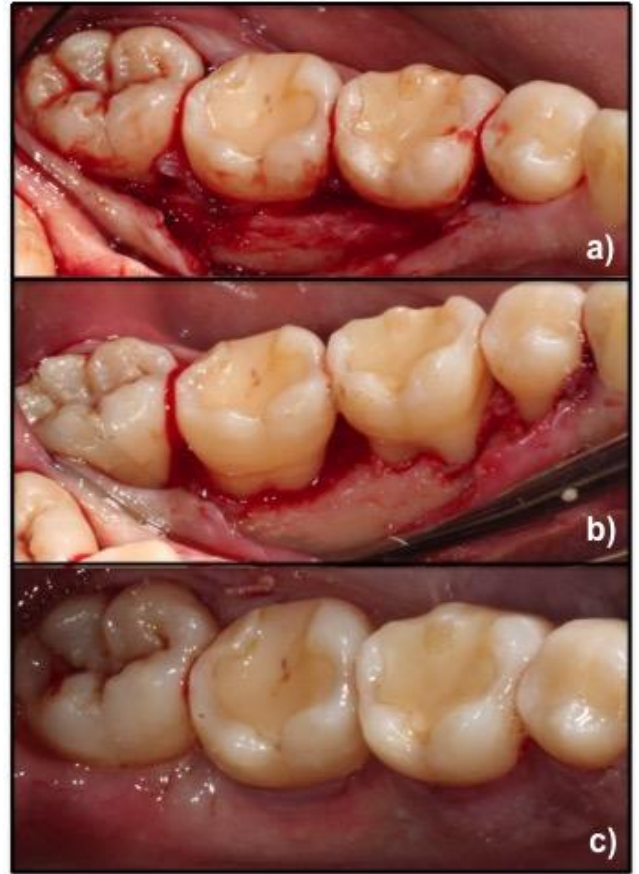


Fig 5: Quadrant III Debridment Flap with curtain technique. a) Flap elevation b) Debridement, c) Suture with external horizontal mattresses.

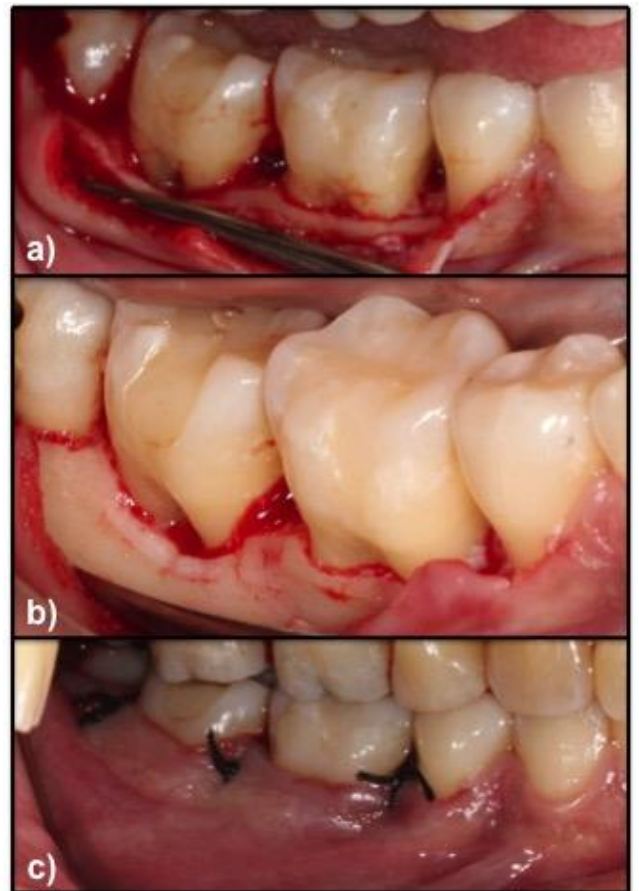


Fig 6: Quadrant IV Debridment Flap. a) Flap Elevation, b) Debridement, Osteoplasty and elimination of the enamel projections, c) Suture with internal vertical mattresses.

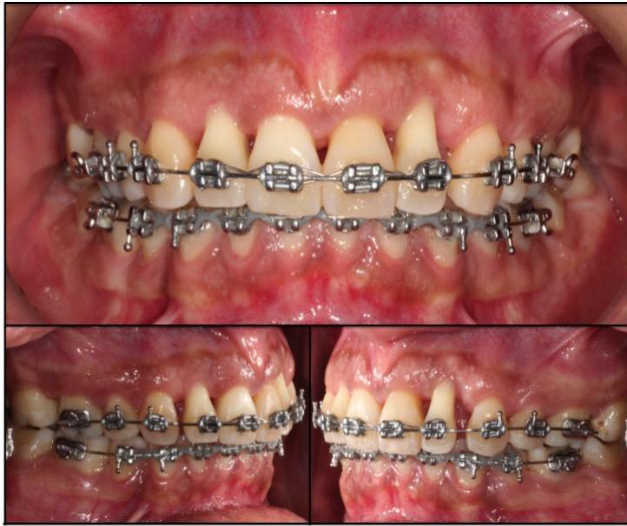

Fig 7: Clinical photographs after nine months of surgical treatment.

4. Conclusions

The treatment of infrabony defects with enamel matrix derivative and autogenous bone graft, CAL gain was obtained, and the elimination of the periodontal pockets with stable clinical parameters at nine months after the surgical treatment.

Acknowledgments

Acknowledgments to CONACYT for the scholarship granted.

References

1. Eke PI, Wei L, Borgnakke WS, Thornton-Evans G, Zhang X, Lu H *et al.* Periodontitis prevalence in adults ≥ 65 years of age, in the USA. *Periodontol 2000.* 2016; 2(1):76-95.
2. Fernández-Plata R, Olmedo-Torres D, Martínez-Briseño D, González-Cruz H, Casa-Medina G, García-Sancho C. Días de estancia hospitalaria (DEH) en pacientes con enfermedades respiratorias (ER) y enfermedad periodontal (EP). *Gac Med Mex.* 2017; 153:31-35.
3. Dentino A, Lee S, Mailhot J, Hefti AF. Principles of periodontology. *Periodontol 2000.* 2013; 61(1):16-53.
4. Matarasso M, Iorio-Siciliano V, Blasi A, Ramaglia L, Salvi GE, Sculean A. Enamel matrix derivative and bone grafts for periodontal regeneration of intrabony defects. A systematic review and meta-analysis. *Clin Oral Investig.* 2015; 19(7):1581-1593.
5. Monegro LMM, Pulido JIR. Ozonoterapia como adyuvante en el tratamiento periodontal no quirúrgico. Revisión de la bibliografía. *Rev Mex Periodontol.* 2015; 6(3):136-142.
6. Yilmaz S, Cakar G, Yildirim B, Sculean A. Healing of two and three wall intrabony periodontal defects following treatment with an enamel matrix derivative combined with autogenous bone. *J Clin Periodontol.* 2010; 37(6):544-550.
7. Hoffmann T, Al-Machot E, Meyle J, Jervøe-Storm PM, Jepsen S. Three-year results following regenerative periodontal surgery of advanced intrabony defects with enamel matrix derivative alone or combined with a synthetic bone graft. *Clin Oral Investig.* 2016; 20(2):357-364.
8. Yamamoto S, Masuda H, Shibukawa Y, Yamada S. Combination of bovine-derived xenografts and enamel matrix derivative in the treatment of intrabony

- periodontal defects in dogs. *Int J Periodontics Restorative Dent.* 2007; 27(5):471-479.
9. Miron RJ, Sculean A, Cochran DL, Froum S, Zucchelli G, Nemcovsky C *et al.* Twenty years of enamel matrix derivative: the past, the present and the future. *J Clin Periodontol.* 2016; 43(8):668-683.
10. Miron RJ, Bosshardt DD, Buser D, Zhang Y, Tugulu S, Gemperli A *et al.* Comparison of the capacity of enamel matrix derivative gel and enamel matrix derivative in liquid formulation to adsorb to bone grafting materials. *J Periodontol.* 2015; 86(4):578-587.
11. Pilloni A, Saccucci M, Di Carlo G, Zeza B, Ambrosca M, Paolantonio M *et al.* Clinical evaluation of the regenerative potential of EMD and NanoHA in periodontal infrabony defects: A 2-year follow-up. *BioMed Res Int.* 2014; (1):1-9.
12. Ragghianti Zangrando MS, Chambrone D, Pasin IM, Conde MC, Pannuti CM, de Lima LAPA. Two-year randomized clinical trial of enamel matrix derivative treated infrabony defects: radiographic analysis. *BMC Oral Health.* 2014; 14:1-8.
13. Armitage GC. Development of a Classification System for Periodontal Diseases and Conditions. *Ann Periodontol.* 1999; 4(1):1-6.
14. Losada M, González R, García ÀP, Santos A, Nart J. Treatment of Non-Contained Infrabony Defects With Enamel Matrix Derivative Alone or in Combination With Biphasic Calcium Phosphate Bone Graft: A 12-Month Randomized Controlled Clinical Trial. *J Periodontol.* 2017; 88(5):426-435.
15. Tartakovsky Y, Goldstein A, Goldstein M. Radiographic outcomes following treatment of intrabony defects by freeze-dried bone allograft combined with enamel matrix derivative: A retrospective study. *Quintessence Int.* 2015; 46(9):773-780.
16. Queiroz LA, Santamaria M, Casati M, Silverio K, Nociti-Junior F, Sallum E. Enamel matrix protein derivative plus synthetic bone substitute for the treatment of mandibular Class II furcation defects: a case series. *Quintessence Int.* 2015; 46(3):199-205.
17. Ogihara S, Tarnow DP. Efficacy of enamel matrix derivative with freeze-dried bone allograft or demineralized freeze-dried bone allograft in intrabony defects: a randomized trial. *J Periodontol.* 2014; 85(10):1351-1360.
18. Trombelli L, Annunziata M, Belardo S, Farina R, Scabbia A, Guida L. Autogenous bone graft in conjunction with enamel matrix derivative in the treatment of deep periodontal intra-osseous defects: a report of 13 consecutively treated patients. *J Clin Periodontol.* 2006; 33(1):69-75.