



International Journal of Applied Dental Sciences

ISSN Print: 2394-7489
ISSN Online: 2394-7497
IJADS 2018; 4(2): 299-304
© 2018 IJADS
www.oraljournal.com
Received: 17-02-2018
Accepted: 18-03-2018

Dr. Vedant Patel
PG Student, Darshan Dental
College & Hospital, Loyara,
Udaipur, Rajasthan, India

Dr. Meenakshi Khandelwal
Professor, Darshan Dental
College & Hospital, Loyara,
Udaipur, Rajasthan, India

Dr. Vikas Punia
Reader, Darshan Dental College
& Hospital, Loyara, Udaipur,
Rajasthan, India

Dr. Vivek Sharma
Professor, Darshan Dental
College & Hospital, Loyara,
Udaipur, Rajasthan, India

Dr. Saransh Malot
Senior lecturer, Darshan Dental
College & Hospital, Loyara,
Udaipur, Rajasthan, India

Dr. Anand Porwal
Senior lecturer, Darshan Dental
College & Hospital, Loyara,
Udaipur, Rajasthan, India

Correspondence

Dr. Vedant Patel
PG Student, Darshan Dental
College & Hospital, Loyara,
Udaipur, Rajasthan, India

Single implant supported fixed prosthesis in anterior zone: A review

Dr. Vedant Patel, Dr. Meenakshi Khandelwal, Dr. Vikas Punia, Dr. Vivek Sharma, Dr. Saransh Malot and Dr. Anand Porwal

Abstract

The goal of modern dentistry is to restore the patient to normal contour, function, comfort, esthetics, speech, and health, whether restoring a single tooth with caries or replacing several teeth. A treatment option to replace a single missing tooth is a single-tooth implant. The replacement of a single tooth in the anterior region is challenging because of the highly specific soft and hard tissue criteria, in addition to all other esthetic, phonetic, functional, and occlusal requirements. Since 1993, single-tooth implant survival has demonstrated that this procedure is the most predictable method of tooth replacement. 100% survival rates of single tooth implants has been reported. Anterior single-tooth replacement is often a challenge, regardless of the experience and skill of the dentist. This review article comprehensively summarizes the therapeutic situation “single-tooth restoration in the esthetic region” and provides the clinician with relevant information and state-of-the-art knowledge on both surgical and prosthetic procedures.

Keywords: Implant, single tooth implant, implant supported fixed prosthesis, anterior implant

1. Introduction

The goal of modern dentistry is to restore the patient to normal contour, function, comfort, esthetics, speech, and health, whether restoring a single tooth with caries or replacing several teeth. What makes implant dentistry unique is the ability to achieve this ideal goal regardless of the atrophy, disease, or injury of the stomatognathic system^[1]. A treatment option to replace a single missing tooth is a single-tooth implant^[2].

Since 1993, single-tooth implant survival has demonstrated that this procedure is the most predictable method of tooth replacement. 100% survival rates of single tooth implants has been reported in the previous studies^[3,4]. A series of reports in 1991, 1994, and 1996 by Laney and colleagues reported a cumulative survival rate of 97.2% at 3 and 5 year^[5-8]. In 1997, Gomez-Roman *et al.*^[9] reported a 96% overall survival rate. The median of these reports is a 2.8% implant loss with a mode of 5 years. In comparison, a fixed partial denture failure rate may be as high as 20% within 3 years, and 50% survival at 10 years is expected. As important, no reports indicate a loss of an adjacent tooth, which is a considerable advantage^[2].

Advantages of this modality over a fixed partial restoration include the decreased risk of caries on the abutment teeth, the improved ability to clean the proximal surfaces of the adjacent teeth, improved esthetics of the adjacent teeth, the maintenance of bone in the edentulous site, the psychological advantage (especially with congenitally missing teeth or the loss of a tooth after a crown restoration), and the decreased risk of abutment tooth loss from endodontic failure or caries^[2].

Although implant success rates are high in the maxillary region high patient expectations, high esthetic requirements, and sensitive soft and hard tissue management compound the complexity of the anterior teeth restoration. Implants to replace an anterior single tooth remain one of the more difficult treatments to perform in implant dentistry. The soft tissue drape is often the most difficult aspect of treatment. As a consequence, anterior single-tooth replacement is often a challenge, regardless of the experience and skill of the dentist^[2].

Hence, this article comprehensively addresses the therapeutic situation “single-tooth restoration in the esthetic region” and provides the clinician with relevant information and state-of-the-art knowledge on both surgical and prosthetic procedures.

2. Indications

- Poor abutment teeth support
- Inadequate hard or soft tissue (or both) in esthetic regions (pontic contour)
- Patient will not allow preparation of adjacent teeth (patient desire)
- Young patients with large pulp horns in clinical crowns
- Anodontia ^[2]

3. Contraindications

- Lack of available bone height with poor prognosis or impossibility to augment
- Inadequate bone volume.
- Inadequate intra-tooth space.
- Observable mobility of the adjacent teeth.
- The time required for treatment, and psychologic fear of surgery ^[2]

4. Pre-treatment evaluation

The limiting factors that may influence the treatment plan for maxillary anterior single-tooth replacement should be included in the presurgery preprosthetic evaluation ^[2].

4.1 Esthetics Evaluation

The implant is often 5 mm or less in diameter and round in crosssection. A natural maxillary anterior crown cervix region is 4.5 to 7 mm in mesiodistal cross-section and is never completely round. In fact, the natural central incisor and canine teeth are often larger in their faciopalatal dimension at the cemento-enamel junction (CEJ) than in the mesiodistal dimension ^[10].

The bone is lost first in the faciopalatal width, so the greater width of implants in this dimension to copy a tooth root would require even more augmentation than presently advocated. As a result, a smaller-diameter, round implant is suggested, and the cervical esthetics of a single implant crown must accommodate a round-diameter implant and balance hygiene and aesthetic parameters. Additional prosthetic steps and components with varied emergence profiles or customized tooth colored abutments are often required to render the illusion of a crown on a natural abutment ^[10]. To ideally restore an esthetic maxillary anterior tooth, the implant should be positioned in three dimensions within the prosthetic contour requirements of the final restoration. Hence, the ideal implant body position is first identified ^[10].

4.2 Crown Height Space

The interocclusal space should be assessed carefully. Patients with Angle's Class II Division II skeletal patterns, an inadequate maxilla-mandibular relationship, or a severe deficiency in the vertical dimension are poor candidates for dental implants without prior corrections. An implant abutment is usually too short for proper retention of the crown. This may mean orthognathic surgery, orthodontic therapy, or both is required before any tooth replacement ^[2].

4.3 Bone Height

The available bone should be closely evaluated because it will greatly influence the soft tissue drape, implant size, implant position (angulation and depth), and ultimately the final esthetic outcome. The model midcrestal position of the edentulous site should be 2 mm below the facial CEJ of the adjacent teeth. On occasion, the bone crest may be above this position when the interproximal bone height is higher and/or a

bone graft was performed at extraction. Often the osseous crest may be more apical than ideal, in both the implant site and the adjacent tooth roots. Under these conditions, ideal crown contour, soft tissue emergence, and interproximal tissue conditions are less likely ^[2].

4.4 Mesiodistal Space

An adequate mesiodistal space is necessary for an esthetic outcome of an implant restoration and the interproximal soft tissue of the adjacent teeth. A traditional two-piece implant should be at least 1.5mm from an adjacent tooth. When the implant is closer than this to an adjacent tooth, any bone loss related to the microgap, the biological width, and/or stress might cause the implant and adjacent tooth to lose bone. This may compromise interproximal esthetics and/or sulcular health of the implant and natural tooth ^[10].

4.5 Faciopalatal Width

The bone width loss is primarily from the facial region, because the labial plate is very thin compared with the palatal plate, and facial undercuts are often found over the roots of the teeth. A bone graft is often necessary to restore the proper anatomy of the ridge and to avoid a compromised implant position more palatal and apical ^[10].

The amount of available bone width (faciopalatal) should be at least 2.0 mm greater than the implant diameter at implant insertion. Therefore a 3.5mm implant requires at least 5.5mm of bone width. It should be emphasized the implant diameter measurement is at the crest module of the implant. Most 3.75-mm diameter implant bodies are 4.1 mm at the crest module. In these situations, the mesiodistal limitation is 7.1 mm and the faciolingual width limitation is 6.1 mm ^[10].

4.6 Soft Tissue Drape

The position and architecture of the interdental papillae are noted before developing the implant treatment plan. The soft tissue in the region of the edentulous site should ideally have the same color and form as the adjacent teeth. When a tooth is lost, the thin interseptal bone disappears and the bone remodels in a sloping fashion from the palatal to the more apical facial bony plate. As a result, the interdental papillae are often depressed compared with their level between healthy adjacent teeth. The papilla height is also affected as a result of the lack of interproximal contact with the missing tooth.² Several authors have proposed additional parameters for predictable papillae that may guide the practitioner in the choice of the most appropriate modality ^[11, 12]. They are as follows-

4.6.1 Height of the Lip Line

Ideally the height of the maxillary lip should rest at the junction of the free gingival margin on the facial aspect of the maxillary centrals and canine teeth ^[13, 14]. Thus the interdental papillae are visible, but little gingival display is seen over the clinical crowns. Almost 70% of patients have this ideal smile position. The higher the high lip line is, the more ideal the esthetic requirements are for the remaining teeth and for the single-tooth replacement ^[10].

4.6.2 Gingival Biotype in the Treatment Area

The biotype of the gingiva is usually called *thick* or *thin*. Thicker tissue is more resistant to the shrinkage or recession and more often leads to the formation of a periodontal pocket after bone loss. Thin gingival tissues around the teeth are more prone to shrinkage after tooth extraction and are more

difficult to elevate or augment after tooth loss. Gingival recession is the most common esthetic complication of thin biotypes after anterior single-tooth extraction and is also a concern after implant surgery, uncovering, or both [10].

4.7 Shape of the Missing and Adjacent Teeth

The shape of the missing and adjacent teeth can profoundly influence the degree of risk associated with implant-supported restorations in the esthetic zone. With the esthetic outcome strongly influenced by the final gingival architecture, the risk can be reduced by the presence of square teeth (and, often, a thick-gingiva biotype). Triangular tooth shapes often have a tissue architecture of the thin, high-scalloping type when associated with teeth in good periodontal health. A high esthetic risk is evident when a triangular tooth shape is associated with localized periodontal defects and the loss of interproximal papillae. These patients will often require a dental implant superstructure that is square-shaped, as well as large contact areas, potentially compromising the final appearance. When the restoration includes triangular tooth shapes, interproximal spaces (black triangles) must be anticipated [15].

4.8 Implant Crest Module Design

The crest module of an implant body should be designed to transmit some compression and tensile forces to the crestal bone. Smooth metal on the crest module increases the crestal bone loss of the biological width (once the implant is uncovered) and transmits shear forces to the bone. Both these conditions increase the risk of crestal bone loss around the implant. The crestal bone loss may cause shrinkage of the soft tissue drape and compromise esthetics. Therefore smooth metal collars on the implant crest module should be limited to approximately 0.5 mm [2].

4.9 Implant Size

The first factor that influences the size of an implant is the mesiodistal dimension of the missing tooth. However, the implant body should obviously not be as wide as the natural tooth or clinical crown. Otherwise, the emergence contour and interdental papillae region cannot be properly established [2].

The second factor that determines the mesiodistal ideal implant diameter is the necessary distance from an adjacent tooth root. The horizontal dimension of a wedge-shaped bone defect around an implant from the biological width, implant design, or occlusal overload at the crest of the ridge is approximately 1.4 mm. When the implant is closer than 1.5 mm to an adjacent root, the wedge-shaped vertical defect may become a horizontal defect, causing bone loss on the adjacent tooth root [10].

The ideal width of the single-tooth implant should ideally correspond to the width of the missing natural tooth, 2 mm below the CEJ. The next dimension that determines the width of an anterior implant is the faciopalatal dimension of bone. The ideal width of bone would allow at least 1.5 mm on the facial aspect of the implant so that if a vertical defect forms around the crest module.² The faciopalatal width of bone at the crest for an anterior implant should have at least 1.5 mm on the facial, plus the dimension of the implant at the crest module, plus 1 mm on the palatal [2].

4.10 Examination of the Occlusion

This can be usually be accomplished by simple clinical examination. The adjacent tooth contacts (and that of the pre-existing prosthetic replacement if available) should be

examined in centric occlusion, retruded contact, and protrusive and lateral excursions. Occlusal contacts on the single tooth implant restoration should be designed such that contacts occur first on adjacent teeth. Difficulties can arise when replacing canines in a canine-guided occlusion. Under these circumstances, attempts should be made to achieve group function and light contacts on the implant restoration. Similar precautions are required with central and lateral incisor replacements in class 2 division 2 incisor relationships with deep overbites [16].

4.11 Bone Mapping

Ideally, implants should be surrounded by at least 1 mm of bone. In the anterior maxilla, accurate assessment of bone dimensions is complicated by irregular resorption patterns and thickness of the overlying mucosa [17].

The bone-mapping technique involves a series of measurements with a specially designed caliper (Fig. 1). The sharp points of the caliper penetrate the anesthetized mucosa until the surface of the bone is reached. A millimeter scale near the handle end of the caliper will give an accurate reading of ridge thickness. A stent made of clear acrylic or thermoplastic sheet with holes in the edentulous site at 2-3 mm intervals can be used to guide and transfer the markings on the cast [18].

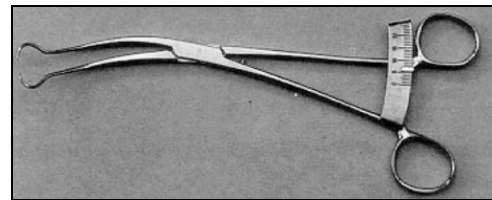


Fig 1: A- Bone Caliper

4.12 Evaluation by Imaging

It can be surprisingly difficult to obtain accurate radiographic mesio-distal measurements of spaces at sites in the arch such as the maxillary lateral incisors/canines and the mandibular canine. This is due to the curvature of the arch and the difficulty of achieving parallel film alignment with the space. The clinical measures can be checked against the radiographic ones to obtain a more accurate estimate. (Fig. 2) [16]

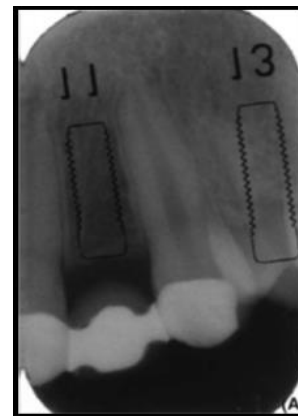


Fig 2: An intraoral radiograph of a maxillary lateral incisor space with an overlay showing an 11-mm-long _ 3.5-mm-diameter implant allowing an assessment of distance between the implant surface and adjacent tooth root.

Sectional Tomography although some clinicians routinely use CT scans for single tooth planning, we would consider this to be in excess of what is normally required. CT scans, however,

may be very important aids with some areas such as the maxillary central incisors where the presence of the incisive canal may compromise implant placement. To optimize the information provided by 3D radiographic techniques, it is helpful to provide information about the planned final restoration. A suitable existing partial denture or a customized stent that mimics the desired tooth setup is constructed and radiographic markers incorporated. The radiopaque marker can be placed in the cingulum area of the tooth if a screw-

retained crown is planned to indicate the access hole for the screw ^[16].

5. Surgical phase for implant placement

5.1 Different Surgical Techniques

There are three approaches for single-tooth implant surgery:

- Two-stage surgery
- One-stage surgery
- Direct, one-stage surgery

Table 1: Comparison between Two- Stage, One-Stage, and Direct One- Stage Surgeries

Topic	Two Stage	One Stage	Direct One Stage
Bone anatomy visual control	Yes	Yes	No
Osteotomy visual control	Yes	Yes	No
Cover screw/PME	Below tissue	Above tissue	Above tissue
Bone graft	Yes	Maybe	No
Exposure to intraoral bacteria	No	Yes	Yes
Surgical appointments	2	1	1
Prosthetic connection	At or below tissue	At or above tissue	Above tissue
Implant platform level	More difficult	Easier	Easier
Reposition Keratinized facially	Yes	Yes	No
Transitional appliance	Yes	Yes-No	Yes-No
Stage II needed	Yes	No	No

6. Interim restorations for the osseointegration period

These procedures will often require a healing phase before the seating of provisional restorations on dental implants. A well-designed interim restoration will not only provide esthetic relief for the patient, but will help protect the tissue as it matures during the healing phase ^[19].

6.1 Options for ideal interim restorations

- Fixed partial denture
- Resin fiber-reinforced fixed partial denture
- Vacuform retainer
- Removable partial denture (RPD)

7. Stage ii surgery and soft tissue emergence contours

When the implant-bone interface is acceptable, the exposure of the implant body should be accomplished with the soft tissue final architecture in mind. The ideal goal of the soft tissue drape in a two-stage surgical approach after the implant insertion is for the soft tissue to be at the height of the desired interdental papillae. These soft tissue procedures may be classified as.

7.1 Subtractive Technique

When the soft tissue along the edentulous crest is at the level of the desired interdental papillae and is of sufficient quality and volume, a subtraction technique (e.g., gingivoplasty with a coarse diamond) sculpts the crestal gingival tissues to reproduce the cervical emergence contour of the crown, complete with interdental papillae and proper labial gingival contour. (Fig. 3) ^[2]

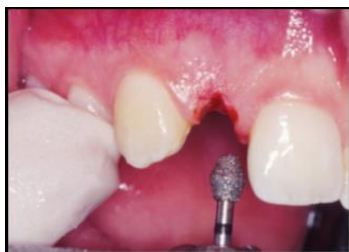

Fig 3: A coarse diamond sculpts the soft tissue drape of the implant crown

7.2 Addition Technique

If the gingival contour at stage II uncover is insufficient for the proper architecture for the interdental papillae, then an additive surgery is performed to gain tissue thickness and height. Several addition techniques have been proposed ^[21-24]. For example, an incision is made on the palatal aspect of the ridge, from the palatal line angle of each adjacent tooth. The tissue is elevated from the crest of the ridge, and the first-stage cover screw is identified. After removal, a low-profile healing cap of 3 mm is inserted ^[2].

A removable transitional prosthesis is recontoured to fit over the healing cap for the next few weeks until patient is seen for first prosthetic appointment. The soft tissue heals to the contour of the healing abutment or permucosal device. The patient is referred to restoring dentist for fabrication of the final crown after 6 to 8 weeks of tissue maturation ^[2].

8. Prosthetic phase

8.1 Abutment Selection

As a result of the specific anatomical limitations of the single-tooth implant, the prosthetic abutment not only must be designed with antirotational features (which requires a two-piece system) but also may need to be angled to compensate for implant body insertions that are not within the contours of the final restoration ^[10].

Abutment Options-

8.1.1 Prefabricated Abutments

a). Narrow-Diameter Abutments

Advantages is that one size of abutment may be used for almost all patients. The abutment is seated on the implant platform and engages the hexagon without circumferential hard or soft tissue interference, which is beneficial because the abutment-to implant connection may be several millimeters below the tissue ^[10].

b). Wider-Diameter Abutments

An abutment with a 1- to 2-mm “flare” positioned 1 to 2 mm above the implant platform presents several advantages. The wider cervical region improves the emergence profile of the soft tissue starting 1 to 2 mm above the bone. The wider

abutment also provides a greater surface area for retention and provides a greater premade taper of the abutment [10].

c). Premade Anatomic Abutment.

It seems logical to have an abutment copy a natural tooth crown preparation. The added advantage is that because anterior teeth are wider faciolingually than mesiodistally, the abutment can reflect the natural tooth cross-section [10].

d). Ceramic Abutments

The ceramic premade abutments are usually white in colour. Ceramic premade abutments have become popular to prevent metal below the crown margin from causing a grayish hue to be seen through the cervical tissues when there is a thin biotype [10].

e). Angled Abutments

Their use should be limited to situations in which a facial or angled implant position precludes restoration without correction of the angulation [10].

8.1.2 Customized Abutments

A trend toward laboratory-customized anatomical or aesthetic abutments has emerged. The primary advantage of the custom abutment is that the abutment is fabricated for each specific patient condition. The subgingival crown margin position and contours can be extended only where necessary. Another major advantage of the customized abutment is that the abutment may be fabricated with crown and bridge precious metal, so the facial region may be covered with porcelain [10].

8.1.3 Abutments for Screw-Retained Crowns

For single tooth, the main advantage is simplicity and ease of insertion and removal. Problems can arise when cementing crowns, particularly if deep margins are used. With a screw-retained approach, the porcelain can be taken further subgingivally with minimal risks. Usually screw-retained crowns are more applicable to premolar and molar regions where occlusal screw access may be less of an aesthetic problem and in situations where there may be more of a need to remove restorations [18].

9. Maintenance phase

9.1 Criteria for Implant Success

- An individual, unattached implant is immobile when tested clinically.
- A radiograph does not demonstrate any evidence of periimplant radiolucency.
- Vertical bone loss is less than 0.2 mm annually after the first year of service of the implant.
- In the context of the foregoing, a success rate of 85% at the end of a 5-year observation period and 80% at the end of a 10-year period are minimum criteria for success [2].

9.2 Ideal Clinical Conditions of Teeth

- Absence of pain
- Less than 0.1 mm initial horizontal mobility under lateral forces less than 100 g
- Less than 0.15 mm secondary mobility with lateral forces of 500 g
- Absence of observed vertical mobility
- Periodontal probing depths less than 2.5 mm
- Radiographic crestal bone height 1.5 to 2.0 mm below the cemento-enamel junction

- No bleeding on probing
- No exudate
- Absence of gingival recession [2].

10. Conclusion

A missing single tooth is a common scenario in restorative dentistry. The replacement of a single tooth in the anterior region is challenging because of the highly specific soft and hard tissue criteria, in addition to all other esthetic, phonetic, functional, and occlusal requirements. When the intra-tooth is adequate and bone is present or can be created, the implant restoration is the treatment of choice. Today, with the improvements in implant materials, design, surgical approach, and prosthetic guidelines and with reported success rates greater than 97%, the use of implants to replace a single tooth is often the treatment of choice. Unique surgical and prosthetic concepts are implemented for proper results.

11. References

1. Tatum OH. The Omni implant system, Birmingham. Ala Alabama Implant Congress, 1988.
2. Misch CE. Contemporary implant dentistry. 3rd edition. St. Louis: Mosby Elsevier, 2007.
3. Schmitt A1, Zarb GA. The longitudinal clinical effectiveness of osseointegrated dental implants for single-tooth replacement. *Int J Prosthodont.* 1993; 6(2):197-202.
4. Misch CE, D'Alessio R, Misch-Dietsh F. Maxillary partial anodontia and implant dentistry-maxillary anterior partial anodontia in 255 adolescent patients: a 15 year retrospective study of 276 implant site replacements. *Oral Health.* 2005; 95(4):45-57.
5. Jemt T, Laney WR, Harris D, Henry PJ, Krough PHJ, Polizzi G *et al.* Osseointegrated implants for single tooth replacement, a 1-year report from a multicenter prospective study. *Int J Oral Maxillofac Implants.* 1991; 6(1):29-36.
6. Laney WR, Jemt T, Harris D, Henry PJ, Krough PHJ, Polizzi G *et al.* Osseointegrated implants for single tooth replacement: progress report from a multicenter prospective study after 3 years. *Int J Oral Maxillofac Implant.* 1994; 9(1):49-54.
7. Laney WR, Jemt T, Harris D, Henry PJ, Krough PHJ, Polizzi G *et al.* Osseointegrated implants for single tooth replacement: a prospective 5-year multicenter study. *Int J Oral Maxillofac Implants.* 1996; 11(4):450-455.
8. Malevez C, Hermans M, Daelemans P. Marginal bone levels at Brånemark system implants used for single tooth restoration. The influence of implant design and anatomical region. *Clin Oral Implants Res.* 1996; 7(2):162-169.
9. Gomez-Roman G, Schulte W, d'Hoedt B, Axman-Krcmar D. The Frialit- 2 Implant System: 5-year clinical experience in single tooth and immediately post extraction applications. *Int J Oral Maxillofac Implants.* 1997; 12(3):209-309.
10. Misch CE. Dental implant prosthetics 2nd edition. St. Louis: Mosby Elsevier, 2015.
11. Kois JC. Predictable single tooth peri-implant esthetics-five diagnostic keys. *Compend Contin Educ Dent.* 2001; 22(3):199-218.
12. Salama H, Salama M, Garber D, Adar P. Techniques for developing optimal peri-implant papillae within the esthetic zone: guided soft tissue augmentation. *J Esthet Dent.* 1995; 7(4):125-129.

13. Tjan AH, Miller GD, The JG. Some esthetic factors in a smile. *J Prosthet Dent.* 1984; 51(1):24-28.
14. Kokich V. Esthetics and anterior tooth position: an orthodontic perspective. Part I-Crown length. *J Esthet Dent.* 1993; 5(5):19-23.
15. Belser U, Martin W, Jung R, Hammerle C, Schmid B, Morton D *et al.* ITI Treatment Guide Implant Therapy in the Esthetic Zone Single-Tooth Replacements Volume 1. USA. Quientessence, 2007.
16. Palmer RM, Howe LC, Palmer PJ. *Implants in Clinical Dentistry* 2nd Edition. London: Informa Healthcare, 2012.
17. Wilson DJ. Ridge Mapping for Determination of Alveolar Ridge Width. *Int J Oral Maxillofac Implants.* 1989; 4(1):41-43.
18. Allen F, Smith DG. An assessment of the accuracy of ridge-mapping in planning implant therapy for the anterior maxilla. *David G. Smith Clin Oral Impl Res.* 2000; 11(1):34-38.
19. Garg AK. *Implant Dentistry A practical approach* 2nd edition. Missouri: Mosby Elsevier, 2010.
20. Belser U, Martin W, Jung R, Hammerle C, Schmid B, Morton D *et al.* ITI Treatment Guide Implant Therapy in the Esthetic Zone Single-Tooth Replacements Volume 1. USA. Quientessence, 2007.
21. Salama H, Salama M, Garber D, Adar P. The interproximal height of bone: a guidepost to predictable aesthetic strategies and soft tissue contours in anterior tooth replacement. *Pract Periodontics Aesthet Dent.* 1998; 10(9):1131-1141.
22. Becker W, Becker B. Flap designs for minimization of recession adjacent to maxillary anterior sites, a clinical study. *Int J Oral Maxillofac Implants.* 1996; 11(1):46-54.
23. Misch CE, Al-Shammari KF, Wang HI. Creation of interimplant papillae through a split-finger technique. *Implant Dent.* 2004; 13(1):20-27.