



International Journal of Applied Dental Sciences

ISSN Print: 2394-7489
ISSN Online: 2394-7497
IJADS 2018; 4(3): 01-04
© 2018 IJADS
www.oraljournal.com
Received: 01-05-2018
Accepted: 05-06-2018

Dr. Aesha Akhtar

Post Graduate Student,
Department of Conservative
Dentistry and Endodontics,
Dayananda Sagar College of
Dental Sciences, Kumaraswamy
layout, Bangalore, Karnataka,
India

Dr. Neeharika Godla

Post Graduate Student,
Department of Conservative
Dentistry and Endodontics,
Dayananda Sagar College of
Dental Sciences, Kumaraswamy
layout, Bangalore, Karnataka,
India

Dr. Vedavathi B

Associate Professor, Department
of Conservative Dentistry and
Endodontics, Dayananda Sagar
College of Dental Sciences,
Kumaraswamy layout,
Bangalore, Karnataka, India

Dr. Roopa R Nadig

Professor and Head, Department
of Conservative Dentistry and
Endodontics, Dayananda Sagar
College of Dental Sciences,
Kumaraswamy layout,
Bangalore, Karnataka, India

Correspondence

Dr. Aesha Akhtar

Post Graduate Student,
Department of Conservative
Dentistry and Endodontics,
Dayananda Sagar College of
Dental Sciences, Kumaraswamy
layout, Bangalore, Karnataka,
India

Custom cast posts - A diminishing reality? - A case report

Dr. Aesha Akhtar, Dr. Neeharika Godla, Dr. Vedavathi B and Dr. Roopa R Nadig

Abstract

The successful treatment of teeth with substantial damage to the tooth structure not only depends on good endodontic treatment, but also on prompt post endodontic restoration of the tooth after the completion of the same. The primary purpose of the post is to retain a core that holds the definitive prosthesis. A post and core also helps to improve the fracture resistance following RCT when the remaining tooth structure is very less. Keeping in mind, the wide array of post systems available, it is critical to decide the type of post endodontic restoration according to the clinical situation. When a large amount of tooth structure is lost or if an insufficient ferrule is present, a custom cast post and core is indicated. The following case reports depict the restoration of carious anterior teeth after using custom cast posts followed by PFM crowns.

Keywords: custom cast post, ferrule, anterior teeth, post endodontic restoration, PFM crowns

Introduction

Grossly decayed endodontically treated tooth with less coronal tooth structure remaining either due to a large pre-existing restoration or an extensive access cavity preparation often poses a challenge while choosing an appropriate post-endodontic restorative material [1]. Clinicians always face the dilemma whether to go for a direct/indirect restoration, partial/full coverage crown, also whether to opt for a post or not. There is again a confusion whether to select custom cast/ prefabricated post. According to Franklin Weine, most of the Endodontically treated teeth often failed following root canal treatment owing to poor post endodontic restoration rather than primary endodontic cause [2].

Remaining coronal tooth structure following RCT, functional requirements of the tooth, esthetics, age of the patient and the existing periodontal condition have to be kept in mind while choosing an appropriate post endodontic restorative material [3].

Endodontically treated anterior teeth with minimal to moderate loss of tooth structure without any discoloration can be restored with composite resin which provides an effective coronal seal and reduces the fracture susceptibility of tooth [4,5].

Teeth with intact cingulum/incisal edge and one or two small proximal lesions can be restored with composite resin [6]. If the root canal treated tooth is discolored, non-vital tooth bleaching followed by direct or indirect veneers is preferred.

In cases of endodontically treated teeth with moderate loss of tooth structure (<50%), the dilemma is whether to opt for direct composite or full coverage restoration, depending on occlusal loading condition and location of tooth. Endodontically treated teeth with crack lines, high occlusal loading, mesial and distal caries or cervical abrasion, definitely require intra-radicular posts for better retention of core and also to improve the fracture resistance of the tooth [7].

Anterior teeth with more than 50% tooth structure loss, post and core followed by full coverage restoration is mandatory [8].

A wide variety of post systems are available ranging from traditional cast metal posts to newer fiber posts. The ease of use, less time consumption for fiber posts along with the available laboratory and clinical evidence validates the utilization of fiber posts as an alternative to metal posts. It doesn't mean custom cast posts have lost their relevance in today's clinical practice. They are still a better option in cases where change in the angulation of the core is

required and where there is more tooth structure loss. This case report show cases restoration of carious maxillary incisors by custom cast post followed by porcelain fused to metal restorations.

Case Report

A 43 years old male patient presented to the department of Conservative Dentistry and Endodontics with the chief complaint of decayed upper front teeth and wanted to get them filled. Patient gave a history of pain in the upper front teeth one year ago which gradually subsided on taking medication.

Intra Oral Examination revealed multiple decayed, restored, missing teeth, labially proclined upper left front tooth, healthy gingiva, Canine Guided occlusion was present without loss of vertical dimension with adequate overjet and overbite. Radiograph revealed deep dentinal caries with increase in the width of PDL space in relation to 12, 21, 22 with negative response to EPT and cold test. Our goal was to treat pulpal and periapical infection, restore the involved teeth to their proper form, function and esthetics (Figures 1 – 5).

Based on the location of decay, palatal access was done in relation to 21, 22 and labial access opening was done in relation to 12 to conserve the sound tooth structure which provides for fracture resistance of the tooth. Biomechanical preparation was done using hand files in a step back technique and intracanal medicament of calcium hydroxide was placed in relation to 12, 21, 22 for 1 week. Obturation was completed using gutta percha by lateral compaction technique (Figure 6). Owing to the amount of tooth structure lost and presence of non-uniform ferrule, crown lengthening (Figure 7) was done and custom cast posts (Figure 8) and PFM crowns (Figure 9) were planned for these teeth. Direct composite restoration was done in relation to 11(Figure 8). Establishment of patient's esthetics and function was hence achieved (Figure 10, 11)

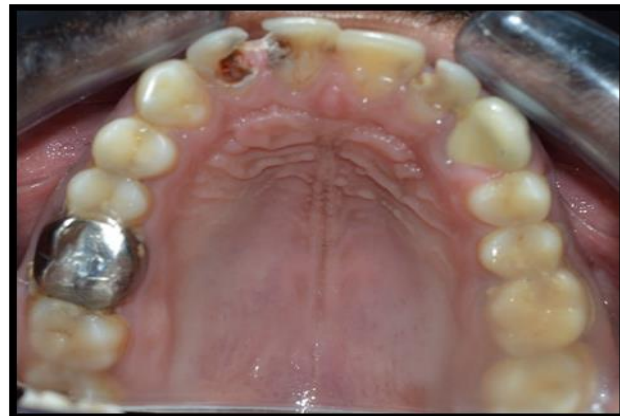

Fig 3

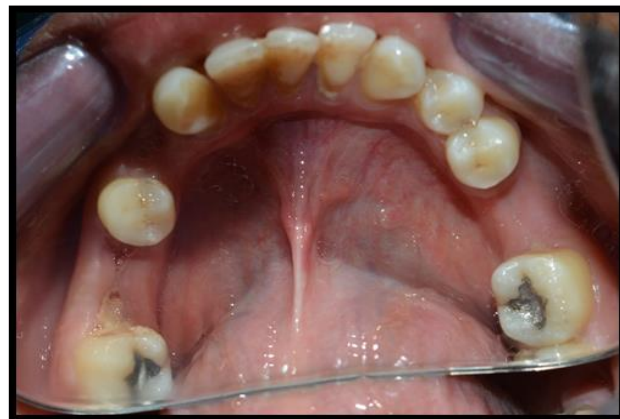

Fig 4

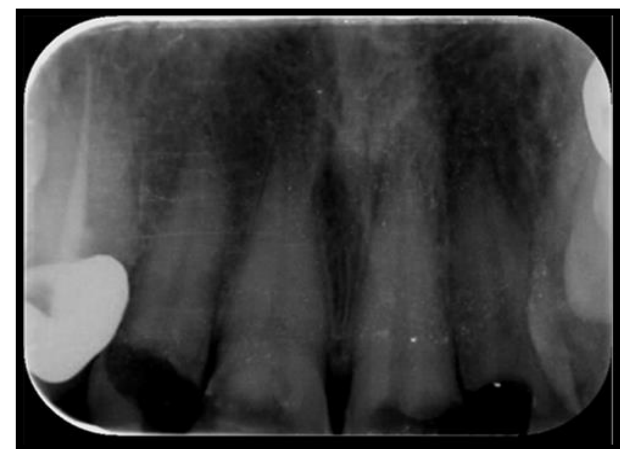


Fig 5

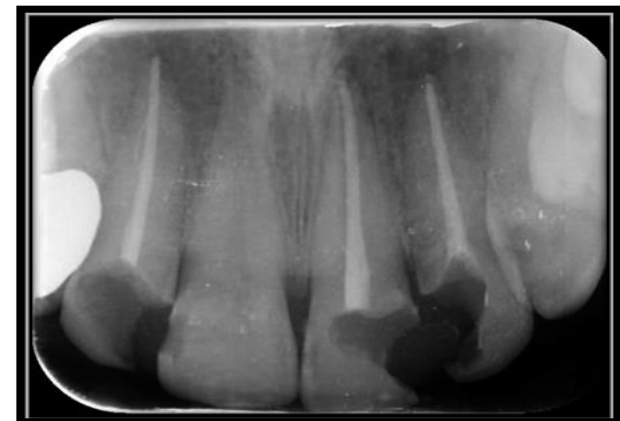

Fig 6

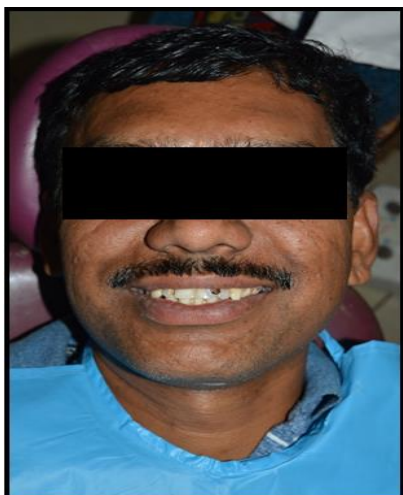

Fig 1

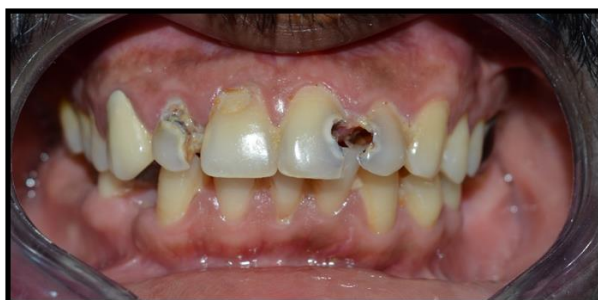

Fig 2

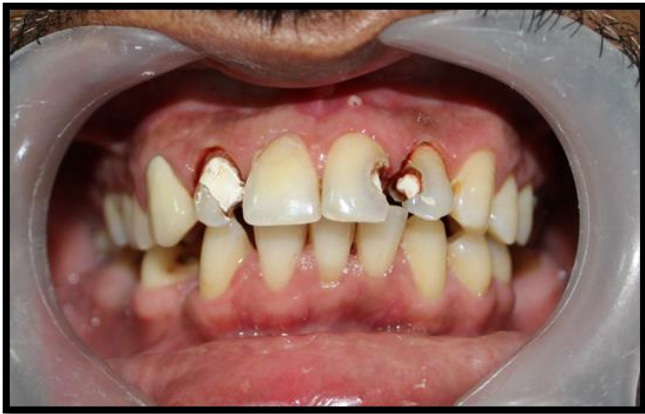

Fig 7




Fig 11

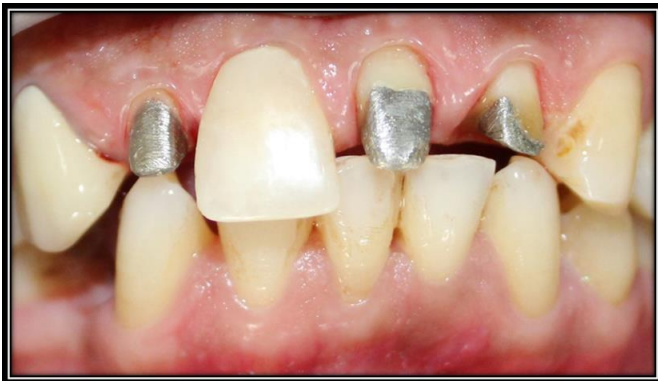

Fig 8: Cast Posts Cemented Following Endodontic therapy

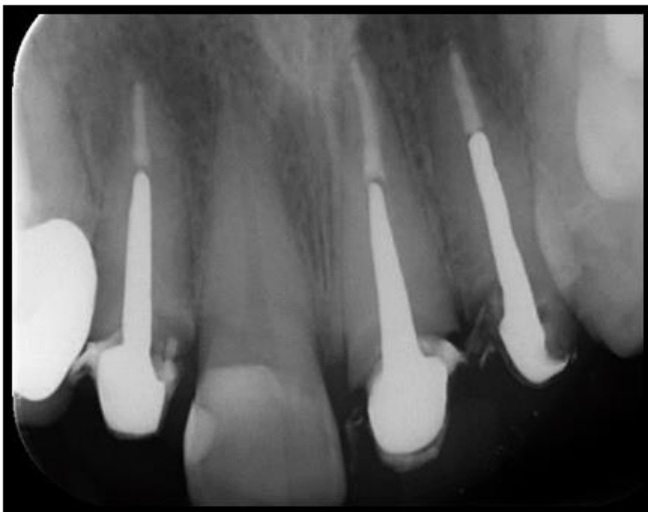

Fig 9

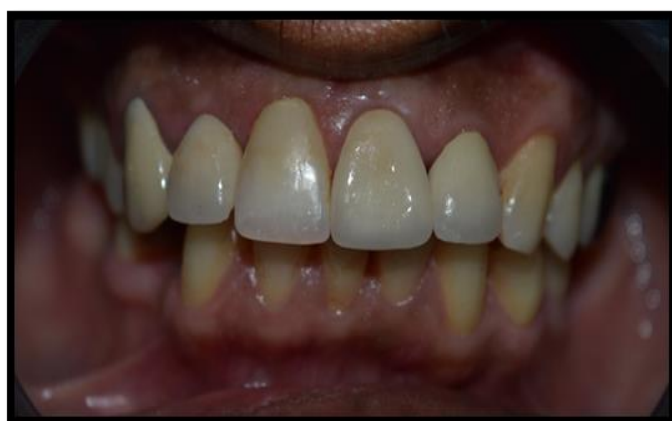

Fig 10

Discussion

A good post endodontic restoration along with good endodontic treatment often results in healing of periapical inflammation in 91.4% of the teeth, whereas poor restorations and poor endodontic treatment resulted in the absence of periradicular inflammation by only 18.1%. Furthermore, poor endodontic treatment followed by good permanent restoration resulted in 67.6% success rate. This clearly showed that success of endodontically treated teeth depended significantly more on the post endodontic restoration rather than quality of endodontic treatment as suggested by Trope and Ray^[9].

Keeping in mind, the wide array of post systems available in the market and the shift in clinical practice from traditional custom cast posts to prefabricated posts, it is necessary to weigh the advantages and disadvantages of both during treatment planning.

Cast posts conform to the canal morphology and can be used in all types of canal configurations- oval or elliptical. A slight change in core angulation can be done using cast posts and hence they can be used for correcting proclined teeth unlike other prefabricated posts^[10]. Also, according to Gomez Polo *et al*, cast metal posts have shown higher survival rates over 10 years^[11].

According to Santos-Filho PC *et al*, a 2mm ferrule increased the fracture resistance of the endodontically treated incisors, irrespective of crown, core or post type. This may be attributed to an improved stress distribution to the root.^[12]

According to a systematic review by Rafael Sarkis Onofre *et al*, posts with high modulus of elasticity performed better^[13].

In the absence of a ferrule, cast posts with higher modulus of elasticity are preferred, since the amount of tooth structure available for bonding is less and there are no long-term studies on fiberposts to prove the same^[14]. Fracture resistance of restored teeth and the mode of failure are the result of interaction between multiple mechanical properties and not just the material of the post. However, in certain clinical situations such as in teeth that lack cervical stiffness or in tooth with extensive destruction, with no ferrule or unable to obtain ferrule- cast posts are preferred.

Ferrule is the circumferential ring of tooth structure that is enveloped by the cervical portion of the crown. It provides a bracing action to improve the integrity of root canal treated tooth. It allows the crown and root to function as an integrated

unit and transmits the occlusal forces to the periodontium physiologically [15]. It has also been shown that a 2mm ferrule in teeth restored with metal crowns reduced the level of stress concentration in dentin for different metal and non-metal post systems [16]. Thus, stiffness of the post and core materials did not appear to significantly influence the strain values and fracture resistance as long as sufficient dentin remained. Also, according to Santos Filho PC *et al*, it has been reported that the presence of a 2mm crown ferrule surrounding remaining tooth structure enhanced fracture resistance of anterior teeth which were restored with a cast post and core and metal ceramic crowns [12].

In this case, as 12, 21, 22 presented with less peri-cervical tooth structure, cast posts were opted for post endodontic restoration followed by full coverage restoration. Having a good palatal ferrule is as effective as having a complete `continuous 360 degree ferrule` in maxillary incisors, as non-axial load from the palatal side from mandibular incisor challenges the post core /root junction. Hence a labial access was planned in relation to 12 as against the palatal to retain sufficient palatal tooth structure.

In cases of insufficient ferrule, crown lengthening or periodontal surgery (Gingivectomy/alveolectomy) or orthodontic extrusion with or without periodontal surgery can be undertaken to obtain sufficient ferrule [17, 18]. In this case, crown lengthening by 1mm was done in relation to both the lateral incisors to obtain more tooth structure.

The choice of crowns in this case would be either an all ceramic crown with a zirconia coping to mask the discolouration or a porcelain fused to metal crown. Keeping the patient's affordability in mind, PFM crowns were chosen as the final restoration.

Conclusion

Selection of suitable post and core system is challenging and should be guided by knowledge of their indications, advantages and disadvantages, as well as the amount and quality of remaining tooth structure and aesthetic requirements. The use of cast metallic posts and cores are recommended to restore severe loss of coronal tooth structure with insufficient ferrule and to retain metal-ceramic crowns. Establishment of esthetics and function for the patient has been achieved in this case using cast metal posts and metal ceramic crowns for rehabilitation of anterior teeth.

References

- Burke FJ. Tooth fracture *In vivo* and *in vitro*. J Dent. 1992; 20:131-9
- Franklin S. Weine endodontic therapy. (6th ed.):553-61.
- Naumann N, Kiessling S, Seemann R. Treatment concepts for restoration of endodontically treated teeth: A nationwide survey of dentists in Germany. J Prosthet Dent. 2006; 96:332-338.
- Heydecke G, Butz F, Strub JR. Fracture strength and survival of endodontically treated maxillary incisors with approximal cavities after restoration with different post and core systems: an *in-vitro* study. J Dent. 2001; 29:427-433.
- Pontius O, Hutter JW. Survival rate and fracture strength of incisors restored with different post and core systems and endodontically treated incisors without coronoradicular reinforcement. J Endod. 2002; 28:710-715.
- Khirtika SG, *et al*. J Pharm. Sci. & Res. 2017; 9(11):2123-2126.
- Balkenhol M, Wostmann B, Rein C, Ferger P. Survival time of cast post and cores: a 10-year retrospective study. J Dent. 2007; 35:50-58.
- Cheung W. A review of the management of endodontically treated teeth: post, core and the final restoration. Journal of the American Dental Association. 2005; 136(5):611-619.
- Ray HA, Trope M. Periapical status of endodontically treated teeth in relation to the technical quality of the root filling and the coronal restoration, International Endodontic Journal. 1995; 28(1):12-18.
- Bada NZ. Contemporary Restoration of Endodontically Treated Teeth Quintessence Publishing, Hanover Park, Ill, 2013.
- Gómez-Polo M, Llidó B, Rivero A, Del Río J, Celemín. A 10-year retrospective study of the survival rate of teeth restored with metal prefabricated posts versus cast metal posts and cores. J Dent, 2010.
- Paulo Cesar Freitas Santos-Filho. Influence of Ferrule, Post System, and Length on Biomechanical Behavior of Endodontically Treated Anterior Teeth JOE, 2014; 40(1).
- Sarkis-Onofre, Fergusson, Cenci, Moher. Pereira-Cenci Performance of Post-retained Single Crowns: A Systematic Review of Related Risk Factors. J Endod, 2017.
- Da Silva NR *et al*. The effect of post, core, crown type, and ferrule presence on the biomechanical behavior of endodontically treated bovine anterior teeth. The Journal of Prosthetic Dentistry. 2010; 104(5):306-17
- Jotkowitz A, Samet N. Rethinking ferrule--a new approach to an old dilemma. Br Dent J. 2010; 209:25-33
- Barkhordar RA, Radke R, Abbasi J. Effect of metal collars on resistance of endodontically treated teeth to root fracture. J Prosthet Dent. 1989; 61:676-678
- Ramya Nethravathy, Santhana Krishnan Vinoth, Ashwin Varghese Thomas. Three different surgical techniques of Crown lengthening: A comparative study. J Pharm Bioallied Sci. 2013; 5(1):S14-S16
- Luis Antonio Felipe, Sylvio Monteiro Jr, Luis Clovis Cardoso Vieira, Elioto Araujo. Re-establishing biologic width with forced eruption. Quintessence Int. 2003; 34(10):