



ISSN Print: 2394-7489
ISSN Online: 2394-7497
IJADS 2018; 4(3): 72-76
© 2018 IJADS
www.oraljournal.com
Received: 12-05-2018
Accepted: 13-06-2018

Shivali S Gaekwad
Junior Resident, Department of
Dentistry, Mysore Medical
College and Research Institute,
Mysore, Karnataka, India

Gauresh Kumar Patel
Assistant Professor,
Department of Periodontology,
Chitwan Medical College and
Teaching Hospital, Bharatpur,
Nepal

Sheela Kumar Gujjari
Professor and Head,
Department of Periodontology,
JSS Dental College and Hospital,
JSSAHER, SS Nagar, Mysore,
India

Pramod Kumar TM
Professor and Head,
Department of Pharmaceutics,
JSSAHER JSS College of
Pharmacy, Mysore, Karnataka,
India

Correspondence
Shivali S Gaekwad
Junior Resident, Department of
Dentistry, Mysore Medical
College and Research Institute,
Mysore, Karnataka, India

Evaluation of alkaline phosphatase levels in class ii furcation defects treated with simvastatin collagen graft

Shivali S Gaekwad, Gauresh Kumar Patel, Sheela Kumar Gujjari and Pramod Kumar TM

Abstract

Background: The predictable management of furcation defects has remained a perpetual problem. Simvastatin a lipid lowering drug has anti resorptive and anabolic effects on bone on local application. Simvastatin on local application also stimulates Alkaline Phosphatase expression. Thus Alkaline Phosphatase in Gingival crevicular fluid was assessed as a biomarker in class II furcation defects treated with Simvastatin collagen graft.

Materials and methods: 40 bilateral mandibular class II furcation defects in 20 systemically healthy subjects were randomized as test and control sites using split mouth design. Simvastatin collagen graft was placed in the test sites and collagen graft was placed in the control sites. Alkaline phosphatase level in gingival Crevicular fluid was estimated at baseline, 7 and 14 days post operatively. Horizontal probing depth at furcation site and radiographic assessment of bone fill was made using standardized intraoral periapical radiographs with at baseline, 6, 9, 12 and 15 months. The results were analyzed statistically.

Results: A statistically significant ($p < 0.05$) increase in Alkaline phosphatase levels was observed in test sites in comparison to control sites. A decrease in horizontal probing depth both groups over 15 months. The percentage bone area between the test and control over 15 months showed statistically significant differences.

Conclusion: Simvastatin collagen graft and collagen graft both showed improvements in clinical parameters and evidence of bone formation. The results encourage the adjunctive use of Simvastatin collagen graft for predictable regeneration of grade II furcation defects. Alkaline phosphatase levels in gingival crevicular fluid can be used as an early indicator of bone formation along with other parameters.

Keywords: Alkaline phosphatase class II furcation, collagen sponge, gingival Crevicular fluid, simvastatin

1. Introduction

The unpredictable success of molar furcation therapy is attributed to the morphology of the molar furcation and the resultant periodontal lesion. Involvement of the furcation with periodontal disease is a leading cause for tooth loss [1]. A plethora of options have been attempted for treating and improving the prognosis of Class II furcation defects. They include autografts, allografts, xenografts, enamel matrix protein derivatives, barrier membranes and growth factors [2]. It is critical to use an agent which can exert local effects by promoting bone regeneration; biological molecules like Bone Morphogenetic Protein 2 (BMP-2) and Fibroblast growth factor has been used. However they tend to degrade at the site and are relatively expensive [3]. The quest for a safe and cost effective pharmacological agent that could affect bone regeneration by stimulating expression of BMP-2 led to an inquiry into local use of Statins. Simvastatin a synthetic statin, is an inhibitor of 3-hydroxy-3-methylglutaryl coenzyme A (HMG-CoA) reductase enzyme in mevalonate pathway of cholesterol synthesis, thus used in treatment of hyperlipidemia [4]. Statins also possess cholesterol independent effects. It not only prevents bone resorption by suppressing osteoclast differentiation but also exerts bone anabolic effects by up regulating the expression of BMP-2 to induce osteoblast differentiation. [5] Systemic statin therapy is found to bolster bones and is associated with decreased tooth loss in patients with chronic periodontitis [6]. Animal studies using injectable Simvastatin in furcation defects showed a potential to augment alveolar bone. Simvastatin in collagen type I

sponge carrier reported osteoinductive activity [7, 8]. An *in-vitro* study, confirmed that Simvastatin promoted osteoblastic differentiation of human periodontal cells and expression of alkaline phosphatase activity after 7 and 14 days. Expression of Alkaline phosphatase is known to be a differentiation marker of osteoblasts; its increased expression is suggestive of the potential of Simvastatin for periodontal regeneration [9]. The present research evaluated the levels of alkaline phosphatase in gingival crevicular fluid from furcation defects treated with Simvastatin collagen graft.

2. Materials and methods

2.1 Trial design: This was a controlled, interventional study with split mouth design. It was a single centred prospective study.

The study was conducted at the Department of Periodontology, JSS. Dental College and Hospital, a constituent college of JSS Academy of Higher Education and Research, Mysore, India from February 2011 to November 2012. The study protocol was approved by the Institutional Review Board, JSS Dental College and Hospital, an affiliated institution of the JSS Academy of Higher Education and Research, Mysore. The investigation was performed in accordance to the requirements of the "Declaration of Helsinki" as was adopted by the 18th World Medical assembly in 1964 and revised in Edinburgh in 2000.

2.2 Patient selection: Patient enrolment was conducted by a study examiner¹ by purposive sampling from the outpatients presenting to the department of Periodontology. Patients were explained the elected procedure in detail and included for the study with their written consent. Twenty systemically healthy subjects, 6 men and 14 women within the age group 45-55 years were included in the study. The presence of two contra lateral sites with Class II furcation involvement was necessary for intervention. Only vital teeth, as revealed by a positive cold test, were included in the study. Subjects in good systemic health, with no inflammatory, infectious, immune or hormonal anomalies were included. Smokers, pregnant and lactating women, patients on systemic statin therapy or those with confirmed allergy to the material were excluded.

2.3 Randomization and Intervention: Initial therapy done prior to randomisation and surgical intervention consisted of scaling and root planing of the selected teeth in the planned quadrant was performed using ultrasonic device and hand currettes. Patients were re-evaluated after 6 weeks of initial therapy and scheduled for intervention based on presence of two similar contra lateral defects (Hamp's defect, horizontal loss of periodontal support $\geq 3\text{mm}$ but $\leq 7\text{mm}$) and plaque index and gingival index less than 1. The selected sites i.e. two contra lateral sites with class II furcation involvement in each individual were randomized using toss of a coin. The sites were assigned as test site (Simvastatin collagen graft) and control site (collagen graft) by the study therapist[‡].

2.4 Outcome Measures: GCF alkaline phosphatase was estimated at baseline, 7 days and 14 days as a biomarker of early bone formation. The clinical parameter recorded at baseline and 6, 9, 12 and 15 month intervals was the change in horizontal PD. The radiographic parameter assessed was the bone area at baseline, 6, 9, 12 and 15 months postoperative period.

On the day of surgical intervention (baseline), the selected sites were isolated and 2 microns of GCF was collected using

a 5 micron micropipette from the gingival sulcus of the teeth to be treated (Figure 1). This was repeated on 7th day and 14th day. The samples were stored in sterile vials containing 2 ml tris carbonate buffer in a freezer at 4 degree C and sent for estimation of alkaline phosphatase level. Pre-surgical clinical measurement made was horizontal Probing depth at the furcation using 2N Naber's probe. Conventional intraoral periapical radiographs with a X ray mesh gauge were taken at baseline and repeated at 6 months by the study examiner¹ and area of bone fill was assessed using a computer aided software.[†]

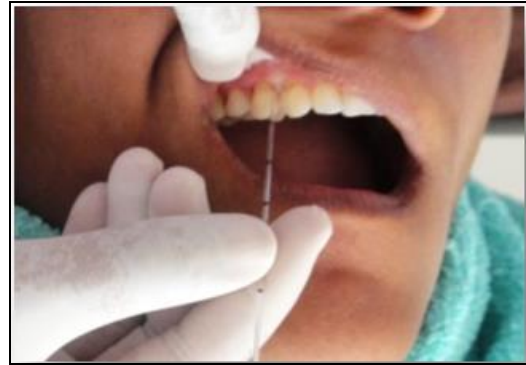

Fig 1: Collection of GCF from periodontal pocket site for ALP estimation

2.5 Procedure of graft formulation: 1.2 grams of Simvastatin powder was added to 100ml biologic grade ethanol and stirred until the powder completely dissolved to form a clear solution. The solution thus obtained had a concentration of 12mg/ml (1.2 mg/0.1 ml). The solution was stored in a sterile dark glass bottle and closed to obtain a tight seal. A sterile collagen sponge of dimension 10 mm X 10 mm[¥] was impregnated with 0.1 ml of Simvastatin solution to form Simvastatin collagen graft 15 minutes prior to its placement in the defect site.

2.6 Surgical Procedures: Local infiltration of 2% lidocaine containing epinephrine at a concentration of 1:100,000. Full thickness mucoperiosteal flaps were reflected and the furcation defect was thoroughly debrided. The collagen graft was placed in the control site and statin collagen graft was placed in the test site. The flaps were repositioned with interrupted sutures using 4-0 silk sutures and a periodontal dressing was placed over the surgical area. Postoperative instructions, antibiotics and oral analgesics were prescribed. One week postoperatively, periodontal dressing and silk sutures were removed. Patients were examined at 1-week, 2-week, and 6-month intervals after the surgeries.

2.7 Alkaline Phosphatase estimation: The level of ALP was estimated with an auto analyzer[‡] by using Wilkinson's adaptation of the Bessy and Lowrey method based on the principle that at a pH 10.3, alkaline phosphatase catalyses the hydrolysis of p-Nitro phenyl phosphate to yellow colored p-Nitro phenol and phosphate. The change in absorbance measured by autoanalyzer at 405 nm wavelength is proportional to ALP activity in the sample.

2.8 Statistical analysis: The values obtained from clinical evaluation were tabulated and subjected to statistical analysis using statistical software[‡]. The descriptive statistics and repeated measure ANOVA test was employed to assess the changes in the parameters at various intervals. The paired "t-

test” was used for intra group comparisons over the durations. The independent samples “t” test was used for inter group comparisons over the durations. Any value < 0.05 was considered statistically significant.

3. Results

The number of subjects analyzed and the study drop outs are presented in the consort flowchart (Figure 2). On clinical examination no inflammation or erythema in the test and control sites was observed one week post operatively and no patient reported with discomfort. The estimation of Alkaline phosphatase in GCF showed a significant ($p<0.05$) increase in levels in defects treated with Simvastatin collagen graft (test Sites). The defects that received collagen graft alone (control sites) showed decreasing levels of GCF alkaline phosphatase from baseline to 7th and 14th day, although the difference was

not statistically significant (table 1). The clinical and radiographic parameters were evaluated over a longer duration of 15 months. The intra-group comparison for GCF alkaline phosphatase revealed a statistically significant increase in test sites in comparison to control sites (table 2). On intra group comparison, a statistically significant ($p<0.05$) decrease in the site specific horizontal bone probing depth was found in test sites and control sites from baseline over 15 months. A statistically significant increase in bone area was observed in the test sites but not in the control sites over 12 months (table 3). On inter group comparisons, statistically significant difference in horizontal bone probing depth from base line to 15 months interval was observed. A statistically significant ($p<0.05$) increment in furcal bone area was seen in the test sites compared to control sites (table-4).

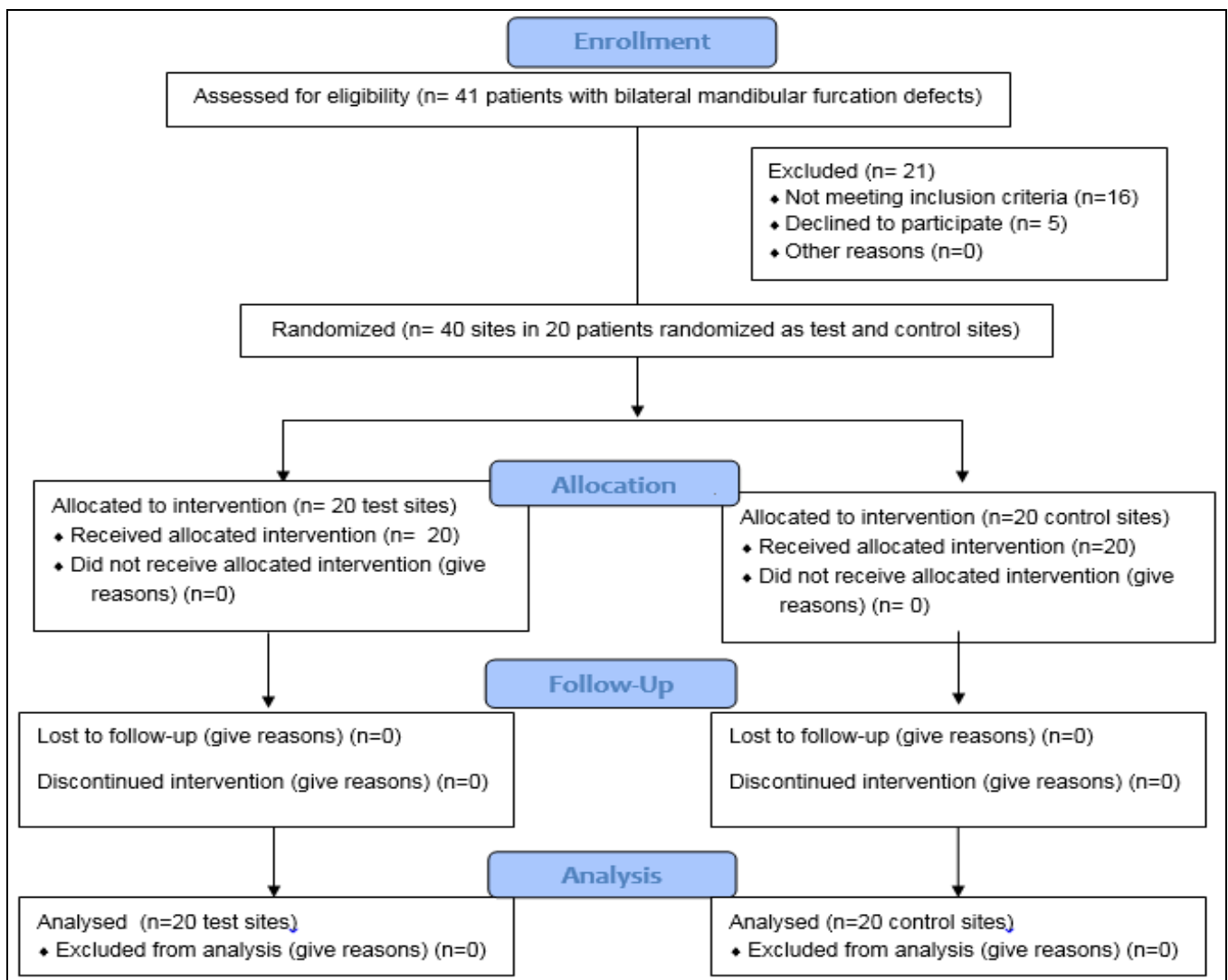


Fig 2: Consort flow chart for patient enrolment, allocation, follow up and analysis

Table 1: Intra group comparisons of mean values of parameters at various time intervals. H-PD- Horizontal bone probing depth; Bone area- Mean values of bone area at the furcation. N- Number of sites.

Group	Test sites (N=20)		Control sites (N=20)	
	H-PD	Bone Area	H-PD	Bone Area
Baseline	2.85±0.58	2.83±1.33	3.10±0.30	2.29±0.96
6 months	2.05±0.22	3.19±1.41	2.40±0.50	2.28±0.69
9 months	1.90±0.44	3.54±1.63	1.95±0.22	2.44±0.77
12 months	1.45±0.60	3.85±1.55	1.80±0.41	2.67±0.86
15 months	1.40±0.59	4.44±1.94	1.85±0.48	2.69±0.93
p value	0.000	0.022	0.000	0.363

$P \leq 0.05$ was considered statistically significant.

Table 2: Inter Group comparisons of mean values of parameters at various time intervals. H-PD- Horizontal bone probing depth; Bone area- Mean values of bone area at the furcation.

Parameter	H-PD			Bone Area		
	Test	Control	p value	Test	Control	P-value
Baseline	2.85±0.58	3.10±0.30	0.100	2.83±1.33	2.29±0.96	0.151
6 months	2.05±0.22	2.40±0.50	0.007	3.19±1.41	2.28±0.69	0.013
9 months	1.90±0.44	1.95±0.22	0.657	3.54±1.63	2.44±0.77	0.010
12 months	1.45±0.60	1.80±0.41	0.039	3.85±1.55	2.67±0.86	0.005
15 months	1.40±0.59	1.85±0.48	0.013	4.44±1.94	2.69±0.93	0.001

P<0.05 was considered statistically significant.

Table 3: Intra-group comparisons of GCF ALP between Simvastatin collagen graft (test) and collagen graft (placebo) sites over different time intervals.

Group	Test site	Control site
N= 20 Baseline	12.46 ± 5.45	14.43 ± 12.05
7 days	33.05 ± 21.51	18.19 ± 15.46
14 days	37.76 ± 22.26	12.94 ± 11.12
p-value	0.426	0.426

Statistically significant at P<0.05.

Table 4: Inter-group comparisons of GCF ALP between Simvastatin collagen graft (Test Group) and collagen graft (Control) sites over different time intervals.

Parameter	Test sites	Control sites	P value
GCF ALP			
Baseline	12.46 ± 5.45	14.43 ± 12.05	0.511
7 days	33.05 ± 21.51	18.19 ± 15.46	0.016
14 days	37.76 ± 22.26	12.94 ± 11.12	<0.001

Statistically significant at P<0.05.

4. Discussion

Furcation involvements are the root ward extension of periodontal pockets in the regions of furcations leading to progressive attachment and bone loss. Long term studies have reported that molar teeth with furcation involvement are most commonly lost teeth due to their complex anatomy [10]. The management of moderate to advanced furcation defects remains a critical problem despite a large arsenal of therapeutic options. Thus the study intended to explore a novel option in furcation therapy.

Since the furcation defects are difficult to access and instrument due to their anatomical constraints, open flap approach yields more effective debridement of the area [11]. Hence the surgical approach was opted.

Although bone grafting and guided tissue regeneration have improved the prognosis of class II furcation defects, they have not promised predictability. Biological molecules like BMP-2 and other growth factors are not only expensive but also have shown degradation and at the site and elicit immune response.³ Simvastatin is a synthetic statin which can stimulate new bone formation by expression of BMP-2. The successful use of Simvastatin to promote bone formation in vivo depends on its local concentration and this prompts the need of a carrier that maintains sustained drug release and provide a matrix for mesenchymal cell migration [5]. Purified collagen grafts is proven to be a good delivery vehicle for statins [12]. In this study the efficacy of Simvastatin collagen graft in furcation defects was compared to collagen graft in contra lateral furcation defects.

Clinically significant changes in furcation are often not detected by radiographs. The initial vertical pocket curves horizontally into the furca in the furcation involved teeth.¹³ In the present study, the furcation involvement was assessed clinically by measuring the horizontal probing depth at the furca using a Naber's probe and a radiograph with grid was used for estimation of bone fill. Since, both parameters are

inconclusive and a surgical re-entry invasive, alkaline phosphatase was used as a biomarker for bone formation.

Alkaline Phosphatase is among the first functional genes expressed in the process of calcification and represents a useful biochemical marker of bone formation. It is expressed early in development by proliferating osteoblasts and is soon observed on the cell surface and in matrix vesicles. Later in the developmental program, while other genes (e.g. osteocalcin) are up regulated, ALP expression declines. Clearly, ALP must function in the initial phases of the process [14]. Previous studies have measured alkaline phosphatase levels in GCF to assess its relation to periodontal status and bone metabolism [15]. *In vitro* study demonstrated that Simvastatin stimulated alkaline phosphatase activity, affecting proliferation and osteoblastic differentiation of human periodontal ligament cells [90]. Since alkaline phosphatase is a biomarker for early bone formation, it was assessed in GCF sampled from the defect sites on 7th day and 14th day after intervention with Simvastatin collagen graft and collagen graft alone. Since horizontal probing depth and radiographic evidence of bone fill can be assessed only on longer durations, they were recorded at 6,9,12 and 15 months interval.

The significant reduction in horizontal probing depth in both test and control groups over time, can be attributed both to the meticulous debridement of the furcation defect and the placement of Simvastatin collagen graft or collagen graft. However, a significant decrease in test sites in comparison to control sites may hint to the better efficiency of Simvastatin collagen graft. The results are similar to another research which used 1.2 mg Simvastatin delivered subgingivally in class II furcation defects with significant reduction in probing depth [16]. As the same study found 1.2mg/ml Simvastatin to be effective and safe as confirmed by release kinetics, the same concentration was adopted in this study.

An animal study which compared 2.5 mg/ml Simvastatin collagen graft against collagen graft as active control in parietal bone defects reported a 308% increase in new bone in the statin site concluding that Statins can be used as osteoconductive agents in absorbable collagen carriers [12]. In the present study 173% bone fill was observed in furcation defects treated with Simvastatin collagen grafts against 61% in furcation defects that received collagen grafts.

Alkaline phosphatase levels in GCF sampled from test sites showed an increasing trend on 7th and 14th day in contrast to the control sites that showed a decreasing trend. The difference was significant. The invitro study also revealed increased alkaline phosphatase after 7th and 14th day [9]. Another animal study estimated alkaline phosphatase levels on 5th and 10th day after local application of Simvastatin, and reported an increase in alkaline phosphatase activity but not osteocalcin, thus suggesting alkaline phosphatase to be differentiation marker of osteoblasts in early bone formation and osteocalcin appeared in later stages of mineralisation [17]. The inclusion of alkaline phosphatase as a biomarker holds the advantage of being non-invasive, cost effective, simple and rapid addition to clinical and radiographic parameters for more precise diagnosis and post-operative assessment. The study lacked the assessment of bone formation in later stages using other biomarkers like osteocalcin. Newer radiographic techniques like Cone beam Computerised tomography and other biomarkers like BMP-2 can also be used but with cost concerns. Since this is a preliminary study evaluating Simvastatin collagen graft in furcation defects, the more common parameters were employed.

5. Conclusion

The study encourages the use of Simvastatin in a collagen carrier in class II furcation defects with ease. It can be a cost effective and simple adjective to surgical treatment. Alkaline phosphatase can be a reliable biomarker. However, similar multi centre studies in larger population using other carriers and varying dosages of Simvastatin may yield more predictable results.

6. Acknowledgement

This study was supported by the research grant received from Indian council of Medical research (ICMR), New Delhi.

7. References

- Guey-Lin Hou, Yu-Min Chen, Chi-Cheng Tsai, Weisgold, Arnold S. A New Classification of Molar Furcation Involvement Based on the Root Trunk and Horizontal and Vertical Bone Loss. *International Journal of Periodontics & Restorative Dentistry*. 1998; 18:256-265.
- Taheri M, Molla R, Radvar M, Sohrabi K, Najafi M. An evaluation of bovine derived xenograft with and without a bio absorbable collagen membrane in the treatment of mandibular Class II furcation defects. *Australian Dental Journal*. 2009; 54:220-227.
- Garrett IR, Gutierrez G, Mundy GR. Statins and bone formation. *Current Pharmaceutical Design*. 2001; 7:715-736.
- Mundy GR, Garrett R, Harris S, Chan J, Chen D, Rossini G *et al*. Stimulation of bone formation invitro and in rodents by Statins. *Science*. 1999; 286:1946-1949.
- Park JB. The use of Simvastatin in bone regeneration. *Med Oral Patol Oral Cir Bucal*. 2009; 14:485-488.
- Cunha-Cruz J, Saver B, Maupome G, Hujoel PP. Statin Use and Tooth Loss in Chronic Periodontitis Patients. *J Periodontol*. 2006; 77:1061-1066.
- Morris MS, Lee Y, Lavin MT, Giannini PJ, Schmid MJ, Marx DB. *Et al*. Injectable Simvastatin in Periodontal Defects and Alveolar Ridges: Pilot Studies. *Journal of Periodontology*. 2008; 79(8):1465-1473.
- Pradeep AR, Priyanka N, Kalrs N, Naik SB, Singh SP, Martande S. Clinical Efficacy of Subgingivally Delivered 1.2-mg Simvastatin in the Treatment of Individuals With Class II Furcation Defects: A Randomized Controlled Clinical Trial. *J Periodontol*. 2012; 83:1472-9.
- Yazawa H, Zimmermann B, Asami Y, Bernimoulin JP. Simvastatin Promotes Cell Metabolism, Proliferation, and Osteoblastic Differentiation in Human Periodontal Ligament Cells. *Journal of Periodontology* 2005; 76:295-302.
- Glickman I. Bifurcation involvement in periodontal disease. *J Am Dent Assoc*. 1950; 40:528.
- Matia JI, Bissada NF, Maybury JE. Efficiency of scaling of molar furcation area with and without surgical access. *Int. J. Periodontics restorative Dent*. 1986; 6:25-35.
- Wong RWK, rabie ABM. Statin collagen grafts used to repair defects in the parietal bone of rabbits. *British Journal of Oral and Maxillofacial Surgery* 2003; 41:244-248
- Newell DH. The diagnosis and treatment of molar furcation invasions. *Dental Clinics of North America* 1998; 42:301-337.
- Golub EE, Boesze-Battaglia K. The role of alkaline phosphatase in mineralization. *Curr Opin Orthop* 2007; 18: 444-448.
- Nakashima K, Roehrich N, Cimasoni G. Osteocalcin, prostaglandin E2 and Alkaline Phosphatase in gingival crevicular fluid: their relations to periodontal status. *J clin periodontal*. 1994; 21:327-333.
- Pradeep AR, Priyanka N, Kalrs N, Naik SB, Singh SP, Martande S. Clinical Efficacy of Subgingivally Delivered 1.2-mg Simvastatin in the Treatment of Individuals With Class II Furcation Defects: A Randomized Controlled Clinical Trial. *J Periodontol*. 2012; 83:1472-9.
- Ayukawa Y, Ogino Y, Koyano K. Local application of statin promotes bone repair through the suppression of osteoclasts and the enhancement of osteoblasts at bone-healing sites in rats. *Oral Med Oral Pathol Oral Radiol Endod*. 2009; 107(107):336-342.