



ISSN Print: 2394-7489  
ISSN Online: 2394-7497  
IJADS 2018; 4(3): 77-82  
© 2018 IJADS  
www.oraljournal.com  
Received: 13-05-2018  
Accepted: 14-06-2018

**Dr. Shubhangi Pandurang Lokhande**  
Post Graduate Student of  
Prosthodontics, Goa Dental  
College and Hospital, Goa, India

**Dr. Meena Ajay Aras**  
Professor and Head, Department  
of Prosthodontics, Goa Dental  
College and Hospital, Goa, India

**Dr. Praveen Rajagopal**  
Assistant Professor, Department  
of Prosthodontics, Goa Dental  
College and Hospital, Goa, India

**Dr. Ashwin Mysore**  
Lecturer, Department of  
Prosthodontics, Goa Dental  
College and Hospital, Goa, India

**Dr. Aradhana Nagarsekar**  
Assistant Professor, Department  
of Prosthodontics, Goa Dental  
College and Hospital, Goa, India

**Dr. Ankita Chamaria**  
Former Post Graduate Student  
of Prosthodontics, Goa Dental  
College and Hospital, Goa, India

## Evaluation of patient acceptance using three techniques for the fabrication of ocular prosthesis: A case report

**Dr. Shubhangi Pandurang Lokhande, Dr. Meena Ajay Aras, Dr Praveen Rajagopal, Dr. Ashwin Mysore, Dr. Aradhana Nagarsekar and Dr. Ankita Chamaria**

### Abstract

**Background:** Causes for loss of eyes can be congenital, traumatic, malignancy or radical surgery [1]. It may have a severe physical & psychological impact on the patient. Rehabilitation of a prosthodontics patient with an ocular prosthesis is a challenging procedure.

**Technique:** This article describes three different techniques for fabrication of ocular prosthesis.

**Discussion:** A sequence of steps for fabrication of an ocular prosthesis is outlined & the critical areas of fabrication including the artistic techniques & options that can be used in successful prosthetic rehabilitation are described in this article.

Three techniques namely, Modified stock eye technique, Conventional iris paint on technique & Digital photographic technique are explained along with the indications, advantages & disadvantages.

**Conclusion:** The patient was most satisfied with Digital photography technique as compared to other two techniques.

**Keywords:** Custom eye prosthesis, digital photography, stock eye

### Introduction

The partial or total loss of an eye impairs the patient's visual function & also results in a noticeable deformity. The use of ocular prosthesis has been a boon to such patients [1, 2]. Although patients cannot see with the prosthesis, it would definitely restore their self-esteem & allow them to confidently face the world rather than hiding behind dark glasses. This case report explains & compares three different techniques for fabrication of an ocular prosthesis are to rehabilitate a patient after enucleation of an eye. The three techniques described are a Modified stock eye technique, the Iris customisation with the use of conventional paint on technique & the Digital photographic method of fabricating eye prosthesis.

### Case presentation

A 23-year-old male patient was referred to the Department of Prosthodontics and Crown & Bridge, for rehabilitation with a ocular prosthesis. The patient had history of accidental injury at his work place that resulted in trauma to his right eye. Medical records revealed enucleation of the socket. The patient was examined for the relationship of palpebral fissure in an open & closed condition. Both the eyelids were intact. The patient was also evaluated for the muscle control of the palpebrae & the internal anatomy of the socket in resting position & in full excursion. The socket revealed a healthy tissue bed and adequate depth between the upper and lower eyelids for the retention of the ocular prosthesis. (Figure 1)

### Modified stock eye technique

A prefabricated stock eye was selected resembling the contralateral eye in shape, size, colour & iris positioning. The socket was irrigated with chilled saline. The stock eye was trimmed to fit in the socket without any irritation to the tissue bed. While trying the stock eye in socket, it was first immersed in lens solution (Renu contact lens solution) for lubrication. After insertion of the modified stock eye, the patient was not satisfied with colour & size of the iris of the stock eye. (Figure 2)

### Correspondence

**Dr. Shubhangi Pandurang Lokhande**  
Post Graduate Student of  
Prosthodontics, Goa Dental  
College and Hospital, Goa, India

### Customised ocular prosthesis with conventional paint on technique

#### Fabrication of custom tray

A custom impression of the eye socket was made using [3] a technique similar to the one developed by Allen & Webster (1969).

The stock eye was submerged in alginate impression material (Tropicalgin Alginate, Zhermack) to get a mould. (Figure 3) The alginate mould was filled with clear autopolymerising

acrylic resin (DPI, India) to form a custom tray. To improve the adaptation, border moulding was done with low fusing impression compound stick (DPI pinnacle tracing sticks, Dental products of India). A circular inlet was cut in the center of the tray to attach an automixing tip & multiple small holes were made around the inlet for retention of impression material & to relieve pressure on the tissue bed while making an impression. (Figure 3)

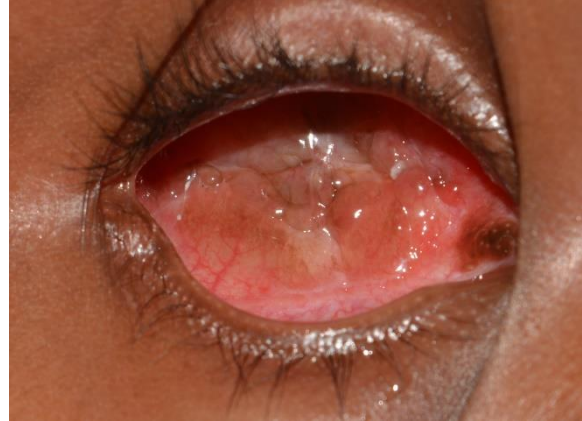

Fig 1: Eye socket

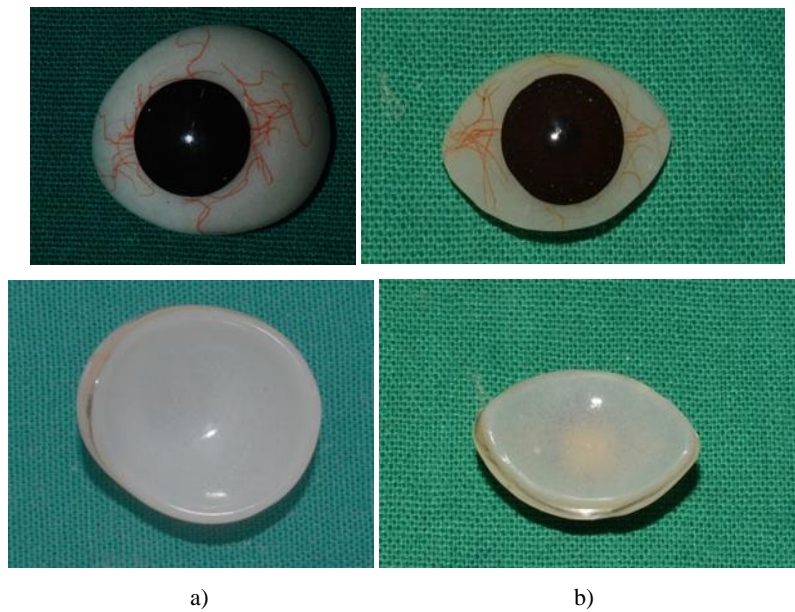
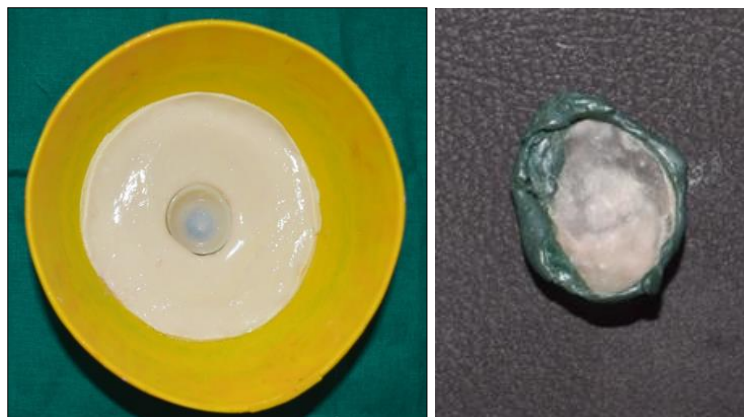

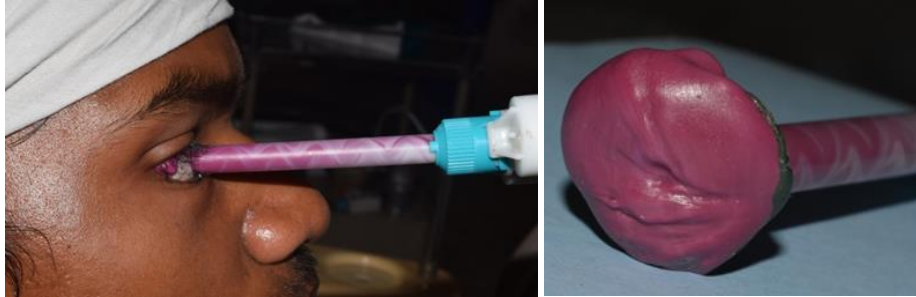


Fig 2: Stock Eye: a) The Prefabricated stock eye b) The modified stock eye

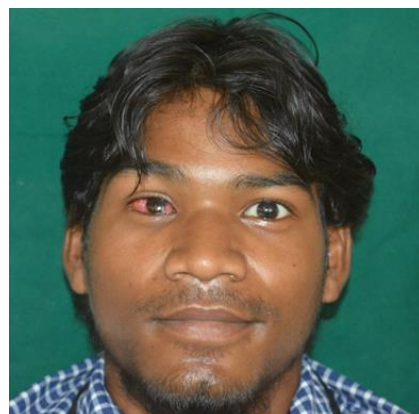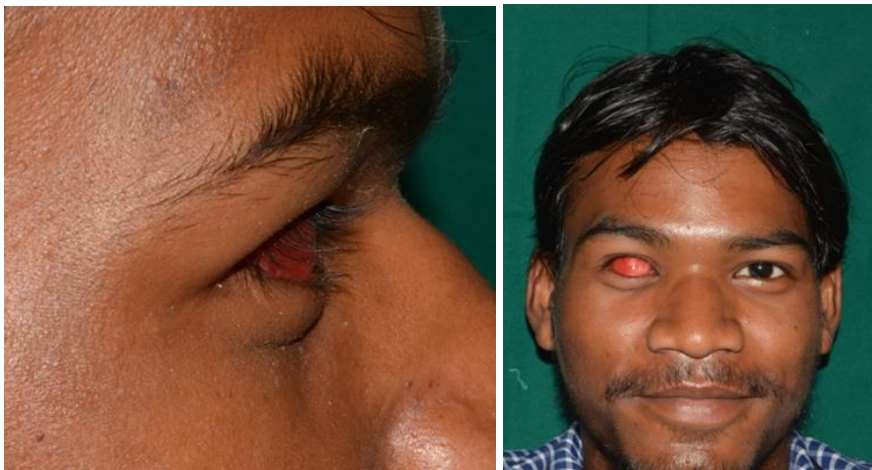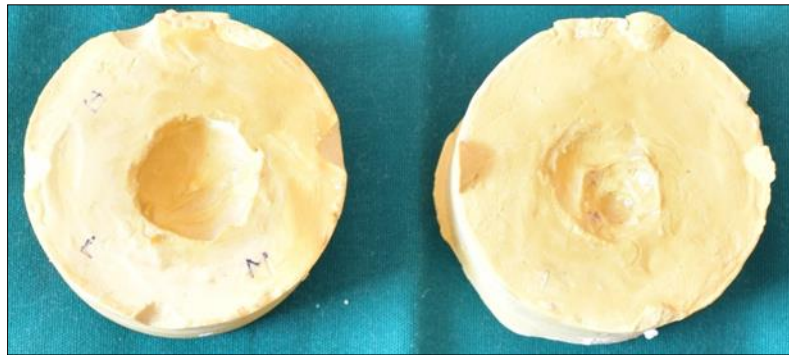




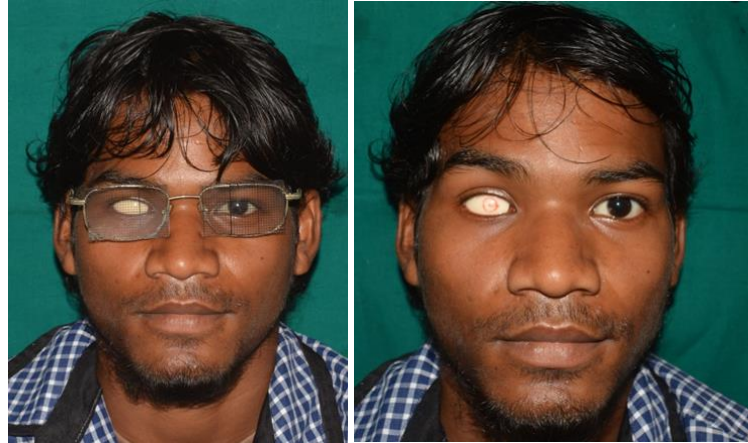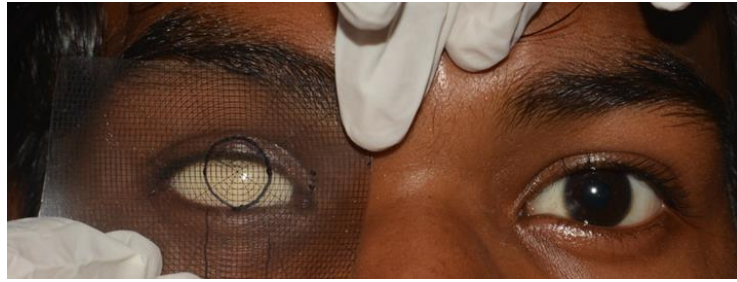
**Fig 3:** Customised ocular tray



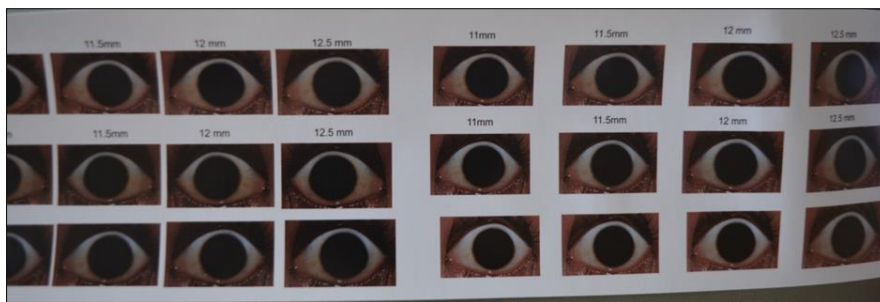
**Fig 4:** Impression procedure



**Fig 5:** Fabrication & trial of wax conformer



**Fig 6:** Iris positioning with graph & spectacle



**Fig 7:** Images with different contrast & brightness.



a) b) c)

**Fig 8:** Pre & post ocular prostheses with three different techniques

### Impression procedure

The patient's right eyelids & eyelashes were lubricated with petroleum jelly. The impression material (Dentsply Aquasil ultra monophasic) was injected through the automixing tip connected to a cartridge of the dispensing gun. (Figure 4) The patient was asked to move the normal eye in all directions to allow proper flow of the impression material during function.

A two mould technique was used to make a cast. The impression was poured in Type III dental stone till the height of contour to get the first half of the mould. After it was set, orientation grooves were made & a lubricant was applied on the first half & the second part was poured.

The two parts of the mold were separated & the impression was removed. Molten modelling wax (Modelling Wax, Deepti Dental Products of India Pvt. Ltd.) was poured into the mold. The wax conformer was retrieved, smoothened & tried in the eye socket of the patient (Figure 5). It was contoured to match the convexity of the contralateral eye. Iris positioning was done with a circular square graph with 1mm scale attached to a spectacle frame<sup>4</sup>. The iris was housed in the wax conformer in the marked area. The wax conformer was polished & invested. After deflasking, heat cure clear acrylic resin (DPI, India) was packed & acrylisation was carried out conventionally.

The wax pattern was flaked, dewaxed & packing was done with heat cure acrylic denture base material (DPI heat cure, dental products of India). The sclera was painted with composite stains (SR Adoro Stains, Ivoclar Vivadent, Germany) & cured in the polymerization unit. The stains were protected using protective coating (G-Coat Plus, GC America Inc.) The prosthesis was finished, polished & tried in the patient's eye socket.

### III) Digital photography technique

Impression making & contouring of the wax pattern was similar to the second technique. The wax pattern was flaked & processed using clear heat polymerising acrylic resin mixed with tooth moulding powder (DPI, India). The scleral blank was tried, with the patient sitting erect & viewing an object kept at least 3 feet in ahead of & at the level of natural eye. (Figure 6) The supraorbital folds, margins of the lower eyelids & outer contour of scleral blank were evaluated. The diameter of the iris & pupil on the intact side was measured. Then the patient was instructed to stare at infinity, & photographs of frontal images of the entire face & orbital regions & images of the existing eye were taken using a digital camera ((NIKON D5200 with the 18–55 kit lens) in daylight. As the diameter of a pupil changes depending upon the distance of object from eye to focus. It was important to obtain numerous photos with varying focal distances in different exposures, so that the most suitable images could be selected.

The image obtained was edited by using Corel Draw (Corel Draw Graphics Suite X5, Corel Corporation) and Adobe Photoshop CS4 (Adobe Systems Inc.) The edit included mirroring the image and spreading the scleral part of the image to cover the conformer sufficiently. Different amalgamation of brightness and contrast were used to produce a variety of images so as to take up the closest match for the prosthesis. (Figure 7) The images obtained were printed on a self-adhesive glossy vinyl paper sticker using a colour laser

printer. The photographs were evaluated & compared with iris & sclera of the normal eye of the patient.

Using the graph method<sup>[4, 5]</sup> (Figure 6), the iris position was marked on the scleral blank. The images printed on the paper sticker were matched to the contralateral eye, and the best one was selected and cut precisely to cover the visible palpebral fissure area. The cutout was then pasted on the conformer. A protective coating (G-Coat Plus, GC America Inc.) was applied over the sticker to protect the color of the printed iris & the sclera. A layer of clear heat cure acrylic resin was obtained over it by packing the prosthesis in the previous mold that was preserved for further processing. This gives a glossy and realistic appearance to the prosthesis.

The patient was instructed to gaze ahead in the distance & to shut the eyelids intermittently. (Having the patient gaze ahead fixes the position of the tissues of the socket & aligns the axes of both pupils. Closure of the eyelids helps the patient to express fluid from the lacrimal glands, which assists to reduce the dehydration & discomfort of the eye socket.<sup>1)</sup>

The ocular prosthesis obtained was finished and polished and was delivered to the patient with post-delivery instructions.

Among the three prostheses, patient was happy with the prosthesis fabricated with digital photographic method. (Figure 8)

### Post-delivery instructions<sup>[6]</sup>

It is advised

- To wear the prosthesis as long as it remains comfortable & is not irritating
- To keep the artificial eye in water or contact lens solution.
- The prosthesis should never be stored in a paper towel or tissue paper. Allowing the artificial eye to dry may cause its various layers to separate, making it ineffective.
- Eyeglasses should always be worn to protect the natural eye.

### Discussion

Many clinicians have concluded that iris colour of prosthetic eye is the most important consideration for esthetic acceptance of the prosthesis<sup>[7]</sup>. A stock eye comes with predetermined iris & sclera colour & does not adapt well to the tissue bed.

The custom-made acrylic resin ocular prosthesis achieves intimate contact between prosthesis & tissue bed. The close adaptation of the custom made prosthesis tends to distribute pressure more equally than does a stock eye prosthesis. This helps reduce the incidence of conjunctival abrasion or ulceration. It also enhances tissue health by reducing potential stagnation spaces at the prosthetic- tissue surface. Fluid collection in the space can cause tissue irritation & increase bacterial growth<sup>[8]</sup>.

Using digital imaging in the fabrication of ocular prosthesis provides acceptable esthetic results as it closely replicates the patient's iris & sclera<sup>[9]</sup>.

### Conclusion

Each technique has its own advantages & disadvantages. (Table 1)

| Techniques                                     | Advantages  | Disadvantages  |
|--|---|--|
| I Modified stock eye technique (Figure 8a)     | <ul style="list-style-type: none"> <li>• Easy</li> <li>• Requires less time to adjust</li> <li>• Economical</li> <li>• Can be used as interim prosthesis.</li> </ul>  | <ul style="list-style-type: none"> <li>• Stock eye usually do not match the convexity, shape, position of iris with that of contralateral natural eye</li> </ul> |
| II Conventional Paint on technique (Figure 8b) | <ul style="list-style-type: none"> <li>• As compared to stock eye close adaptation to the tissue bed provides maximum comfort to the patient, prevents collapse of supra orbital folds &amp; maintains palpebral opening similar to natural eye.</li> </ul> | <ul style="list-style-type: none"> <li>• Requires artistic skills</li> <li>• Time consuming</li> </ul>   |
| III Digital photographic technique (Figure 8c) | <ul style="list-style-type: none"> <li>• Decreased treatment time due to minimal artistic skills which are necessary in the iris painting technique</li> </ul>  | <ul style="list-style-type: none"> <li>• Special equipments like DSLR &amp; tripod are required.</li> <li>• Operator needs computer software skills.</li> </ul>  |

The challenging task of prosthetic rehabilitation of a lost eye can be made simple by following a technique which produces a comfortable & esthetic ocular prosthesis.

### References

1. Prashanti E, Reddy JM, Vinay Kumar, Mathew X. All about ocular prosthesis - A Review. 2008; 63:53-58.
2. Cain JR. Custom ocular prosthetics. J Prosthet Dent. 1982; 48(6):690-694.
3. Allen L, Webster HE. Modified impression method of artificial eye fitting. Am J Ophthalmol. 1969; 67(2):189-218.
4. Meena AA, Vidya C, Praveen R, Manjita MP. Precise iris positioning in ocular prosthesis using an eyewear. J Dental Sci. 2017; 2(1):000121.
5. Guttal SS, Patil NP, Vernekar N, Porwal A. simple method of positioning the iris disk on a custom-made ocular prosthesis. A clinical report. J Prosthodont. 2008; 17(3):223-7.
6. Parr GR, Goldman BM, Rahn AO. Postinsertion care of the ocular prosthesis. J Prosthet Dent. 1983; 49:220-4.
7. Debnath N, Gupta R, Meenakshi A, Ramkumar K, John J. A Simplified Approach to Fabricate a Custom-made Ocular Prosthesis. Int J Prosthodont Restor Dent. 2013; 3(1):25-29.
8. Taicher, Steinberg HM, Tubiana J, Sela M. Modified stock eye ocular prosthesis J Prosthet Dent. 1985; 54:95-8.
9. Jain S, Malkar S, Gupta S, Bhargava A. A prosthetic rehabilitation of ocular defect using digital photography: A case report. Jr Indian Prosthodont Soc. 2010; 10:190-3.