



ISSN Print: 2394-7489
ISSN Online: 2394-7497
IJADS 2018; 4(3): 217-223
© 2018 IJADS
www.oraljournal.com
Received: 04-05-2018
Accepted: 05-06-2018

Dr. Gazala Yasmeen
SJM Dental College & Hospital,
PB Road, Chitradurga,
Karnataka, India

Evaluation of diagnostic accuracy of digital bitewing radiography in assessing alveolar bone level in comparison with transgingival probing

Dr. Gazala Yasmeen

Abstract

Background and objective: Alveolar bone loss is a cardinal sign of periodontitis. Interproximal (bitewing) images more accurately record the crest of the interradicular alveolar bone because the beam is oriented at right angles to the long axis of the teeth, thus providing an accurate view of the relationship of the height of the alveolar bone through comparison with the adjacent teeth, however they tend to underestimate bone loss. It has been shown that the bone probing measurements is closely correlated with the actual bone level measured surgically and is the most reliable method for assessing bone levels before and after any surgical procedures. Hence the purpose of the study is to evaluate the diagnostic accuracy of digital bitewing radiographs in assessing alveolar bone level in comparison with transgingival probing.

Materials and methods: Sixty two subjects (age range 18-70 years, 34 males and 28 females) with chronic periodontitis were included. Radiographically alveolar bone level was measured by a single trained examiner using digital bitewing radiographs. Intraobserver correlation was done by intraclass correlation for radiographic data to avoid bias. Clinically transgingival probing was performed by a single trained examiner with stent in place using UNC 15 probe. The examiner was blinded to radiographic values to avoid bias. Results were statistically analyzed by paired sample t test, Pearson's correlation, intraclass correlation and regression methods.

Results: Intraclass correlation showed good reliability for radiographic measurements. Radiographic measurements showed consistently lower values compared to transgingival probing with an average underestimation of bone loss by 1.77 ± 0.44 mm. Pearson's correlation coefficient showed statistically significant correlation ($r = 0.960$) between the two methods. As, there was a significant correlation between the two methods, a correction factor could be applied to estimate "Transgingival probing measurement" based on radiographic values with derived formula $y = 0.9668x + 2.088$ where $y =$ Transgingival probing measurement, $x =$ Radiographic measurement.

Conclusion: Radiographic measurements overestimated alveolar bone level ie, underestimated bone loss. However as there was a correlation between two methods, a correction factor could be applied to estimate transgingival probing values based on radiographic values.

Keywords: Digital bitewing radiography, transgingival probing, alveolar bone level, periodontal disease, correction factor

Introduction

Periodontal diseases are one of the most extensively occurring diseases in the general population [1]. It is an inflammatory disease of the supporting tissues [1], cardinal sign of which is alveolar bone loss. Evidence suggests that periodontal bone loss could commence at an earlier age than previously thought [1]. Thus, early detection and treatment of this disease is important.

An overall assessment of the periodontal diseases is based on both the clinical examination and radiographic findings — the two investigations complement one another [3].

The most accurate method which can be used for assessing alveolar bone level (ABL) is to elevate the flap and measure the bone level directly, however this method causes discomfort to the patient and can damage the tissues [4]. It has been shown that the bone probing measurements is closely correlated with the actual bone level⁵ measured surgically and is the most reliable method for assessing bone levels before and after any surgical procedures [6].

Radiographs play an integral role in the assessment of periodontal disease. They provide unique information about the status of the periodontium and a permanent record of the

Correspondence

Dr. Gazala Yasmeen
SJM Dental College & Hospital,
PB Road, Chitradurga,
Karnataka, India

condition of the bone throughout the course of the disease [7]. Most commonly used radiographs in the diagnosis of periodontal diseases are periapical radiographs, bitewings and panoramic radiographs, however they tend to underestimate bone loss [4]. Others like CBCT, CT, Xeroradiography, CADIA, Digital subtraction radiography, scanography, Stereoscopy, nuclear medicine are also useful for evaluating the periodontium [6], but are not routinely used due to prohibitive costs.

Periapical views (paralleling technique), especially in the posterior maxilla, may present a distorted view of the relationship between the teeth and the height of the alveolar bone because the presence of the hard palate often requires the x-ray tube to be oriented slightly downward toward the posterior teeth to see the apices of these teeth. In this circumstance, the level of the buccal alveolar bone may be projected near or even above the level of the lingual cemento-enamel junction, thus making the bone height appear greater than it actually is [7].

Panoramic radiographs are not recommended for evaluation of periodontal disease because the distortion and poor image detail of panoramic views tend to lead the clinician to underestimate minor marginal bone destruction and overestimate major destruction [7]. Interproximal (bitewing) images more accurately record the distance between the cemento-enamel junction (CEJ) and the crest of the interradicular alveolar bone because with interproximal views the beam is oriented at right angles to the long axis of the teeth, thus providing an accurate view of the relationship of the height of the alveolar bone to the roots [7].

Bitewing radiographs are used both in clinical practice and epidemiological studies as they are characterized by their simplicity, reduced exposure time, have an advantage of coverage of posterior teeth and require less number of films than that of periapical radiographs [8].

The advent of digital imaging has revolutionized radiology. This revolution is the result of both technologic innovation in image acquisition processes and the development of networked computing systems for image retrieval and transmission [7]. The main advantage of digitized radiographs is the ability to manipulate and advance the quality of images using various software programmes [9]. In addition, digital intraoral receptors require less radiation than film, thus lowering patient exposure [7].

Recently, digital radiography has attracted a lot of attention in determining the depth, width and topography of bony defects and progression of the defect since loss of bone density and height should be evaluated using an automated instrument to diagnose periodontal lesions and assess the treatment success [9].

Digital bitewing radiographs were superior when compared to conventional bitewing radiographs in terms of alveolar bone loss in one of the study. Its cost factor is an important point of consideration, which can limit its use [10].

Hence the present study was undertaken to evaluate diagnostic accuracy of digital bitewing radiography in comparison in assessment of alveolar bone level in comparison with transgingival probing.

Objectives of the study are as follows

1. To assess alveolar bone level in digital bitewing radiographs.
2. To assess alveolar bone level clinically by transgingival probing.
3. To compare the alveolar bone level assessed by digital

bitewing radiograph with transgingival probing.

Subjects and Methods

Source of Data

The subjects for the study were selected by employing convenience sampling among patients reporting to the Department of Oral Medicine and Radiology, Maratha Mandal's Nathajirao G Halgekar Institute of Dental Sciences and Research Centre, Belagavi. This study included observation and analysis of digital bitewing radiographs and transgingival probing of 62 subjects aged between 18-70 years suffering from mild to moderate periodontitis.

Ethical approval

An approval from the institutional review board was obtained prior to the beginning of the study and all the participants were given brief information regarding the purpose of the study. Informed written consent was taken from willing subjects.

Selection Criteria

Inclusion criteria

1. Subjects between 18-70 years of age.
2. Subjects who have mandibular right second premolar and first molar.
3. Subjects with mild to moderate alveolar bone loss associated with mandibular right second premolar and first molar.

Exclusion criteria

1. Pregnant women.
2. Patients wearing intraoral appliance (eg. orthodontic wire), which may interfere with clinical and radiographic evaluation.
3. Patients with proximal caries/ crown/ root stumps in right mandibular second premolar and first molar.
4. Patients with supraerupted mandibular second premolar and/or first molar.

Results

The present study was conducted to evaluate the diagnostic accuracy of assessing alveolar bone loss with digital bitewing radiography in comparison with transgingival probing. The study was conducted in the Department of Oral Medicine and Radiology, Maratha Mandal's Nathajirao G Halgekar Institute of Dental Sciences, Belagavi among 62 subjects with chronic periodontitis.

The alveolar bone loss was measured by transgingival probing using UNC 15 periodontal probe and digital bitewing radiograph.

Age and gender distribution

Table 1: Gender wise distribution of study participants.

Gender	Frequency (n)	Percentage (%)
Female	28	45.2
Male	34	54.8
Total	62	100

A total of 62 subjects, 34 male and 28 female were included in the study. (Table 1)

Table 2: Age wise distribution of study participants

Age group	Frequency(n)	Percentage (%)
21-30 years	6	9.67
31-40years	14	22.58
41-50years	25	40.3
51-60years	8	12.90
61-70years	9	14.51
Total	62	100

There were no subjects in the age range of 18-20 years in our study sample. Among 62 subjects maximum numbers of subjects were in the age range of 41-50 years and minimum

numbers of subjects were in the age range of 21-30 years. (Table 2)

Table 3: Radiographic and transgingival probing measurements from reference line

Gender	Number	Radiographic measurement in mm (Mean±Std Dev)	Transgingival probing in mm (Mean±Std Dev)
Male	34	9.23 ±1.40	10.92 ±1.30
Female	28	9.69 ±1.67	11.52 ±1.74
Total	62	9.48 ±1.57	11.25 ±1.58

The mean alveolar bone level among 62 subjects by radiographic measurements was 9.48±1.57 and transgingival probing method was 11.25±1.58 showing overestimation of

alveolar bone level ie, underestimation of bone loss by radiographic method. (Table3)

Table 4: Intraexaminer reliability of radiographic measurements

	Mean	Std Deviation
1 st measurement	9.556	1.539
2 nd measurement	9.545	1.539

ICC –Single measurement intraclass correlation r=1.00, (p<0.001), significant

Clinical and radiographic measurements were performed in 62 subjects by the single examiner after training. The intraexaminer correlation and intraexaminer consistency for radiographic measurements was calculated using intraclass

correlation coefficient (ICC). There was a significant positive relationship between the 1st and 2nd measurement scores. (Table 4)

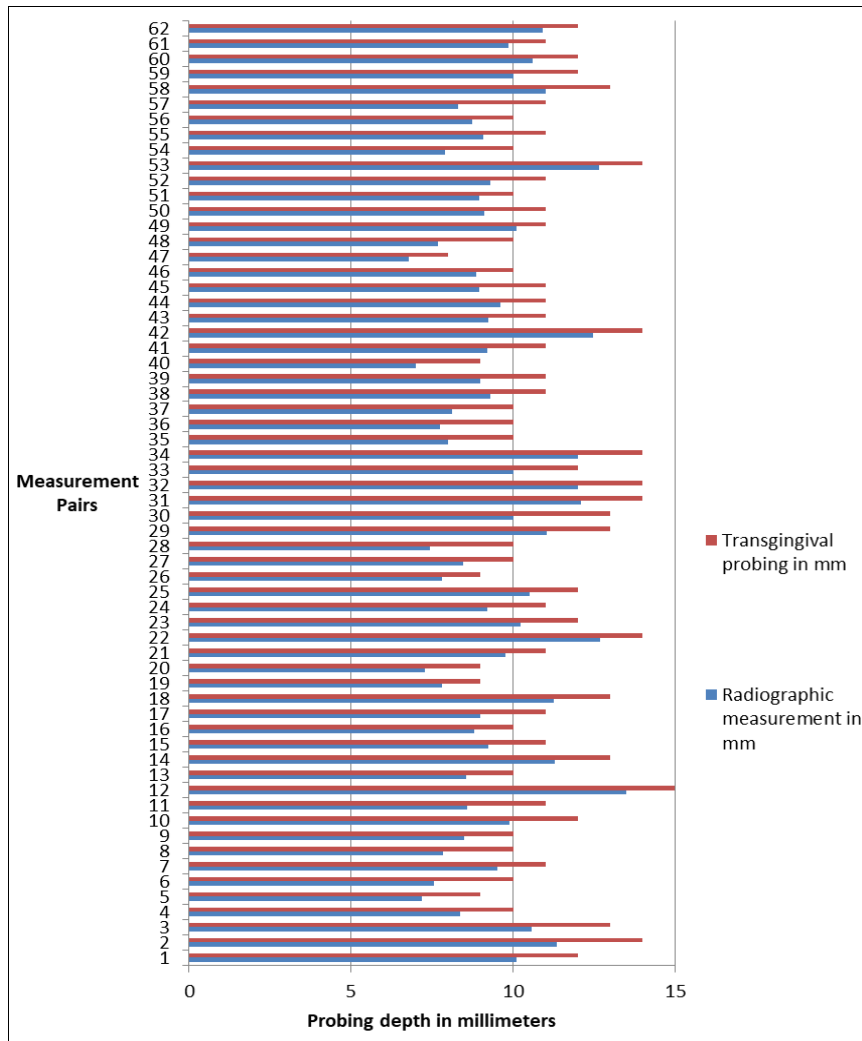
Table 5: Comparison of radiographic and transgingival probing values by paired t test\

Measurements	Mean	Std. Deviation	Paired t test	
			t-value	p-value and significance
Radiographic measurement	9.48	1.57	-31.23	<0.001, Significant
Trans gingival Probing	11.25	1.58		
Trans-gingival probing Minus Radiographic Measurements	1.77	0.44	---	---
Intra class correlation coefficient (single measures) and p-value, significance	0.960 (0.934 to 0.975), p-value <0.001, Significant			
Pearson’s correlation coefficient	R = 0.960 p-value <0.001, Significant			
Formula for estimating trans-gingival probing based on Regression	y = 0.9668x + 2.088 y= Trans-gingival probing measurement x= Radiographic measurement			

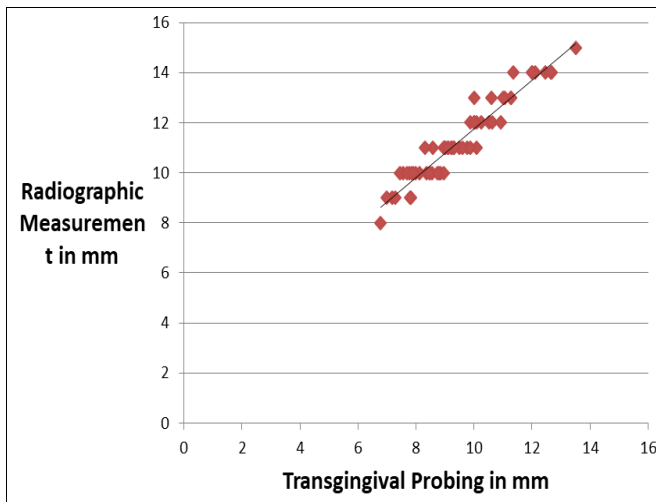
Radiographic measurements showed consistently lower values compared to transgingival probing with an average underestimation of bone loss by 1.77 ± 0.44 mm (Table 5, Graph 1). The difference between the two methods was statistically significant indicating that radiographic measurement can lead to significant underestimation of bone loss.

Correlation between the two methods of measurements showed that as the transgingival probing increases, radiographic measurement also increases, but with a mean

difference of 1.77±0.44 mm(Graph 2). Pearson’s correlation coefficient showed relationship between transgingival and bitewing radiographs measurement and statistically significant correlation (r =0.960) was found between the two methods (Graph 1). As, there was a significant correlation between the two methods, a correction factor could be applied to estimate “Transgingival probing” measurement based on radiographic vaues. A formula was derived by regression method y=0.9668x+2.088



Graph 1: Bar diagram showing higher values for transgingival probing compared to radiographic measurements from reference line in observation pairs



Graph 2: Scatter plot showing correlation between two methods of measurements

Points along the straight line indicate perfect agreement between both radiographic and transgingival probing measurements (Graph 2).

Discussion

Radiographs play an integral role in the assessment of periodontal disease. They provide unique information about the status of the periodontium and a permanent record of the

condition of the bone throughout the course of the disease. Radiographs aid the clinician in identifying the extent of destruction of alveolar bone, local contributing factors, and features of the periodontium that influence the prognosis [7]. Clinical examination should include periodontal probing, a gingival index, mobility charting, and an evaluation of the amount of attached gingiva. Features that are not well delineated by the radiograph are most apparent clinically, and those that the radiograph best demonstrates are difficult to identify and evaluate clinically. Radiographs are an adjunct to the diagnostic process [7]. Evidence suggests that periodontal bone loss could commence at an earlier age than previously thought [1]. Thus, early detection and treatment of this disease is important.

The most accurate method which can be used for assessing alveolar bone level is to elevate flap and measure the bone level directly and hence, it is considered to be the gold standard. However, this method and other invasive clinical methods like transgingival probing/bone sounding causes discomfort to the patients and they can damage the tissues [4, 28]. Recently Savitha B *et al.* [5] concluded that bone level measurement by transgingival probing which highly correlates with bone levels measured surgically, is the most reliable method for assessing bone levels before and after any surgical procedures. Hence this study was undertaken to evaluate the diagnostic accuracy in assessing alveolar bone level by digital bitewing radiographs in comparison with transgingival probing.

Our study group included 62 subjects in the age range of 18-70 years as chronic periodontitis is most frequently observed in adults, however it can also occur in children and adolescents in response to chronic plaque and calculus accumulation^[13].

Among studies conducted by Savitha B *et al.*^[5], Sairam V *et al.*^[8], Parashis A *et al.*^[16], Banodkar AB *et al.*^[17], Wolf B *et al.*^[23], Kim HY *et al.*^[24], G Li *et al.*^[25], Pahwa P *et al.*^[26], Kolte RA *et al.*^[27], Levin L *et al.*^[31] and the lower limit ranged from 18-27 years and upper age limit from 29-84 years. Age range was not mentioned in studies by Esmaeli F *et al.*^[9] and Pilgram TK *et al.*^[14],

Chronic periodontitis generally affects both genders equally¹³. Our study had unequal numbers of male (34) and female (28) subjects. This is in accordance with the gender wise distribution of subjects in assessing alveolar bone level radiographically by Savitha B *et al.*^[5], Sairam V *et al.*^[8], Singh S *et al.*^[10], Vasconcelos KDF *et al.*^[11], Walter C *et al.*^[15], Parashis A *et al.*^[16], Banodkar AB *et al.*^[17], Moradi J *et al.*^[21], Neetha MC *et al.*^[22], Eickholz P *et al.*^[33], Wolf B *et al.*^[23], Jenkins WMM *et al.*, Kim HY *et al.*^[7], Pahwa P *et al.*^[26], and included equal gender distribution. Levin L *et al.*^[31] included only males.

Subjects in whom right second premolar and first molar with proximal caries, crown, root stumps, supraerupted, wearing intraoral appliance (eg. Orthodontic wire) were excluded from the study as they known to affect clinical and radiographic evaluation. Which is in accordance with the studies by Savitha B *et al.*^[5].

In our study group right mandibular second premolar and first molar was used for clinical and radiographic evaluation. Single site was selected, for the standardization and ease of radiographic and clinical assessment. Other studies used multiple sites. Pecoraro ML *et al.*^[30] assessed alveolar bone level by evaluating the mesial and distal aspects of all available teeth excluding third molars while Streckfus CF *et al.*^[18] considered mesial and distal aspects of each tooth. Sairam V *et al.*^[8] included mesial and distal sides of first, second premolar and molars in both arches while Monali A *et al.*^[19] considered mesial and distal sites at the buccal and lingual aspects. Savitha B *et al.*^[5] considered 56 sites, where in mesial and distal surfaces were evaluated while Pilgrim *et al.*^[14] considered 6 sites per tooth, mesial edge, midtooth and distal edge on both facial and lingual sides. Moradi J *et al.*^[21] evaluated interproximal surfaces of posterior teeth.

Bone level is often measured from the cemento-enamel junction; however, this reference point is not valid in situations where there is over eruption or where there is severe attrition with passive eruption⁷ or caries / restoration / crown is present. Hence to overcome this drawback we used stent with incorporated metal as a reference line for standardization to assess bone level clinically and radiographically, similarly studies by Monali A *et al.*^[4], Savitha B *et al.*^[5], Kim HY *et al.*^[24], Wahi S *et al.*^[27], Kolte RA *et al.*^[28], Akesson L *et al.* and Soumi *et al.*^[31]. Clinically stent are used to guide the probe to an exact location with a proper orientation. Which is in accordance with studies by Monali A *et al.*^[4], Savitha B *et al.*^[5],

In our study radiographs were taken by using X mind DC, satelec machine. Others used Trophy intra-oral X-ray^[1], X mind AC^[10], Spectro 70X Selectronic dental X-ray^[11], minray intraoral X-ray unit^[20, 12] (Soredex), GX-770 X-ray^[30], Focus – X-ray^[25], Elity Trophy, Irix 70^[12] and Dixi digital intraoral X-ray^[31].

Digital bitewing radiographs were used in our study as Singh

S *et al.*^[10] stated that digital radiographs are superior when compared to conventional radiographs. Bitewing radiographic technique was used in our study as this technique accurately record the crest of the interradicular alveolar bone because the beam is oriented at right angles to the long axis of the teeth, thus providing an accurate view of the relationship of the height of the alveolar bone through comparison with the adjacent teeth^[7].

Bitewing radiographs are used in both clinical and epidemiological studies as they are characterized by their simplicity, reduced exposure time, have an advantage of recording the coronal portions of the maxillary and mandibular teeth in one image⁸. Which is in accordance with the studies by Asif S *et al.*^[1], Singh S *et al.*^[5], Streckfus CF *et al.*^[18], Safi Y *et al.*^[20], Neetha MC *et al.*^[22], and Kim HY *et al.*^[24]. However in studies by Moradi J *et al.*^[21], Pecoraro ML *et al.*^[30] conventional bitewing radiographs were used.

Studies by Savitha B *et al.*^[5], Sairam V *et al.*^[8], Vasconcelos KDF *et al.*^[13], Li G *et al.*^[25], Pahwa P *et al.*^[26], Pecoraro ML *et al.*^[27] and used digital periapical radiographs. Other studies by Vasconcelos KDF *et al.*^[11], Banodkar AB *et al.*^[17], Ferrare N *et al.*^[34] used other radiographs to assess alveolar bone level like panoramic radiography, CBCT, CT, microtomography.

Exposure parameters used for digital bitewing radiographs were 70 kVp, 8 mA and 0.080 sec, which is in accordance with the study by Levin L *et al.* The digital bitewing taken by Singh S *et al.*^[5], Safi Y *et al.*^[20], used exposure parameters 70 Kvp and 8mA, while Asif S *et al.*^[1] used the same parameters with 0.3 sec exposure time. Pecoraro ML *et al.*^[30] with radiation exposure time 10 pulses for mandibular posterior regions.

The sensor used in our study was Charge Coupled Device (CCD), which is in agreement with other studies by Asif S *et al.*^[1], Singh S *et al.*^[5], While other study by Safi Y *et al.*^[20] used photostimulable phosphor plates (PSP). Pecoraro ML *et al.*^[15] used complementary metal oxide sensor (CMOS sensor).

Measurements on image were done by using Xva3 3.5 version software. Other studies used Vixwinpro software^[1], digital-Kodak imaging software, Shick CDR, version 2.1, DIGORA software^[20] Ver 2.6 and Kodak 5000 digital software^[5]. Conventional bitewing radiographs taken by Streckfus CF *et al.*^[18] were digitized using periopro software. Hausmann E *et al.*^[35] digitized conventional bitewing radiographs utilizing a TV camera and PC computer with a Targa 8 imaging board. Vasconcelos KDF *et al.*^[11] digitized periapical radiographs using a scanner scanjet HP 4890

The examiner measured all the images at X 75 magnification for standardization. Pecoraro ML *et al.*^[29] measured all of the images at X 100 magnification. Brightness and contrast was not altered during measurements, which is in concordance with the study by Asif S *et al.*^[1], Pecoraro ML *et al.*^[29]. Other studies by Singh S *et al.*^[5], Moradi J *et al.*^[21], Asif S *et al.*^[1] and Neetha MC *et al.* have not mentioned any alterations during measurements.

The examiner measured the bone levels twice on each radiograph with a gap of 20 days independently to check intraexaminer reliability from the first measurement. Blinding is usually done to minimize bias and maximize the validity of the study which is in concordance with the radiographic studies by Singh S *et al.*^[5], Moradi J *et al.*^[21]. Other studies by Asif S *et al.*^[1], Vanderberghe B *et al.*^[12] and Pecoraro ML *et al.*^[29], have two examiners/multiple examiners for reliability of measuring alveolar bone level.

In our study intraexaminer reliability for radiographic measurement showed significant positive relationship ie, good agreement, which is in agreement with the study by Asif S *et al.* ^[1] who concluded that intraexaminer reproducibility is superior to interexaminer reproducibility. Pecoraro ML *et al.* ^[29], showed no significant difference for intraexaminer reproducibility.

Before transgingival probing local anaesthesia lignocaine was administered to reduce pain, which is in concordance with the study by Savitha B *et al.* ^[5], Kholte *et al.* ^[27], Wahi S *et al.* ^[28], Kim HY *et al.* ^[24], Monali A *et al.* ^[4] and Pahwa P *et al.* ^[26].

In our study to assess alveolar bone level clinically, transgingival probing method was used. It has been shown that the bone probing measurements is closely correlated with the actual bone level⁵ measured surgically and is the most reliable method for assessing bone levels before and after any surgical procedures ^[6]. Which is in concordance with studies by Savitha B *et al.* ^[5], Kim HY *et al.* ^[24], Kolte RA *et al.* ^[27] and Wahi S *et al.* ^[28]. Monali A *et al.* ^[4] used both transgingival probing and open bone measurement. Other studies by Banodkar AB *et al.* ^[17], Li G *et al.* ^[25], Pahwa P *et al.* ^[71], and Akesson L *et al.* ^[32] used open bone measurement. Measurements for transgingival probing in our study was done using UNC 15 probe. Which is in concordance with a study by Monali A *et al.* ^[4]. It is a 15 mm long probe with millimeter markings at each millimeter and color coding at the fifth, tenth and fifteenth millimetres ^[13]. Savitha B *et al.* ^[5], Sairam V *et al.* ^[8], Moradi J *et al.* ^[2], and Wahi S *et al.* ^[27] used Williams graduated probe.

Single examiner measured both radiographic and transgingival probing measurements, and data was recorded on data collection sheet and scores were tabulated separately. Pecoraro ML *et al.* ^[29] suggest that studies evaluating alveolar bone loss on radiographs should use a single examiner to avoid interexaminer disagreement ^[29].

The data was recorded in a Microsoft excel spread sheet and statistical analysis was done using SPSSv 17.0 software Mean \pm standard deviation difference between radiographic and transgingival probing measurements in our study was 1.77 ± 0.44 mm with radiographically overestimating alveolar bone level. These results are in concordance with the study by Savitha B *et al.* ^[5] in which the mean \pm standard deviation difference was 1.75 ± 0.06 mm.

In our study statistically significant correlation was found between two methods of assessing alveolar bone level ($r=0.960$). The radiographic measurements overestimated alveolar bone level ie, underestimating bone loss which is in accordance with the studies by Savitha B *et al.* ^[5] and Sairam V *et al.* ^[8]. As there was statistically significant correlation a correction factor could be applied to estimate transgingival probing values based on radiographic values. A formula was derived based on regression for estimating transgingival probing where $y=0.9668x+2.088$ where y =Transgingival probing measurement, x =Radiographic measurement.

References

- Asif S, Nagesh KS, Waghray S, Pavankumar K, Ramana V. Comparative study of direct digital and conventional intra oral bitewing radiographs in detecting alveolar bone loss. *Journal of Oral Health Research*. 2011; 2(1):33-40.
- Pecoraro ML, Azadivatanle N, Janal M, Khocht A. Comparison of observer reliability in assessing alveolar bone height on direct digital and conventional radiographs. *Dentomaxillofacial radiology*. 2005; 34:279-284.
- Whaites E. *Essentials of Dental Radiography and Radiology* 3rd ed. Churchill livingstone, 2003, 241-252.
- Monali AS, Sneha SS, Deepak D. Dentascan-Is the investment worth the Hype???. *Journal of clinical and Diagnostic Research*. 2013; 7(12):3039-3043.
- Savitha B, Priyanka V, Hiroj B, Alka W. Bone levels – From Hypothesis to Facts. *IOSR Journal of Dental and medical sciences*. 2013; 6(5):19-23.
- Chakrapani S, Sirisha K, Srilalitha A, Srinivas M. Choice of diagnostic and therapeutic imaging in periodontics and implantology. *J Indian SocPeriodontol*. 2013; 17:711-718.
- White SC, Pharoah MJ. *Oral Radiology Principles and Interpretation*. 6th ed. St. Louis, Missouri: Mosby Publication. 2009, 248-250.
- Sairam V, Puri G. Comparison of measurements of alveolar bone levels by clinical, Bitewing and Panoramic Radiography. *Journal of Indian Academy of Oral Medicine and Radiology*. 2011; 23(4):543-547.
- Esmaeli F, Shirmohammadi A, Faramarzie M, Abolfazil N, Rouseli H, Fallahi S. Determination of vertical interproximal bone loss topography: correlation between indirect digital radiographic measurement and clinical measurement. *Iranian Journal of Radiology*. 2012; 9(20):83-87.
- Singh S, Singh K. Comparison between conventional radiography (IOPA) and digital radiography using bitewing technique in detecting the depth of alveolar bone loss. *Scholars Journal of Dental Sciences*. 2015; 2(1):63-68.
- Vasconcelos KDF, Evangelista KM, Rodrigues CD, Estrela C, Sousa TOD, Silva MAG. Detection of periodontal bone loss using cone beam CT and intraoral radiography. *Dentomaxillofacial Radiology*. 2012; 41: 64-69.
- Vanderberghe B, Corpas L, Bosmans H, Yang J, Jacobs R. A comparative *in vitro* study of image accuracy and quality for periodontal diagnosis. PART 1: The influence of X-ray generator on periodontal measurements using conventional and digital receptors. *Clin Oral Invest* 2011; 15:537-549.
- Carranza. *Textbook of clinical Periodontology*. 10th edition.
- Pilgram TK, Hildebolt CF, Yokoyama-Crothers N, Doston M, Cohen SC, Hauser JF, Kardaris E: Relationships between radiographic alveolar bone height and probing attachment level: data from healthy post-menopausal women. *J Clin Periodontol*. 2000; 27:341-346.
- Walter C, Kaner D, Berndt DC, Weiger R, Zitzman NU. Three dimensional imaging as a pre-operative tool in decision making for furcation surgery. *J Clin Periodontol*. 2009; 36:250-257.
- Parashis A, Tsiklakis K. Clinical and radiographic findings following application of enamel matrix derivative in the treatment of intrabony defects. A series of case reports. *J Clin Periodontol*. 2000; 27:705-713.
- Banodkar AB, Gaikwad RP, Gunjekar TU, Lobo TA. Evaluation of accuracy of cone beam computed tomography for measurement of periodontal defects: A clinical study. *J Indian Soc Periodontol*. 2015; 19:285-289.
- Streckfus CF, Parsell DE, Streckfus JE, Pennington W, Johnson RB. Relationship between Oral Alveolar Bone Loss and Aging among African-American and Caucasian

- individuals. *Gerontology*. 1999; 45:110-114.
19. Shah MA, Shah SS, Dave D. Dentascan: An Advent in Assessing Alveolar Bone Levels. *Journal of Clinical and Diagnostic Research*. 2013; 7(12):3039-3043.
 20. Safi Y, Kadkhodazadeh M, Safai P, Esmaeelinejad M, Shamloo N. Evaluation of alveolar crest bone loss via premolar bitewing radiographs: Presentation of a new method. *Journal of Periodontal and Implant Science*. 2014; 44:222-226.
 21. Moradi J, Poorsafar F, Khoshhal M, Vafaei F, Gholami L. A comparison of two radiographic techniques to determine the distance between alveolar bone crest and cemento-enamel junction in patients with chronic Periodontitis. *DJH*. 2010; 1(2):37-40.
 22. Neetha MC, Shashikanth MC, Kalappanavar AN, Ali IM, Shambulingappa P. *In vivo* comparison of Kodak E-speed film and direct digital imaging system for assessment of interproximal bone loss. *J Indian Acad Oral Med Radiol*. 2014; 26:34-41.
 23. Wolf B, Von Bethlenfalvy E, Hassfeld S, Staehle HJ, Eickholz P. Reliability of assessing interproximal bone loss by digital radiography: intrabony defects. *J Clin Periodontol*. 2001; 28:869-878.
 24. Kim HY, Yi SW, Choi SH, Kim CK. Bone probing measurement as a reliable evaluation of the bone level in periodontal defects. *J Periodontol* 71:729-735.
 25. Li G, Engstrom PE, Nasstrom K, Lu ZY, Sanderink G, Welander U. Marginal bone levels measured in film and digital radiographs corrected for attenuation and visual response: an *in vivo* study. *Dentomaxillofacial Radiology*. 2007; 36:7-11.
 26. Pahwa P, Lamba AK, Grewal H, Faraz F, Tandon S, Yadav N. Evaluation of two-dimensional and three-dimensional radiography with direct surgical assessment of periodontal osseous defects. *Indian Journal of Dental Research*. 2014; 25(6):783-787.
 27. Wahi S, Chhina K, Chhabra V, Bhatnagar R. Invasive versus non-invasive method of assessment of distance between the tip of papilla to the crest of interdental bone. *Eur J Gen Dent*. 2013; 2:37-41.
 28. Kolte RA, Kolte AP *et al*. Ghodpage PS. The Saudi Dental Journal. 2013; 25:153-157.
 29. Engstrom PE, Nasstrom K, Lu ZY, Sanderink G and Welander U. Marginal bone levels measured in film and digital radiographs corrected for attenuation and visual response: An *in vivo* study. *Dentomaxillofacial Radiology*. 2007; 36:7-11.
 30. Pecoraro ML, Azadivatan -le N, Janal M, Kohcht A. Comparison of observer reliability in assessing alveolar bone height on direct digital and conventional radiographs. *Dentomaxillofacial Radiology*. 2005; 34:279-284.
 31. Levin L, Levine J. Cigarette smoking and radiographic alveolar bone height and density. *NYSDJ*. 2010, 31-35.
 32. Akesson L, Hakkonson J, Rohlin P. Comparison of panoramic and intraoral radiography and pocket probing for the measurement of marginal bone level. *J Clin Periodontol*. 1992; 19:326-332.
 33. Eickholz P, Riess T, Lenhard M, Hassfeld S, Staehle HJ. Digital radiography of interproximal bone loss; validity of different filters. *J Clin Periodontol*. 1999; 26:294-300.
 34. Ferrare N, Leite AF, De souzaFigueiredo PT, Caracas HCPM, De azevedo RB, De melo NS. Cone-beam computed tomography and microtomography for alveolar bone measurements. *Surg Radiol Anat*. 2013; 35:495-502.
 35. Hausmann E, Aellen K, Celerugh V. What alveolar crest level on a bitewing radiograph represents bone loss? *J Periodontol*. 1991; 62:570-572.