



ISSN Print: 2394-7489
ISSN Online: 2394-7497
IJADS 2018; 4(3): 385-387
© 2018 IJADS
www.oraljournal.com
Received: 29-05-2018
Accepted: 30-06-2018

Mandeep Sharma
PG Student Oral Surgery
KVG Dental College and
Hospital, Karnataka, India

Maduri Palekar
PG Student Oral Surgery
KVG Dental College and
Hospital, Karnataka, India

Mareia Francis
PG Student Oral Surgery
KVG Dental College and
Hospital, Karnataka, India

Bhaskar Roy
PG Student Oral Surgery
KVG Dental College and
Hospital, Karnataka, India

Abhijit George
PG Student Oral Surgery
KVG Dental College and
Hospital, Karnataka, India

Correspondence
Mandeep Sharma
PG Student Oral Surgery
KVG Dental College and
Hospital, Karnataka, India

Extraction of permanent maxillary posterior teeth using only single buccal infiltration of 2% lidocaine

Mandeep Sharma, Maduri Palekar, Mareia Francis, Bhaskar Roy and Abhijit George

Abstract

Background & Objectives: In oral surgery procedure like extraction multiple pricks may cause painful experience many invention modern injection techniques are used, but palatal injection still remain traumatic experience for the patient due to high nerve supply and mucosal adherent to periosteum. The objective of this study is to compare the efficiency of single buccal infiltration of 2% lignocaine in maxillary premolar and molar tooth extraction.

Methodology: A study was carried on 70 patients of age group 20-60 years who required maxillary premolar and molar tooth extraction in a randomized controlled manner. Single buccal infiltration of 1.8ml of lignocaine solution was given randomly to 30 patients in maxillary premolar tooth group A and 40 patients in maxillary molar in group B. Objective signs were checked. Postoperatively VAS score and FPS score was noted.

Results: In group A (maxillary premolar) extraction was done symptoms free in 25 patients. Additional injection was required in 5 case. In group B (maxillary molar), in 40 patients extraction was done out of which in 22 patients extraction was symptoms free. Additional injection was required in 18 cases. The VAS score and FPS score values for both the groups showed a statistically significant difference (p value <0.05) between the two groups.

Interpretation & Conclusion: The single buccal infiltration of 1.8ml lignocaine with a latency period of 10 minutes can be used for extracting permanent maxillary premolar whereas maxillary molar teeth require an additional palatal injection.

Keywords: Premolar, molar, infiltration, lignocaine

Introduction

Anxiety and fear related behavior have long been recognized as significant barrier to the dental treatment [1]. The pain during administration of dental local anesthesia is found to be influenced by numerous factors. One among those site of oral cavity being injected [2]. Over all in the oral cavity most painful injection is injecting palatally. Palatal mucosal binding to its underlying periosteum and its abundant nerve complement, make injection in the palate extremely painful [3]. The pain is caused by the displacement of mucoperiosteum rather than the needle piecing the mucosa. The administration of palatal anesthesia is rated as 1st of most painful procedure in dentistry and direct experience of their procedure is considered to be most common source of fear of dental surgery [4]. Various methods have been suggested to reduce the discomfort of palate injection. They include application of topical anesthetic, pressure administration, topical cooling of palate [5], slow rate of injection, eutectic mixture of local anesthesia (EMLA) [6] and transcutaneous, electric stimulation [7]. These various methods proposed are not obviously evident and not found universally. In recent, reports have claimed that maxillary permanent teeth could be extracted by depositing local anesthesia to the buccal vestibule of the tooth without the need for palate injection. These studies evaluated the diffusion property of local anesthesia from buccal vestibular to palatal aspect. Through the available reports it is that extraction of permanent maxillary tooth is possible with single buccal injection of 2% of lidocaine without the need for palatal infection. This is important as success of technique depends on diffusion of local anesthesia from buccal vestibular to palatal cortical distance increase, diffusion ability of anesthetic solution to the palatal side will be decreased [8]. Here, the purpose of this study is to ascertain whether the extraction of permanent maxillary premolar and molar teeth can be done using a single buccal injection of lignocaine.

Aim: To evaluate the efficacy of single buccal infiltration of 2% lignocaine in extraction of maxillary premolar teeth and maxillary molar teeth.

Objectives: To assess the presence or absence of pain in buccal gingiva and palatal gingiva after infiltration using objective method. To record the subjective pain during procedure using VAS and FPS scale. To measure the duration of the anesthesia.

Methodology: A randomized study was carried on 70 patients of age group 30-40 years who required maxillary premolar teeth and maxillary molar extraction, visiting the Department of Oral and Maxillofacial surgery. Buccal infiltration of 1.8ml of anesthetic solution was given randomly to 30 patients in group A whereas same was given in 40 patients in group B. Objective signs were checked after 10 minutes.

Inclusion criteria: Patients who require maxillary premolar teeth and maxillary molar teeth extraction due to appropriate causes. Patients not having any acute periapical infections. Patients in the age group of 20-60 years. Patient of orthodontic extraction of premolar.

Exclusion criteria: Subjects with any previous history of complications associated with local anaesthetic administration. Presence of acute infection or swelling. Patients unable to give informed consent. Those with teeth showing mobility. Pregnant women and lactating mother.

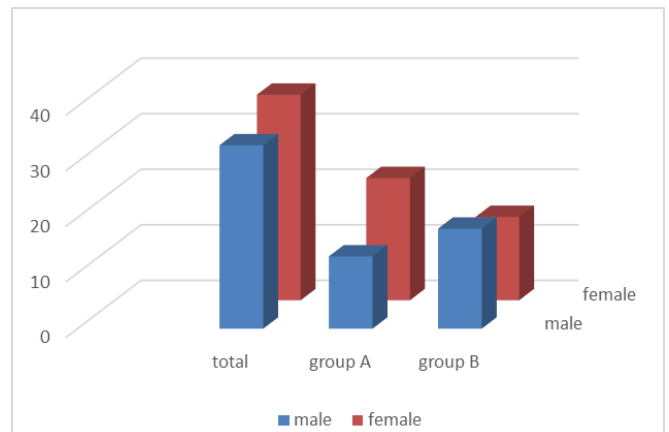
Complete history of all patients was taken. Intra oral periapical radiograph (to rule out any periapical pathology) was taken for every patient. Informed consent was taken and patient was randomly allocated to the study. Buccal infiltration along the long axis of the tooth to be extracted was given. With slow injection technique (approximately 1ml/min) and full cartridge (1.8ml of solution) was deposited. Objective signs were checked after 10 minutes and if the patient complains of pain, then additional palatal infiltration was given and was mentioned. The patients were asked to mark their pain perception after the extraction on the VAS

scale and the operator marked the pain score on the FPS. Following the surgery, the standard postoperative instructions were given to the patients along with the antibiotics and analgesics as and when required.

Results

For statistical analysis, Chi square test and Mann-Whitney Test were done and “p” value less than 0.05 was accepted as indicating statistical significance.

A total of 33 males and 37 females included in the study with 13 males and 22 females participated in group A and 18 males and 15 females participated in group B (graph 1). A mean age of 25.2 years in group A and 34.14 years in group B was found.



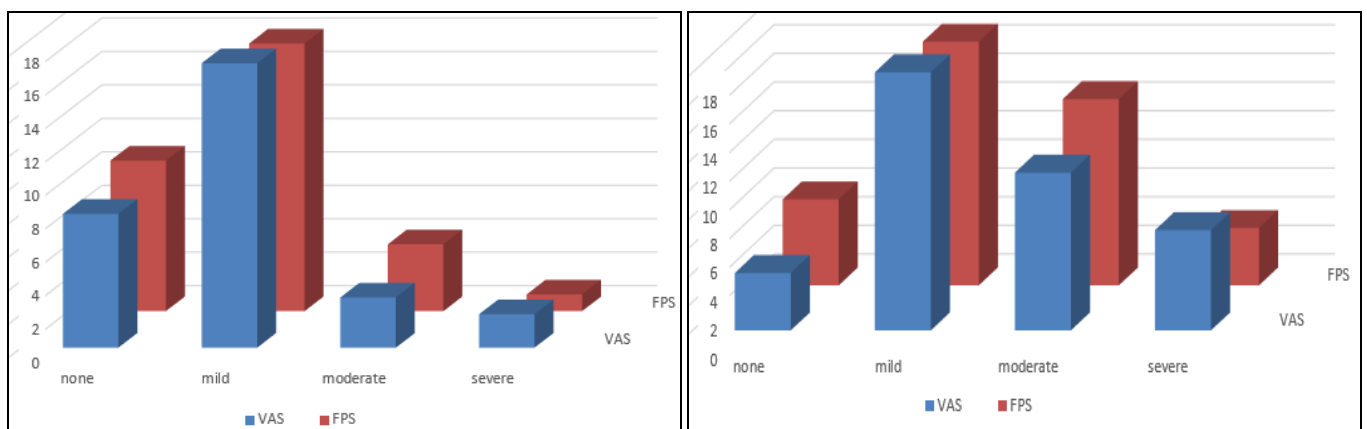
Graph 1: Distribution of sexes in the study

In group a (maxillary premolar) extraction was performed in 25 patients without the need of additional injection. However additional palatal infiltration was given in 5 cases who reported pain during palatal instrumentation. In group B (maxillary molar) 22 patient’s extraction was symptoms free. Additional injection was required in 18 cases (table 1).

Table 1

Groups	Pain on buccal instrumentation	Pain on palatal instrumentation	Extraction performed without additional injection	Additional injections required
Group A	nil	5(16.66%)	25(83.33%)	5
Group B	nil	18(45%)	22(55%)	18

The VAS score and FPS score values for both the groups showed a statistically significant difference (p value <0.05) between the two groups. (Graph 2, 3)



Graph 2-3: VAS and FPS in group A and B (graph 2- Group A and graph 3- Group B)

Mean duration of anesthesia in cases where only buccal infiltration was used was 53 ± 8.23 min

Discussions

Pain control during of any surgical procedure, it is one of the important factor. Patient's cooperation and to manage patient's anxiety use of local anesthetic agent to have rapid onset of action, sufficient duration of action, easily metabolized and the injection has to least painful. The most commonly employed anesthetic agents in lignocaine which has been the dentist first choice owing to its incomparable benefits^[9]. A standard maxillary tooth extraction using lignocaine usually requires administration of 1ml of the anesthetic in buccal vestibule region. In our study we increased the dose of buccal administration of drugs to 1.8ml. Palatal injection is the most painful of all injection in oral cavity because of the tight binding of the palatal mucous to its underlying periosteum and its abundant nervous supply^[10]. On recent study states that even that the idea infiltration of lidocaine HCL with a prolonged latency period of 8 to 10 mins could bypass the need of palatal injection^[4].

Adverse effects of lignocaine and other amide local anesthetic agents are similar in nature. Lignocaine toxicity can result when either the correct dose of lignocaine is inadvertently administered or delivered via the intravascular route, or when doses, even if given by the correct route, are excessive. Number of factors influence or directly affect the severity of lignocaine toxicity^[11]. These include the vascularity of the site of injection, speed of the injection, acid base status, and underlying hepatic or renal impairment^[9]. In our study we did not encounter any lignocaine toxicity.

Conclusion

Based on the results of our study, we can conclude that permanent maxillary premolar teeth can be extracted by giving only buccal infiltration with 2% lidocaine, but maxillary molar teeth are difficult to extract with single buccal infiltration of lidocaine according VAS and FPS which gives the moderate to severe pain in pain rating scale in the palate region while extraction.

Reference

1. Nuttall NM, Brandnock G, White D *et al.* Dental attendance in 1998 and implications for the future. *Br Dent J.* 2001; 190:177-182.
2. Kumaresan R, Srinivasan B, Pendayala S. Comparison of the effectiveness of lidocaine in permanent maxillary teeth removal performed with single buccal infiltration versus routine buccal and palatal injection. *J Maxillofac Oral Surg.* 2015; 14(2):252-7.
3. McArdle BF. Painless palatal anesthesia. *J Am Dent Assoc.* 1997; 128:647.
4. Sekhar GR, Nagaraju T, Kolligiri Nandagopal V, Sudheer R Sravan. Is palatal injection mandatory prior to extraction of permanent maxillary tooth: A preliminary study. *Indian J Dent Res.* 2011; 22(1):100-2.
5. Harbert H. Topical ice: Precursor to palatal injections. *J Endod.* 1989; 15:27-8.
6. Stoltz P, Manworren RCB. Comparison of Children's Venipuncture Fear and Pain: Randomized Controlled Trial of EMLA® and J-Tip Needleless Injection System®. *J Pediatr Nurs.* 2017; 37:91-96.
7. Meechan JG. Effective topical anesthetic agents and techniques. *Dent Clin N Am.* 2002; 46(4):759-766.
8. Rajasekhar G, Nagaraju T, Kolligiri Nandagopal V *et al.*

- Is palatal injection mandatory prior to extraction of permanent maxillary tooth: a preliminary study. *Indian J Dent Res.* 2011; 22:100-102.
9. Malamed So handbook of local anaesthesia, 4th ed.st. louis, Mosley, 1997.
10. S Uckan, E Dayangac, K Araz. Is permanent maxillary tooth removal without palatal injection possible? *Oral Surg Oral Med Oral Pathol Oral Radiol Endod.* 2006; 102:733.
11. Sharma K, Sharma A, Aseri M, Batta A, Singh V, Pilonia D, *et al.* Maxillary posterior teeth removal without palatal injection -truth or myth: a dilemma for oral surgeons. *J Clin Diagn Res.* 2014; 8(11):ZC01-4.