



ISSN Print: 2394-7489  
ISSN Online: 2394-7497  
IJADS 2018; 4(4): 22-24  
© 2018 IJADS  
www.oraljournal.com  
Received: 04-05-2018  
Accepted: 06-06-2018

**Dr. Rahul VC Tiwari**  
FOGS, MDS, OMFS &  
Dentistry, JMMCH & RI,  
Thrissur, Kerala, India

**Dr. Philip Mathew**  
HOD, OMFS & Dentistry,  
JMMCH & RI, Thrissur, Kerala,  
India

**Dr. Yasmin Jose**  
Clinical Observer, MDS, OMFS &  
Dentistry, JMMCH & RI,  
Thrissur, Kerala, India

**Dr. Heena Tiwari**  
BDS, PGDHHM, Government  
Dental Surgeon, CHC Makdi,  
Kondagaon, C.G. India

**Dr. Jisha David**  
Registrar, Dept of Dentistry,  
JMMCH & RI, Thrissur, Kerala,  
India

**Correspondence**

**Dr. Rahul VC Tiwari**  
FOGS, MDS, OMFS &  
Dentistry, JMMCH & RI,  
Thrissur, Kerala, India

## **Kissing Canines: Impacted & Migrated: Case Report**

**Dr. Rahul VC Tiwari, Dr. Philip Mathew, Dr. Yasmin Jose, Dr. Heena Tiwari and Dr. Jisha David**

### **Abstract**

Transmigration is a rare phenomenon seen almost exclusively in the mandibular canines. Canine is one of the most commonly impacted teeth in the dental arch. An unerupted permanent canine crossing the midline is called transmigration and is an unusual event. We report nine cases of impacted canine transmigration. Maxillary canine transmigration, bilateral transmigration, and transmigration associated with odontoma are rare presentations. Mandibular canines are “cornerstone” of dental arch; their importance is manifested by their efficiency in masticatory function, stability of dental arch, and aid in maintaining natural facial expression. Early detection of this anomaly can help preserving these canines by orthodontic intervention or by surgical transplantation. This developmental anomaly is properly diagnosed by radiographic evaluation, which is primarily based on the panoramic radiograph. In patients with over retained deciduous canines or missing permanent canines, an intraoral radiograph should be supplemented with panoramic radiograph. This case report discusses about the impacted and migrated canines in a kissing position and also shows a case of impacted canines if untreated forms a lesion.

**Keywords:** Impaction, Migration, Mandibular canines, Kissing Tooth

### **1. Introduction**

Transmigration is a rare phenomenon that typically affects the mandibular canines. There is no known etiology for its occurrence, however, there are many and varied etiological factors involved in transmigrated teeth, such as ectopic growth of the tooth bud, retention or premature loss of a primary tooth, inadequate eruption space and excessive length of crown. Genetic factors, endocrine disorders and trauma have also been also proposed as etiological factors<sup>[1, 2]</sup>. Dental transmigration is almost exclusively reported in mandibular canines. The incidence for this phenomenon has been reported to be ranging from 0.8–3.6% to 0.1%.<sup>[3, 4]</sup> Kara *et al.*<sup>[5]</sup> studied the prevalence of transmigration of various mandibular teeth and reported an incidence of 0.079% for mandibular canines, 0.0017% trans migrant lateral teeth and 0.0026% trans migrant premolars. Mupparapu classified transmigrated mandibular canines into five types:<sup>[6]</sup>

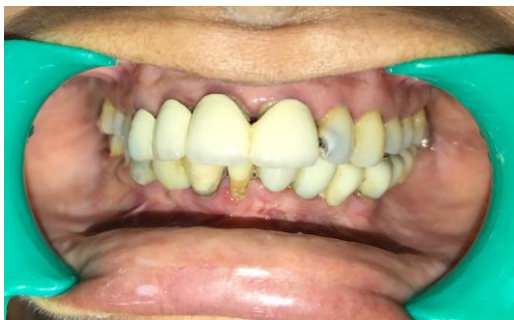- Type 1: Canine impacted mesioangularly across the midline, labial, or lingual to the anterior teeth with crown portion of tooth crossing the midline.
- Type 2: Canine horizontally impacted near the inferior border of the mandible below the apices of the incisors.
- Type 3: Canine erupted either mesial or distal to the opposite canine.
- Type 4: Canine horizontally impacted near the inferior border of the mandible below the apices of the premolar or molar on the opposite side.
- Type 5: Canine positioned vertically in the middle with the long axis of the tooth crossing the midline.

The incidence of these types varies with Type 1 (45.6%) being the most common, followed by Type 2 (20%), Type 4 (17%), Type 3 (14%), and Type 5 (1.5%). Transmigrated teeth are typically asymptomatic diagnosed on routine panoramic radiography taken for evaluation of missing permanent canines or retained deciduous canines. However, if symptomatic they can cause pressure resorption of roots or tilting of adjacent teeth and even pain and neuralgic symptoms.<sup>[4]</sup> Therefore, their timely diagnosis is utmost important. We discuss a case of kissing impacted canine and also shows an OPG with a lesion involving such type if undiagnosed and untreated initially. Surgical extraction appears to be the most favored treatment for migrated canines, rather than a heroic effort to bring the tooth back to its original

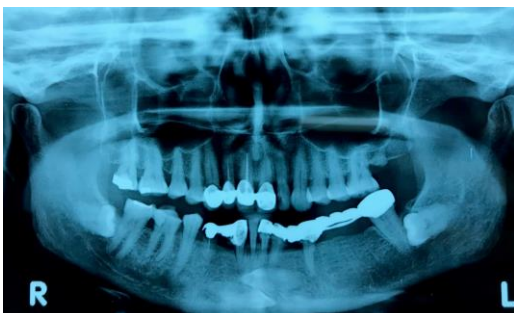place. This is especially true when the mandibular arch is crowded and requires therapeutic extractions to correct the incisor crowding. Thoma stated that transmigrated canines usually have to be removed [7]. Fiedler and Alling also recommend the extraction of transmigrated canines [8]. The adjustment of displaced mandibular canines, Although biomechanically possible, as they consist of mostly necessary pronounced tooth movement, and the narrow jaw width leads for iatrogenic damage to adjacent teeth or poor periodontal conditions. Moreover, since the canines are very often strongly shifted, the orthodontic adjustment is only indicated in exceptional cases. In cases with impacted mandibular canines, the therapy is limited mostly to the extraction of the impacted tooth.

### Case Report

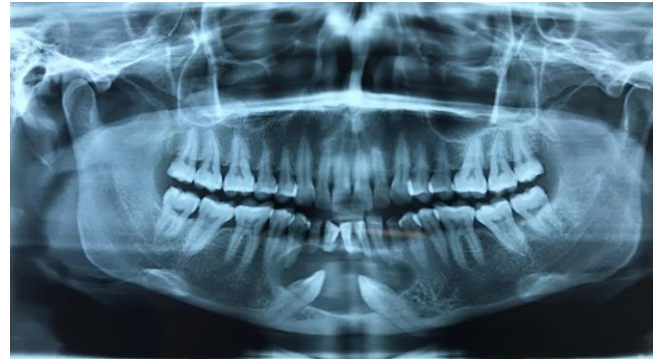A 58-year-old female presented with pain in lower front teeth for one year. Intraoral examination revealed partially edentulous jaw and prosthesis with anterior and posterior teeth, clinically missing permanent mandibular bilateral canine and last molar. Generalized periodontitis was present. (Figure 1) A panoramic radiograph was requested, which revealed impacted and migrates mandibular canines almost in a kissing position in midline and horizontally bilateral impacted last molars. (Figure 2). The radiographic position of the tooth was in accordance with the classification given by Mupparapu for mandibular canine transmigration. No pathologic finding was associated with the transmigrated tooth. Surgical removal of the canine was decided. However, the patient declined the surgical intervention as the tooth was asymptomatic. Patient was informed of the consequence and was scheduled for periodic monitoring. One another case of middle-aged female with same complaint revealed a lesion in relation with the impacted canine. (Figure 3) She informed that surgical removal was informed a year back when she had the same complaint but she didn't turn up for the procedure and it led to this stage when she noticed a swelling with the same lesion. Surgical removal with excision of lesion was done.



**Fig 1:** Intraoral photograph of the patient



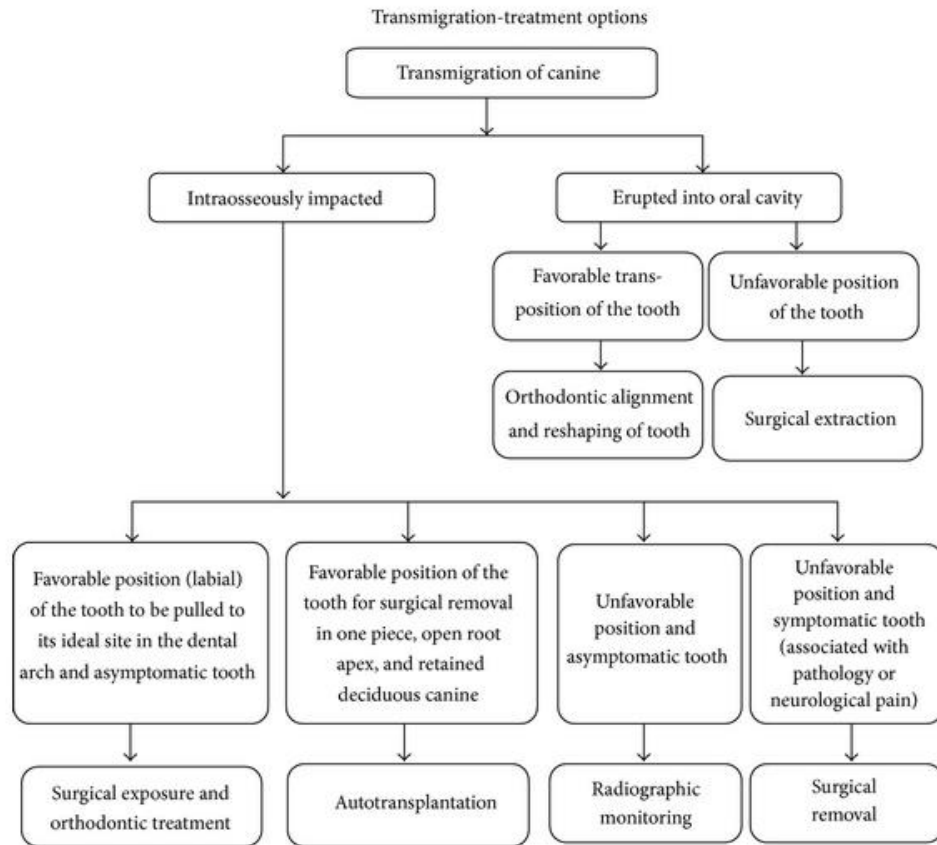
**Fig 2:** OPG showing Kissing Canine



**Fig 3:** OPG showing lesion with Canine

### Discussion

Mandibular canine impaction is uncommon as compared to the maxillary canine. However, transmigration is more commonly exhibited by mandibular canines. [4, 6] This can be attributed to the conical crown, the long root of canine and greater cross-sectional area of the symphysis. [9] Transmigration is usually considered a rare phenomenon with a prevalence of only 0.31% [6] and generally unilateral transmigration is seen. Bilateral transmigration is very rare with an incidence of only 9% [4] and we report three such cases with different presentations. Transmigration is found more frequently in females and on the left side. [6] Multiple etiologies have been proposed. Abnormal displacement of tooth bud during development is the most accepted one [4, 6] Pippi and Kaitas [10] proposed that the simultaneous presence of strong eruptive force during root formation and enlarged follicular space creates an osteolytic area which offers less resistance to tooth movement. Other contributing factors include premature loss or over-retained deciduous teeth, crowding, spacing, unfavorable arch length, trauma, tumor, odontomas, and cyst, [10, 11] all of which alters the guide for the path of eruption. It has been proposed that transmigration should include only those cases in which more than half of the tooth had crossed the midline. [11] However, the tendency to cross the midline is more important as the distance migrated can vary with the stage of diagnosis. [4] Transmigrated canines are usually asymptomatic and discovered on routine panoramic radiograph taken for orthodontic purposes. They can sometimes be associated with pain and discomfort, swelling or paresthesia due to impingement of mandibular canal. [4, 9] Various management and diagnostic options are present for decision making in such cases. (Figure 4) Management of transmigration mainly involves surgical extraction. [12] In asymptomatic patients with no pathological changes, surgical extraction can be deferred, and the patient can be put on periodic follow up. In case of orthodontic treatment, erupted transmigrated canine should be extracted instead of the usual premolars to prevent excessive treatment time. Surgical exposure with orthodontic realignment can be attempted for the labially placed canine in non-extraction cases when the crown has not migrated past the adjacent lateral incisor. [12] Surgical repositioning and transplantation when enough space is available are other treatment options. If the canine has ectopically erupted into the oral cavity, then orthodontic realignment and recontouring of a crown can be attempted [11, 12]



**Fig 4:** Flowchart depicting the various treatment options to aid in decision making for the management of canine transmigration.

### Conclusion

Canines are considered to be the cornerstones of the dental arch. They play an essential role in maintaining the facial harmony and functional efficiency. The unerupted or transmigratory canines are generally asymptomatic. Radiographic examination is essential to diagnose impacted canines and panoramic radiographs are generally required to diagnose transmigrated canines. Timely detection and treatment can help to preserve these canines, surrounding tissues and dentition, resulting in better esthetic and function.

**Financial Support and Sponsorship:** Nil.

**Conflicts of Interest:** There are no conflicts of interest.

### References

- Bishara SE. Impacted Maxillary Canines: A Review. *American J Orthodont Dentofac Orthoped.* 1992; 101(2):159-71
- Adrian Becker, *Orthodontic Treatment of Impacted Teeth*, 3rd Edition, April 2012, Wiley-Blackwell.
- Javid B. Transmigration of impacted mandibular cuspids. *Int J Oral Surg.* 1985; 14:547-9.
- Joshi MR. Transmigrant mandibular canines: A record of 28 cases and a retrospective review of the literature. *Angle Orthod* 2001; 71:12-22.
- Kara MI, Ay S, Aktan AM, Sener I, Bereket C, Ezirganli S, *et al.* Analysis of different type of transmigrant mandibular teeth. *Med Oral Patol Oral Cir Bucal.* 2011; 16:e335-40.
- Mupparapu M. Patterns of intraosseous transmigration and ectopic eruption of mandibular canines: Review of literature and report of nine additional cases. *Dentomaxillofac Radiol.* 2002; 31:355-60.
- Thoma KH. *Oral Surgery* 4 th ed., CV Mosby, St Louis, (as quoted) 1963, 273
- Fiedler LD, Alling CC. Malpositioned Mandibular Canine: Report of a Case. *J Oral Surg* 1968; 26(6):405-407.
- Auluck A, Nagpal A, Setty S, Pai KM, Sunny J. Transmigration of impacted mandibular canines – A report of four cases. *J Can Dent Assoc.* 2006; 72:249-52.
- Pippi R, Kaitsas R. Mandibular canine transmigration: Aetiopathogenetic aspects and six new reported cases. *Oral Surg* 2008; 1:78-83.
- Kumar S, Urala AS, Kamath AT, Jayaswal P, Valiathan A. Unusual intraosseous transmigration of impacted tooth. *Imaging Sci Dent* 2012; 42:47-54.
- Wertz RA. Treatment of transmigrated mandibular canines. *Am J Orthod Dentofacial Orthop.* 1994; 106:419-27.