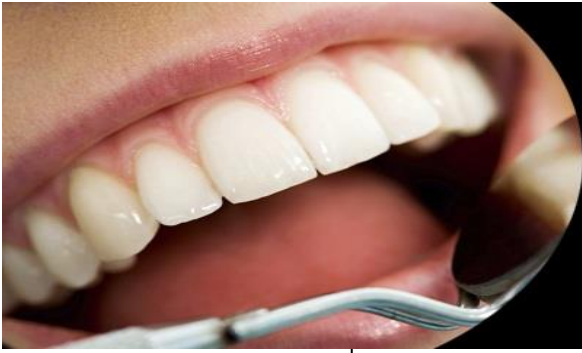



International Journal of Applied Dental Sciences

ISSN Print: 2394-7489
ISSN Online: 2394-7497
IJADS 2018; 4(4): 237-239
© 2018 IJADS
www.oraljournal.com
Received: 25-08-2018
Accepted: 27-09-2018

Falak Naz
Resident, Department of
Prosthodontics, Crown & Bridge,
Government Dental College and
Hospital, Srinagar, Jammu &
Kashmir, India

Jawahir Ahmad Ganai
Resident, Department of
Periodontics, Government
Dental College and Hospital,
Srinagar, Jammu & Kashmir,
India

Sandeep Kaur Bali
Professor and Head, Department
of Prosthodontics, Crown &
Bridge, Government Dental
College and Hospital, Srinagar,
Jammu & Kashmir, India

Correspondence

Falak Naz
Resident, Department of
Prosthodontics, Crown & Bridge,
Government Dental College and
Hospital, Srinagar, Jammu &
Kashmir, India

Exploring the relationship of incisive papilla with maxillary canines in Kashmiri population: An original research

Falak Naz, Jawahir Ahmad Ganai and Sandeep Kaur Bali

Abstract

The dental profession has a huge responsibility to deliver aesthetic complete denture prosthesis for which proper positioning of artificial teeth is must. Positions of denture teeth are best determined using pre-extraction records, but most persons who seek complete denture construction in Kashmir do not have these records. In such situations, anatomic landmarks are frequently valuable in determining the positions of prosthetic teeth, the most common one being the incisive papilla. This study sought to describe the relationship between the incisive papilla and the maxillary canine teeth among Kashmiri population. Maxillary impressions were made in 100 dental students in Government Dental college and hospital, Srinagar, Kashmir. Casts were made and standardized to the horizontal plane. Photographic technique was used to determine the relationship between incisive papilla and inter-canine line on dental casts. The area on the incisive papilla where the inter-canine distance passed was noted. The results showed that the inter-canine line passed through the Middle third of incisive papilla in 52% of the total subjects. Gender had no significant effect on the relationship of the incisive papilla to the maxillary canine teeth. These results suggested that there is a relationship between the incisive papilla and maxillary canines aiding in their proper positioning. The clinical relevance of this study lies in application of incisive papilla as a starting point in the preliminary location of maxillary canine teeth during construction of dentures.

Keywords: Maxillary canine teeth, incisive papilla, photographic technique, Kashmiri population

Introduction

Edentulism is a serious emotional life event that is associated with challenges in mastication, poor facial aesthetics and difficulty in articulation of certain sounds. These problems usually cause the edentulous person to seek replacement for the lost teeth ^[1]. One of the most commonly used treatment options for such patients are the complete dentures. During construction of complete dentures, teeth arrangement is a very critical stage. It is more critical in the aesthetic zone, since complete denture aesthetics is a key in patient satisfaction ^[2-6]. Apart from the aesthetic value, maxillary anterior teeth are equally important for correct speech, lip support and to provide a harmonious Incisal guidance ^[7]. To achieve this the upper anterior teeth should be positioned as close as possible to the positions originally occupied by the natural teeth ^[8, 9].

Among the anterior teeth maxillary canines are considered extremely important for cosmetic appearance. Wheeler ^[10] described canines as “a foundation that insures normal facial expression.” So, it becomes extremely important for a Prosthodontist to place such teeth in their correct positions. An easy method of finding the correct position of teeth are the pre-extraction records. However, most persons who seek complete denture care in Kashmir do not have pre-extraction records. In such situations, biometric guides have been recommended for determination of prosthetic tooth positions ^[11]. One of the most commonly used biometric guides in determining the positions of the maxillary canines is the incisive papilla. The incisive papilla has been described as a stable landmark that remains relatively unchanged after anterior tooth extraction and subsequent resorption of the maxillary ridge ^[12]. Different researchers have studied the relationship between the maxillary canines and incisive papilla. H Watt *et al.* ^[13] suggested that the canines should be located in a coronal plane passing through the posterior border of the papilla. Mavroskoufis and Ritchie ^[8] recommended that the tips of the canines should be set on a horizontal line which pass through the posterior border of

incisive papilla. Since then several authors have studied the canine-papilla relationship in the dentulous persons and have suggested various norms to place the maxillary canines in complete denture [14-27]. However, these previous studies for the determination of relationship between incisive papilla and canines have been done in other population groups and no such study has been done in Kashmiri population. Since, there is a variation in anatomy and general body structure between the various ethnic groups, such variation should be considered when applying biometric guides to complete denture construction. Hence this study was conducted to determine the relationship between incisive papilla and maxillary canines in Kashmiri population which will serve as a guide for evaluating the position of canine teeth in edentulous patients during complete denture fabrication.

Linear measurement between two objects in a three-dimensional relationship imposes problems when the objects are not aligned on the same plane in three dimensions [9]. To reduce this error, a photographic technique was developed and used in this study.

Materials and methods

This study was conducted on 100 dentate subjects (50 males and 50 females) in the age range of 18 to 25 years, selected from a group of approximately 200 under-graduate students from Government Dental College Srinagar, Kashmir. Subjects with well aligned maxillary arches, Angles class 1 molar relation with no surface loss on maxillary anterior teeth were included in the study. Subjects with history of orthodontic treatment, crowding in the maxillary anterior segment, evidence of drifting and/or migration in the maxillary anterior segment, any proximal restorations in the maxillary anterior segment, tooth surface loss in the maxillary anterior segment and those with any developmental defect or acquired pathology affecting the anterior maxilla were excluded from the study. The students were interviewed to establish that they were of Kashmiri descent. Informed consent was obtained from the participants before they enrolled in the study. Clearance from Institutional Ethical Committee was obtained. On each subject, Impression of the maxillary arch was made using irreversible hydrocolloid and casts were poured using Type III Dental stone. Cast was trimmed to produce a flat

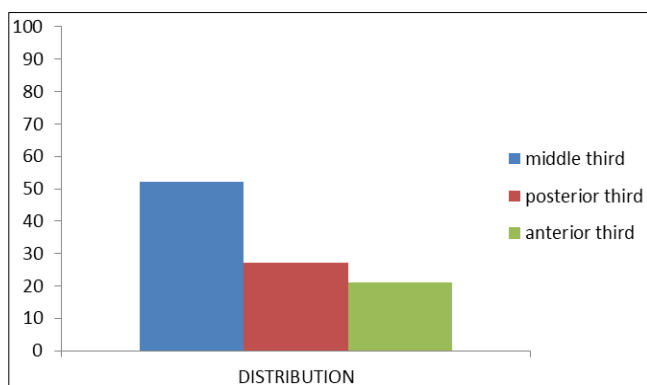
base and then inverted so that the central incisors and the first molars were in contact with a piece of 3 mm thick T-shaped polyvinyl chloride (PVC) sheeting [14]. A horizontal line was scraped on the side of the base of the model with the tip of a pointer, which was 33 mm from the top of the table. The base of the cast was trimmed to the scraped line. The casts thus produced were standardized with the occlusal plane parallel to the horizontal plane when placed on a flat horizontal surface. Each cast was trimmed following the same procedure. The tip of the canine was marked using a marker pen with a fine point (1.0mm tip diameter). In cases where the tip of the canine exhibited wear as a result of attrition, its original position was estimated by joining a line along the mesial and distal cutting edge and a line along the buccal and lingual long axis of the tooth. The point of interception of the two lines would be the estimated canine cusp tip [14]. Photograph of each cast was taken to mark the inter-canine line and to find the relationship between the incisive papilla and the inter-canine line. Acetate tracing paper was placed on top of the photographs. The outline of the incisive papilla, the cusp tip of the right canine and the cusp tip of the left canine were marked on the tracing paper. Incisive papilla was divided into three parts, anterior third, middle third, and posterior third. The tip of canine on both sides and the line connecting these two points on the photograph was designated as Inter-canine line. The relationship of the incisive papilla to the inter-canine line was observed in the photograph. When the position of incisive papilla coincided with the inter-canine line it was defined as Canine-Papilla-Canine (C-P-C line) The point where inter-canine line crosses the papilla was noted.

Results

Results of our study showed that of the inter-canine lines, 52% passed through the middle third, 21% through the anterior third, and 27% through the posterior third. In the male subjects 20% of the inter-canine lines passed through the anterior third, 54% passed through the middle third, and 26% passed through the posterior third, whereas in the female subjects 22% passed through the anterior third, 50% passed through the middle third, and 28% passed through the posterior third. (Table 1, Graph 1). Intergender variation seemed to be insignificant.

Table 1: Percentage distribution of canine papilla line in males and females

Canine papilla line	No. of males	No. of females	Total(%age)
Anterior third	10	11	21%
Middle third	27	25	52%
Posterior third	13	14	27%
	50	50	100



Graph 1

Discussion

The facial structures of edentulous patients offer only indirect clues as to the original position of the natural teeth. Finding the most suitable position for artificial anterior teeth presents a new challenge with every denture and has resulted in a variety of biometric measurements. Many of these measurements relate the denture teeth to points on edentulous casts. The most obvious landmark that appears to have survived intact from the dentate state is the incisive papilla, and it has received a great deal of attention [15]. As early as 1948 Harper stated “When artificial teeth are set in proper position, which may be determined by the incisive papilla, the foundation is correctly laid for natural speech, pleasing appearance and normal function [12]. The canine-papilla line is a useful guide to orient the upper canine teeth in complete

dentures. The significance of the relationship between the maxillary anterior teeth and the incisive papilla in prosthetic dentistry is that it provides a guide for the setting of artificial teeth in the construction of dentures, especially complete dentures. Therefore it is important to orient the dental casts in a standardized manner during measurements so that the results achieved can be applied when artificial teeth are being set in complete denture bases. Thus the orientation of the casts was standardized by defining the occlusal plane, which is formed by the most incisal points of the central incisors and the most occlusal points of the left and right first molars (which are usually on the tips of the palatal cusps). This orientation was chosen because it is more comparable to the complete denture situation^[14].

In this study the inter-canine line was used rather than the line joining the most distal point of the canines as was used by Grove and Christensen^[16], because the most distal point of the canines was not found to be any easier to locate than the tip of the canines. In our study the inter-canine line passed through the middle third of the incisive papilla in 52% of subjects. Our results were very close to the study conducted by Suraksha *et al.*^[17] who found that the inter-canine line passed through the middle third of papilla in 52.6% of the subjects. It was also closely matched to that of Ehrlich and Gazit^[18], who found that 57.6% of the inter-canine lines passed through the center of the papilla. Results were comparable to the results of Sawiris' study^[19] in which 64% of the inter-canine lines were found to pass by +1 mm from the center of the papilla. Similar results were found by studies conducted by Mavroskoufis and Ritchie^[8], lau & clark^[14], Solomon *et al.*^[20] & Khalaf HA^[21].

Conclusion

Incisive papilla is a useful anatomical landmark to locate the position of maxillary canine teeth in complete denture construction. Our study concluded that the intercanine line passes through the middle third of incisive papilla in 52% of dentate kashmiri population. This would serve as an important guide during anterior teeth arrangement in complete denture fabrication. However clinicians must base their judgements on the basis of biometric guides and other functional methods as well like phonetic tests so as to achieve an esthetically pleasing result.

References

1. Suominen-Taipale AL, Alanen P, Helenius H *et al.* Edentulism among Finnish adults of working age, 1978-1997. *Community Dentistry and Oral Epidemiology*. 1999; 27(5):353-365.
2. Carlsson G, Otterland A, Wennstro A. Patient factors in appreciation of complete dentures. *J Prosthet Dent*. 1967; 17(4):322-328.
3. Vallittu P, Vallittu A, Lassila V. Dental aesthetics-a survey of attitudes in different groups of patients. *Journal of Dentistry*. 1996; 24(5):335-338.
4. Brewer A. Selection of denture teeth for esthetics and function. *The Journal of Prosthetic Dentistry*. 1970; 23(4):368-373.
5. Hirsch B, Levin B, Tiber N. Effects of patient involvement and esthetic preference on denture acceptance. *J Prosthet Dent*. 1972; 28(2):127-132.
6. Lefer L, Pleasure MA, Rosenthal L. A psychiatric approach to the denture patient. *Journal of Psychosomatic Research*. 1962; 6(3):199-207.
7. Frush P, Fisher R. Age factor in dentogenics. *J Prosthet Dent*. 1957; 7(1):5-13.
8. Mvroskoufis F, Ritchie GM. Nasal width and incisive papilla as guides for the selection and arrangement of maxillary anterior teeth. *J Prosthet Dent*. 1981; 45:592.
9. Harold R, Ortman D, Ding H, Taso D. Relationship of the incisive papilla to the maxillary central incisors. *J Prosthet Dent*. 1979; 42:492-496.
10. Wheeler RC. *Textbook of dental anatomy and physiology*. Philadelphia: WB Saunders, 1940.
11. Al Wazzan KA. The relationship between intercanthal dimension and the widths of maxillary anterior teeth. *J Prosthet Dent*. 2001; 86(6):608-612.
12. Harper RN. The Incisive Papilla The Basis of a Technic to Reproduce the Positions of Key Teeth in Prosthodontia. *Journal of Dental Research*. 1948; 27(6):661-668.
13. Watt DM. Morphological changes in the denture bearing area following the extraction of maxillary teeth. *British dental journal*. 1974; 136:231-235.
14. Lau GC, Clark RF. The relationship of incisive papilla to the maxillary central incisors and canine teeth in southern Chinese. *J Prosthet Dent*. 1993; 70:86-96.
15. Grave AM, Becker PJ. Evaluation of incisive papilla as a guide to anterior tooth position. *J Prosthet Dent*. 1987; 22:113-119.
16. Grove HR, Christensen LV. Relationship of maxillary canines to the incisive papilla. *J Prosthet Dent*. 1989; 42:492-496.
17. Shrestha S, Joshi SP, Yadav SK. Relationship of incisive papilla to maxillary incisors and canines. *Journal of contemporary dental practice*. 2016; 17(4):306-312.
18. Erlich J, Gazit E. Relationship of maxillary central incisors and canines to the incisive papilla. *J Oral Rehabil*. 1975; 2:309-312.
19. Sawiris MM. The role of anthropometric measurements in the design of complete denture construction. *J Dent*. 1977; 5:141-148.
20. Solomon EGR, Arunachalam KSJ. The Incisive Papilla: A Significant Landmark in Prosthodontics *Journal of Indian Prosthodont Soc*. 2012; 12(4):236-247.
21. Khalaf HA. Evaluation of the incisive papilla as a guide to the maxillary central incisors and canine teeth position in Iraqi and Yemenian samples *J Fac Med Baghdad*. 2009; 51(2):146-150.
22. Schiffman P. Relation of the maxillary canines to the incisive papilla. *J Prosthet Dent*. 1964; 14:469-472.
23. Abd Al-hadi L. Relationship between the incisal papilla and the anterior teeth in dentate patients. *Chir Dent Fr*. 1990; 530:53-56.
24. Bengakul C. Relation of maxillary canines to incisive papilla. *J Dent Assoc Thai*. 1983; 33:178-179.
25. Young-Seok P, Seung PL, Ki-Suk P. The three dimensional relationship on a virtual model between the maxillary anterior teeth and incisive papilla. *J Prosthet Dent*. 2007; 98:312-318.
26. Amin WM, Sandra K, Ghazawi A. The relationships of the maxillary central incisors and canines to the incisive papilla in Jordanians. *J Contemp Dent Pract*. 2008; 9:1-18.
27. Fabiana MV, Sergio SN, Joao NA. The center of the incisive papilla for the selection of complete denture maxillary anterior teeth in 4 racial groups. *Quintessence Int*. 2008; 39:841-845.