



ISSN Print: 2394-7489  
ISSN Online: 2394-7497  
IJADS 2018; 4(4): 289-291  
© 2018 IJADS  
www.oraljournal.com  
Received: 11-08-2018  
Accepted: 15-09-2018

**Dr. Venkat Raghu**  
Post-Graduate Student, AECS  
Maaruti College of Dental  
Sciences and Research Center,  
Bangalore, Karnataka, India

**Dr. Kondumahanti VN Avinash**  
Post-Graduate Student, AECS  
Maaruti College of Dental  
Sciences and Research Center,  
Bangalore, Karnataka, India

**Dr. Ajna Alex**  
Post-Graduate Student, AECS  
Maaruti College of Dental  
Sciences and Research Center,  
Bangalore, Karnataka, India

**Dr. Kondumahanti Venkata Sai  
Prasanth**  
St. Joseph Dental College, Eluru,  
Andhra Pradesh, India

**Dr Subash Munireddy**  
Professor, AECS Maaruti College  
of Dental Sciences and Research  
Center, Bangalore, Karnataka,  
India

#### Correspondence

**Dr. Venkat Raghu**  
Post-Graduate Student, AECS  
Maaruti College of Dental  
Sciences and Research Center,  
Bangalore, Karnataka, India

## Modified technique for the management of the difficulties in recording denture bearing areas with flabby tissues: A technique presentation

**Dr. Venkat Raghu, Dr. Kondumahanti VN Avinash, Dr. Ajna Alex, Dr. Kondumahanti Venkata Sai Prasanth and Dr. Subash Munireddy**

#### Abstract

The unsupported tissues in the denture bearing area often pose potential problem of turning the complete denture treatment into a failure. A proper Impression technique is required to overcome such situations. Zafrulla Khan has described one such technique of taking impressions in such scenarios. In the present technique presentation we described the modification of the originally proposed technique with addition silicone.

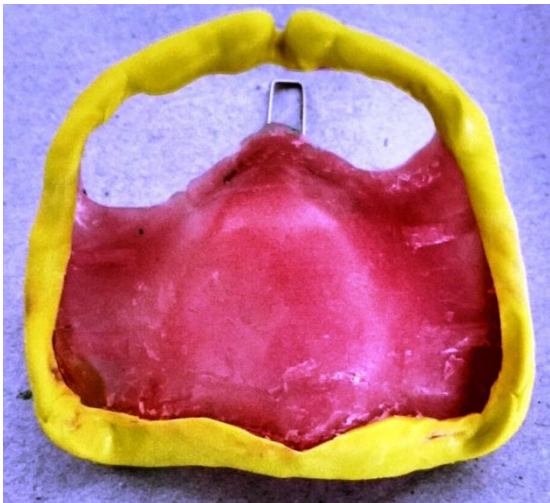**Keywords:** complete denture; impression techniques; addition silicone

#### Introduction

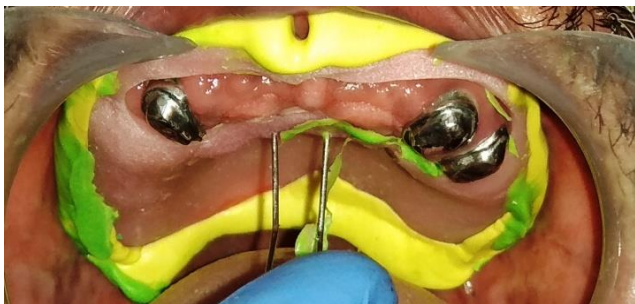
The success of a complete denture often depends on basic principles of impression making. An impression should have maximum coverage of supporting area, peripheral seal without interference with functional movements and accurate adaptation to the tissues without injurious displacement<sup>[1]</sup>. However, these requirements are difficult to achieve when the quality of the denture-bearing areas are not suitable. Flabby ridge that causes pain or looseness relating to a complete denture that rests on them is one such situation. A fibrous or flabby ridge is a superficial area of hyperplastic soft tissue affecting maxillary or mandibular alveolar ridges. It is a common finding particularly in the upper anterior region of long-term denture wearers. It is been seen in 24% of edentulous maxillae and 5% edentulous mandibles<sup>[2]</sup>. These mobile denture-bearing tissues can be displaced when subjected to masticatory forces which eventually leading to loss of peripheral seal. Pressure exerted during impression making can result in distortion of the mobile tissue<sup>[1]</sup>. When hyperplastic tissue replaces the bone, a flabby ridge develops which is often seen in long-term denture wearers and clearly related to the degree of residual ridge resorption. Although surgical excision techniques or use of dental implants has provided clinicians with methods of addressing this particular difficulty, they are not suitable in all conditions.<sup>[3]</sup> Therefore, this article tries to discuss an impression technique for fabrication of a retentive and stabilized denture for cases of complete edentulism with flabby ridges, through palliative approach

#### Technique Presentation

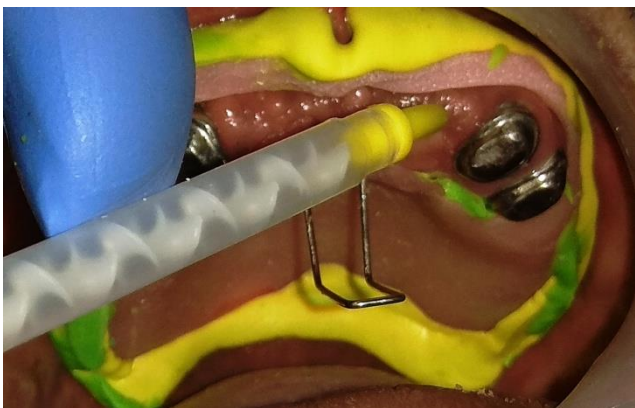*Modified Zafrulla Khan's Window technique:* 4 commonly used technique in impression making of flabby tissue, which was originally described by Zafrulla Khan, requires a custom tray with wax spacer that was fabricated from the primary cast. The unsupported movable tissue was marked using an indelible pencil. A window is cut in the custom tray which corresponding to that area. (Fig-1) After border molding Addition Silicone Light body impression was made. Any impression material which has escaped through the window of the tray was trimmed. The impression was checked for its completeness. Reseat the impression (Fig-2) and Light Body Impression material in Cartridge (Fig-3) was applied over the exposed flabby tissue using the light body dispensing gun. (Fig-4) The tray was held in position till the material sets. (Fig-5) The impression tray was removed from the mouth and checked for any voids (Fig- 6).



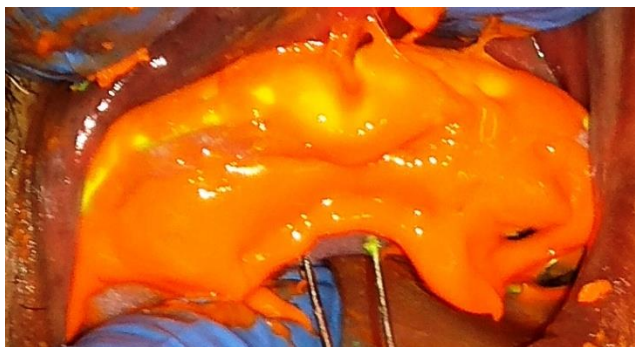
**Fig 1:** Completed border moulding on a special tray with window corresponding the flabby tissue.



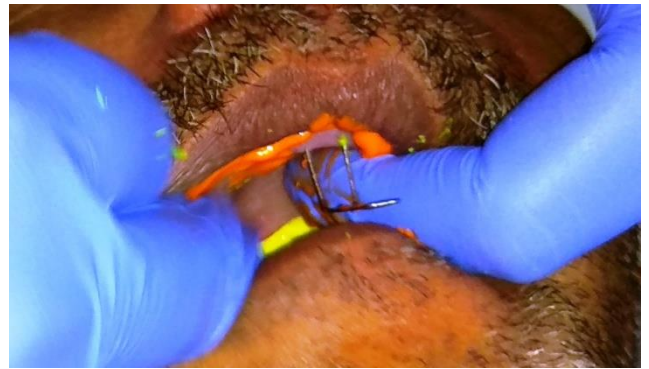**Fig 2:** Reseating the tray



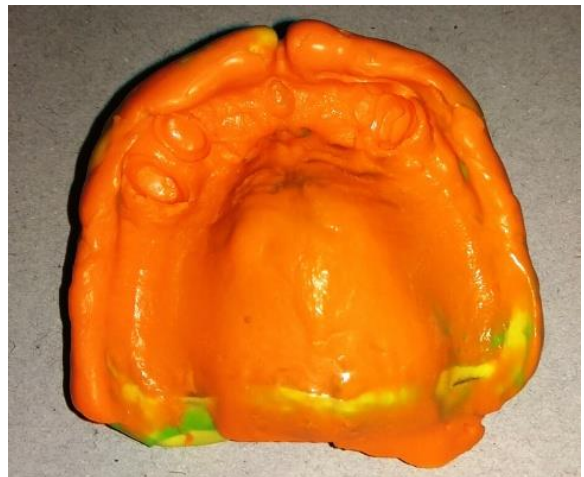**Fig 3:** Injecting the light body impression material



**Fig 4:** Applying the light body impression material on the flabby tissue



**Fig 5:** holding the tray till the material sets



**Fig 6:** completed impression

### Discussion

Flabby ridges can be managed by surgical treatment followed by prosthetic procedures. Surgical excision is favorable only if there is sufficient bone height, but most of the time it decreases the sulcus depth. Ridge augmentation by grafting which is an invasive treatment option carries the risk of resorption or graft material rejection along with the need for additional surgery for graft harvesting. Age, general health, dental history, motivation, and personality of a patient contribute for the success of surgical treatment [3]. Desjardins and Tolman came up with the idea of injecting sclerosing solution to make the tissues firm [4]. However this concept has demerits like anaphylactic reactions, patient discomfort, loss of firmness in some cases, and technique sensitivity.

Prosthetic Management of a patient with a flabby maxillary ridge can be a challenging problem. Impression making plays a major role in complete denture fabrication. Standard muco-compressive impression techniques distort the flabby tissues which results in an unretentive and unstable denture. The selective pressure or minimally displacive impression techniques with the use of holes, windows and wax relieve reduces the hydraulic pressure, should help to overcome some of these situations as they minimize the displacement of the bearing flabby tissues and apply pressure on other stress bearing areas.

A technique which uses two separate impression materials were used in a custom tray (using 'plaster of Paris' over the flabby tissues and zinc oxide eugenol over the normal tissues) was described by Liddlelow in 1964. In 1964, a technique where two separate impression trays and materials were used by Osborne to separately record the 'flabby' and 'normal' tissues and then related intra-orally [5]. In 1981 Zafrullah Khan

came with the idea of using single custom made impression tray with window at the flabby areas and taking impression of the flabby tissue using impression plaster. [6] Watt and McGregor [5] in 1986 applied impression compound to a modified custom tray and a wash impression with zinc-oxide and eugenol was made.

Disadvantages of impression plaster like the material Properties are affected by operator handling technique, Taste and roughness of the material may cause the patient to vomit [7].

The disadvantages of this material are messiness and a variable setting time due to temperature and humidity. Eugenol is irritating to soft tissues. This material is non-elastic and may fracture if undercuts are present [7].

This lead to the search of a better impression material that is compatible with the technique.

Advantages of addition silicone impression material such as its shorter setting time, easy to mix, adequate tear strength, extremely high accuracy, absence of any distortion on removal and good dimensional stability suggests that addition silicone can potentially replace the impression plaster in the conventional technique [7].

### **Conclusion**

The suggested method eliminates the excessive displacement of the soft tissues at the secondary impression using a better patient accepted material. Thus a physiologic and anatomic registration of the attached and the unattached tissue of the denture bearing areas is attained.

### **References**

1. Ogden A. Guidelines in prosthetic and implant dentistry. Quintessence Publishing for British Society for the Study of Prosthetic Dentistry, 1996.
2. Xie Q, Närhi TO, Nevalainen JM, Wolf J, Ainamo A. Oral status and prosthetic factors related to residual ridge resorption in elderly subjects. *Acta Odontologica Scandinavica*. 1997; 55(5):306-13.
3. Carlsson GE. Clinical morbidity and sequelae of treatment with complete dentures. *The Journal of prosthetic dentistry*. 1998; 79(1):17-23.
4. Desjardins RP, Tolman DE. Etiology and management of hypermobile mucosa overlying the residual alveolar ridge. *Journal of Prosthetic Dentistry*. 1974; 32(6):619-38.
5. Lynch CD, Allen PF. Management of the flabby ridge: using contemporary materials to solve an old problem. *British Dental Journal*. 2006; 200(5):258.
6. Khan Z, Jagers JH, Shay JS. Impressions of unsupported movable tissues. *The Journal of the American Dental Association*. 1981; 103(4):590-2.
7. Anusavice KJ, Phillip's Science of Dental Materials, Eleventh Edition, Elsevier, USA, 2007.