



International Journal of Applied Dental Sciences

ISSN Print: 2394-7489
ISSN Online: 2394-7497
IJADS 2019; 5(2): 110-112
© 2019 IJADS
www.oraljournal.com
Received: 20-02-2019
Accepted: 22-03-2019

Dr. Pradeep PR

Professor & Vice Principal,
Department of Conservative
dentistry and Endodontics,
MR Ambedkar Dental College
and Hospital, Bengaluru,
Karnataka, India

Dr. Sukhbir Kour

Post graduate Student,
Department of Conservative
dentistry and Endodontics,
MR Ambedkar Dental College
and Hospital, Bengaluru,
Karnataka, India

Dr. Veena Kumari R

Professor and Head of
Department, department of
Conservative dentistry and
Endodontics, MR Ambedkar
Dental College and Hospital,
Bengaluru, Karnataka, India

Dr. Shoba R

Reader, Department of
periodontics, MR Ambedkar
Dental College and Hospital,
Bengaluru, Karnataka, India

Correspondence

Dr. Sukhbir Kour

Post graduate Student,
Department of Conservative
dentistry and Endodontics,
MR Ambedkar Dental College
and Hospital, Bengaluru,
Karnataka, India

Mucosal fenestration an enigma - Case report

Dr. Pradeep PR, Dr. Sukhbir kour, Dr. Veena Kumari R and Dr. Shoba R

Abstract

Mucosal fenestration is a pathological condition characterized by perforation of the alveolar bone and overlying mucosa. It exposes the root to the oral cavity making them susceptible to deposition of plaque and calculus which in turn prevents the reformation of mucosal coverage. Predisposing factors include a thin cortical alveolar bone, buccally inclined root tip, chronic periapical inflammation and trauma. In this case report the mucosal fenestration defect w.r.t to 22 was treated using a multidisciplinary approach. Nonsurgical endodontic treatment was first performed to control the infection. Subsequent surgical intervention was performed to treat the bony dehiscence with apicectomy and a combination of guided tissue regeneration and bony graft for dehiscence and connective tissue graft for treating mucosal fenestration. Patient was followed for a year, the result showed complete closure of the mucosal fenestration defect.

Keywords: Connective tissue graft, dehiscence, GTR, mucosal fenestration

Introduction

Alveolar process is the portion of maxilla and mandible that forms and supports the tooth socket. It forms when the tooth erupts in order to provide osseous attachment to the forming periodontal ligament [1]. It is the least stable of all the periodontal tissues because its structure is in a constant state of flux. Alveolar bone may undergo morphological alterations due to periodontal diseases resulting in osseous defects such as fenestrations and dehiscences, commonly involving facial bone more than the lingual bone and anterior teeth more than the posterior teeth [2]. The main cause of fenestrations and dehiscences are predominant root apex, malposition and labial proclinations of the roots, severe periradicular inflammation with bone destruction [3].

Mucosal fenestration is one of the rare clinical pathological entities where the affected root portion is exposed to the oral cavity leading to the perforation of the overlying bone and the mucosa. They are less common than bone fenestrations [1]. Although they are asymptomatic they act as plaque retentive areas and pose aesthetic issues and irritation to the patient.

The various treatment modalities for mucosal fenestrations include nonsurgical root canal treatment, apicectomy with retrograde filling [4], guided tissue regeneration combined with bone grafting [5] and periodontal surgeries like connective tissue graft and pedicle graft and free gingival graft [6] have been tried with reliable outcomes. Sub epithelial connective tissue graft or a free connective tissue graft, was first described by Langer & Calagna (1980) [7]. It is the gold standard for soft tissue augmentation and has been widely used in periodontal surgeries [8]. The present case reports the use of multidisciplinary approach including nonsurgical endodontic therapy followed by surgical management of the mucosal fenestration using a combination of GTR, bone graft and a connective tissue graft.

Case Report

A 30 year old male patient reported to the department of Conservative dentistry and endodontics, with chief complaint of discolored upper front teeth and pus discharge from exposed root surface. Patient gave the history of trauma in the same region around 17 years back. On intraoral examination both centrals and left lateral incisors were discolored, root apex of tooth 22 showed a mucosal fenestration approximately 5 mm in size exposing the root to the oral cavity (Fig1A). An access opening of tooth 11, 21, 22 was already done by the referring dentist. On palpation a purulent discharge was noticed from mucosal fenestration defect.

Radiographic examination revealed an immature open root apex w.r.t to teeth 11 and 21 (Fig 1B). A CBCT (Cone beam computer tomography) was advised to know the morphology of the bone defect. The CBCT report revealed periapical bone destruction w.r.t 11, 21, 22 with alveolar bone dehiscence w.r.t 22 (Fig 1C).

The diagnosis was necrotic pulp with asymptomatic apical periodontitis w.r.t 11, 21 and 22. 22 also presented with a labial mucosal fenestration defect. Non surgical root canal debridement was performed for 11, 21. The treatment for 22 included a multidisciplinary approach. The first stage included a root canal treatment and second stage involved treating the mucosal fenestration surgically. After determining the working length the canals, walls were thoroughly cleaned and shaped copious irrigation was done with 3% hypochlorite, 17% EDTA and canal was dried with paper points. Calcium hydroxide dressing was placed into the canals and temporary restoration was given. After 10 days the canals were chemo mechanically cleaned and calcium hydroxide dressing was changed. After 15 days canals were opened again calcium hydroxide paste was flushed out of the canal using thorough irrigation with 0.9% saline and final obturation was done. (Fig 1D). The follow up after 1 month showed decrease in the mucosal fenestration from 5mm to 3mm. (Fig 1E). However, there was a discharge from the fenestration defect w.r.t 22 even after three weeks. Hence a surgical intervention was planned. Under local anesthesia a full thickness mucoperiosteal flap was reflected w.r.t 22. Labial surface of 22 was denuded of the bone but the mesial, distal and interdental bone was intact. A bone defect was seen around the root apex. Degranulation was done around the root apex.

An apicectomy procedure was performed using air rotor with diamond bur and 3mm of root was resected from the tooth apex followed by a retro preparation and MTA (mineral trioxide aggregate) retro filling (Fig 1F). Alloplast bone graft (Perioglass)TM was condensed into the osseous defect around the root apex (Fig 1G). A GTR membrane (Guided tissue regeneration) (Healguide)TM was placed covering the root and bone graft and sutured using a vicryl 14-0 (Fig 1H). The connective tissue graft (CTG) was harvested from palate using Hurzeler's 9 single incision method. The connective tissue graft was placed over the GTR membrane it was compressed and held in position for few minutes to reduce the dead space and immobilized with 4-0 vicryl sutures (Fig 1I). The inner surface of full thickness mucoperiosteal flap was trimmed, curetted and sutured back into position over the Connective tissue graft (Fig 1J). The surgical site was protected using a periodontal pack (COE PACK)TM. Post operative instructions were given to the patient and antibiotics and analgesics were prescribed. Patient was also prescribed 0.2% chlorhexidine mouthwash twice a day for 2 weeks. The patient was followed up after 2 weeks. On removal of the pack the surgical site showed the presence of a layer of debris and mild inflammation. Saline was used to flush the debris. The patient was advised gingival massage in the surgical site. After 3 months the surgical site appeared completely healed and the mucosal fenestration defect was closed. Patient was followed up for a period of a year and showed no sign of inflammation, the mucosal fenestration defect was completely closed (Fig 1K) the radiograph showed adequate bone formation in the periapical region (Fig 1L).

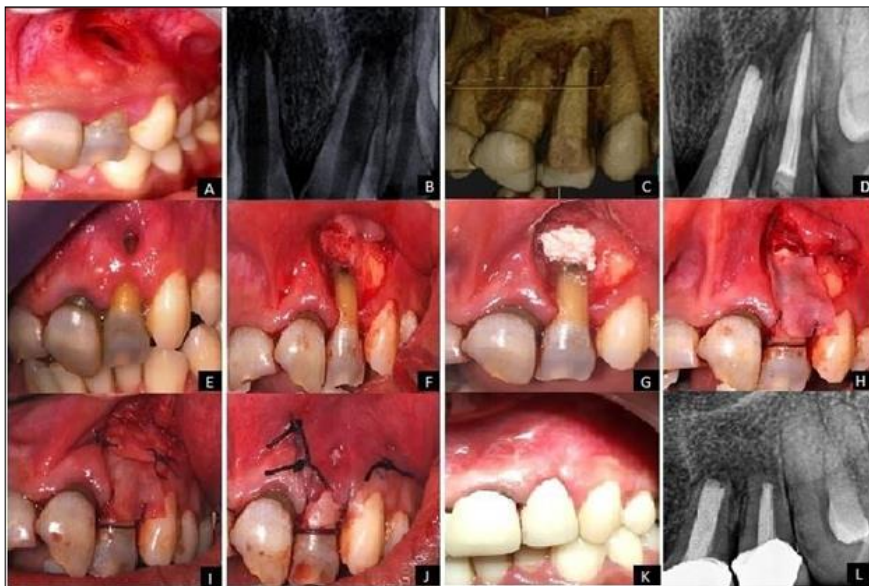


Fig 1: Management of mucosal fenestration in maxillary left lateral incisor

A) Initial clinical view of fenestration of root apex of maxillary left lateral incisor. (B) Preoperative radiograph. (C) CBCT showing bone dehiscence w.r.t 22. (D) Radiograph after completion of RCT (E) Decrease in size of mucosal fenestration 1 month after RCT. (F) Full thickness flap reflection showing affected root apex and loss of buccal cortical plate followed by root end resection and retro preparation with MTA. (G) Bone graft packed in apical bone defect. (H) GTR membrane sutured at the site. (I) Connective tissue graft harvested and sutured to the site. (J) Re-approximation and suturing of the flap. (K) Clinical view 1 year after surgery. (L) Post operative radiograph 1 year after.

Discussion

Mucosal fenestrations of the root apex are a rarely observed complication of pulpal periradicular disease. Combined loss of bone and soft tissue results in denuded and clinically exposed root surface which jeopardizes overall prognosis of the tooth. Mucosal fenestration usually accompanies severe destruction of the surrounding bone. Probable etiological factors may be prominent root apex thin buccal cortical plate and chronic periapical infection.

Though the literature on management of mucosal fenestration is very scarce there are some reports available. The successful management of mucosal fenestration depends on identifying

the cause of its occurrence. Studies done by Peacock *et al.* [10] reported the use of connective tissue graft for successful management of gingival fenestration. Chen *et al.* [11] also reported successful management of mucosal fenestrations in which demineralised freeze-dried bone allograft was packed into the bony defect and covered with CTG to achieve soft tissue coverage. Melloning *et al.* [12] and Flemming *et al.* [13] showed favorable outcomes with bone graft.

Pecora *et al.* [14] showed that the quality and quantity of the regenerated bone were superior when GTR procedures were performed for large periapical lesions, and human histological studies confirmed that the new tissue gained from GTR therapy consisted of mature lamellar bone [15]. GTR techniques improve the outcomes of bone regeneration after surgical endodontic treatment of teeth with large periapical lesions [16].

A CTG is thought to transform a thin gingival tissue into a thick one. Healing of mucosal defect is expedited by allowing for migration of epithelial cells from the edges of the defect and helps in reattaching the mucosal soft tissue to the exposed root surface. Successful management of periapical mucosal fenestration requires adequate debridement of the root canal followed by reconstruction of bony and mucosal defect [17]. In the present case 11, 21, 22 were nonvital and were first treated by root canal therapy to eliminate the foci of infection. After a month of follow up the mucosal fenestration w.r.t 22 was treated by a surgical intervention to remove granulation tissue from the root apex, followed by apicectomy and retro filling with MTA. Guided tissue regeneration combined with an alloplast was used in the periapical bone defect to regenerate lost periodontal tissue.

Connective tissue graft aids in healing of the mucosal defect and carries the genetic message for the overlying epithelium to become keratinized and improved aesthetics can be achieved.

For the treatment of apical lesions with mucosal fenestration, optimal root canal treatment and good retrograde filling to seal the canals is mandatory. MTA has excellent sealing ability, reliable healing rate [18] and predictable results are seen with its use, osseous defect debridement, GTR procedures, and connective tissue graft are important to achieve desirable treatment outcomes.

The treatment regimen described in this case report demonstrated significant clinical improvement and complete mucosal fenestration defect coverage. More cases need to be reported to validate the success and the reliability of this approach.

Conclusion

Careful diagnosis of mucosal fenestration managed by a combination of endodontic and surgical technique can result in an optimum outcome.

References

1. Newman T. Klokkevold and Carranza. Carranza's Clinical Periodontology: South Asia Edition.
2. Rawlinson A. Treatment of a labial fenestration of a lower incisor tooth apex. Br Dent J. 1984; 156:448-9.
3. Jhaveri HM, Amberkar S, Galav L, *et al.* Management of mucosal fenestrations by interdisciplinary approach: a report of three cases. J Endod. 2010; 36:164-8.
4. Lehman III J, Meister Jr F, Gerstein H. Use of a pedicle flap to correct an endo problem: a case report. Journal of endodontics. 1979; 5(10):317-20.
5. Tseng CC, Chen YH, Huang CC, Bowers GM.

- Correction of a large periradicular lesion and mucosal defect using combined endodontic and periodontal therapy: a case report. International Journal of Periodontics & Restorative Dentistry. 1995; 1:15(4).
6. Ju YR, Hsin-Yi Tsai A, Wu YJ, Pan WL. Surgical intervention of mucosal fenestration in a maxillary premolar: a case report. Quintessence international. 2004; 35(2).
7. Langer B, Calagna L. The subepithelial connective tissue graft. The Journal of prosthetic dentistry. 1980; 44(4):363-7.
8. Becker W, Becker BE. Periodontal regeneration updated. The Journal of the American Dental Association. 1993; 124(7):37-43.
9. Hürzeler MB, Weng D. A single-incision technique to harvest subepithelial connective tissue grafts from the palate. International Journal of Periodontics & Restorative Dentistry. 1999; 19(3).
10. Peacock ME, Mott DA, Cuenin MF, Hokett SD, Fowler EB. Periodontal plastic Surgical technique for gingival fenestration closure. General dentistry. 2001; 49(4):393-5.
11. Chen G, Fang CT, Tong C. The management of mucosal fenestration: a report of two cases. International Endodontic Journal. 2009; 42(2):156-64.
12. Mellonig JT. Decalcified freeze-dried bone allograft as an implant material in human periodontal defects. The International Journal of Periodontics & Restorative Dentistry. 1984; 4(6):40-55.
13. Flemmig TF, Ehmke B, Bolz K, Kübler NR, Karch H, Reuther JF *et al.* Long-term maintenance of alveolar bone gain after implantation of autolyzed, antigen-extracted, allogenic bone in periodontal intraosseous defects. Journal of Periodontology. 1998; 69(1):47-53.
14. Pecora G, Kim S, Celletti R, Davarpanah M. The guided tissue regeneration principle in endodontic surgery: one-year postoperative results of large periapical lesions. Int Endod J. 1995; 28:41-6.
15. Brugnamì F, Mellonig JT. Treatment of a large periapical lesion with loss of labial cortical plate using GTR: case report. Int J Periodontics Restorative Dent. 1999; 19:243-9.
16. Tsesis I, Rosen E, Tamse A *et al.* Effect of guided tissue regeneration on the outcome of surgical endodontic treatment: a systematic review and meta-analysis. J Endod. 2011; 37:1039-45.
17. Yang ZP. Treatment of labial fenestration of maxillary central incisor. Dental Traumatology. 1996; 12(2):104.
18. Von Arx T, Penarrocha M, Jensen S. Prognostic factors in apical surgery with rootend filling: a meta-analysis. J Endod. 2010; 36:95.