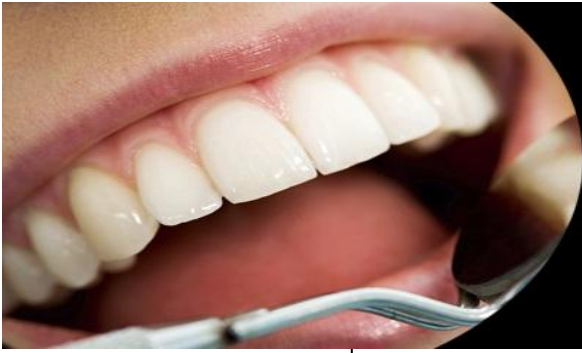



ISSN Print: 2394-7489  
ISSN Online: 2394-7497  
IJADS 2019; 5(2): 233-240  
© 2019 IJADS  
www.oraljournal.com  
Received: 24-02-2019  
Accepted: 26-03-2019

**Sunita Marothiya**  
Lecturer, Department of  
Orthodontics and Dentofacial  
Orthopedics, Sri Aurobindo  
College of Dentistry and PG  
Institute, Indore, Madhya  
Pradesh, India

**Vedant Patel**  
Lecturer, Department of  
Prosthodontics and Crown &  
Bridge and Implantology, Index  
Institute of dental Sciences,  
Indore, Madhya Pradesh, India

**Divya Jain**  
PG Student, Department of  
Prosthodontics and Crown &  
Bridge and Implantology,  
Darshan Dental College and  
Hospital, Udaipur, Rajasthan,  
India

**Shubhangi Agrawal**  
PG Student, Department of  
Prosthodontics and Crown &  
Bridge and Implantology,  
Darshan Dental College and  
Hospital, Udaipur, Rajasthan,  
India

**Surbhi Joshi**  
Tutor, Sri Aurobindo College of  
Dentistry and PG Institute,  
Indore, Madhya Pradesh, India

**Vipin Pandey**  
Tutor, Sri Aurobindo College of  
Dentistry and PG Institute,  
Indore, Madhya Pradesh, India

**Correspondence**  
**Sunita Marothiya**  
Lecturer, Department of  
Orthodontics and Dentofacial  
Orthopedics, Sri Aurobindo  
College of Dentistry and PG  
Institute, Indore, Madhya  
Pradesh, India

## Cone beam computed tomography in orthodontics: A literature review

**Sunita Marothiya, Vedant Patel, Divya Jain, Shubhangi Agrawal, Surbhi Joshi and Vipin Pandey**

### Abstract

3D imaging is quickly emerging as the standard of care in orthodontics as new ultralow-dose CBCT technology offers safer and more affordable volumetric scanning than ever before. Orthodontist routinely use 2-dimensional (2D) static imaging technique, but deepness of structures cannot be obtained and localized with 2-D imaging. Introduction of cone-beam computed tomography (CBCT) for the maxillofacial region provides opportunities for dental practitioners to request multiplanar imaging. This review covers the principles, image acquisition and image reconstruction, various display modes of CBCT and its various application in orthodontics.

**Keywords:** 3D imaging, cone-beam computed tomography (CBCT), computed tomography (CT)

### 1. Introduction

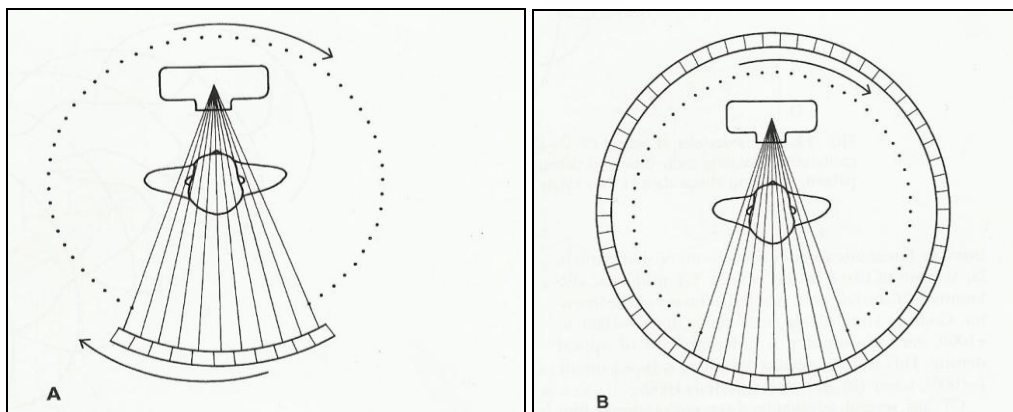
Dr. B. Holly Broadbent Sr. ushered in the age of 3D orthodontics when he first proposed taking a lateral and frontal head film simultaneously to evaluate patients in multiple planes of space [1]. Today we have the technology to image and visualize the entire head in 3D. Cone-beam computed tomography (CBCT) has made a remarkable entry into the field of Orthodontic diagnosis the last few years. It produces impressive 3D color pictures, in comparison to the black & white 2D projections we have been accustomed to.<sup>2</sup> It offers the distinct advantage of 1:1 geometry, which allows accurate measurements of objects and dimensions, therefore it is frequently applied for maxillofacial imaging for better diagnostic accuracy and treatment planning.<sup>3</sup>The aims of this literature review to illustrate the application of CBCT in orthodontics through its different and unique image display of maxillofacial region.

### 2. Computed Tomography (CT)

CT imaging, also called computerized axial tomography (CAT) imaging. It was invented by Godfrey Hounsfield in England at the end of the 1960's and by Allan Cormack in the USA who developed image reconstruction mathematics to provide cross sectional of head. Both shared the Nobel Prize in medicine in 1979 [4].

The term tomography comes from the Greek words tomos, which means to slice or to divide, and graphein, which means to write. So, by definition it is an imaging of an object by analyzing its slices [5].

In CT scanners, x-ray source and solid-state detector are mounted on a rotating gantry. Data are acquired using a narrow "fan-shaped" x-ray beam transmitted through the patient. The patient is imaged slice-by-slice, usually in the axial plane, and interpretation of the images is achieved by stacking the slices to obtain multiple 2D representations [6]. In early CT scanners both x-ray source and detectors revolved around the patient the and only single row of detectors were present for capturing data. Recent advances in CT include multirow detectors, having 4 to 64 rows of detectors which can acquired up to 320 slices simultaneously [7] (Fig. 1).



**Fig 1:** Mechanical geometry of CT scanners. A, Both the x-ray tube and the detector array revolve around the patient. B, Only the x-ray tube rotates; radiation detection is accomplished by the use of a fixed circular array of as many as 1000 detectors.

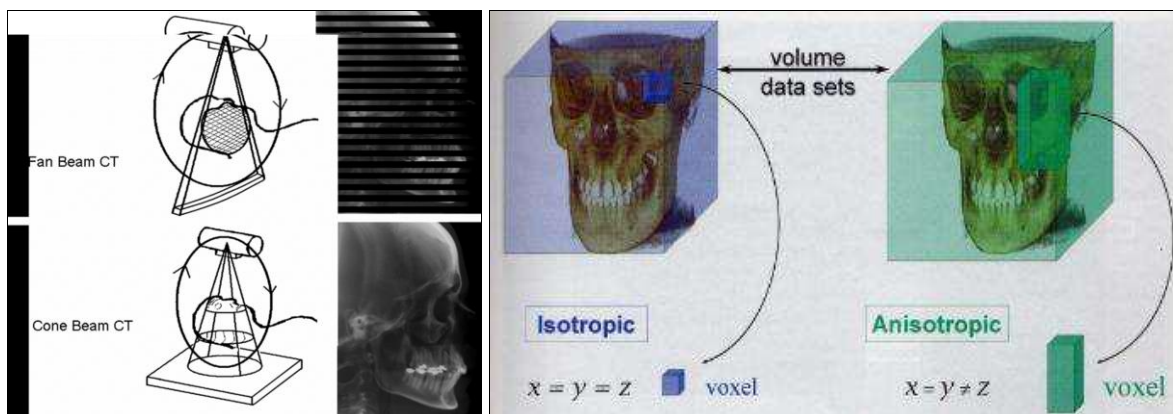
**3. Cone Beam Computed Tomography (CBCT)**

In 1982, Richard Rob a biophysicist and computer scientist at Mayo clinic developed the first CBCT (built for angiography). It uses a “Cone shaped” divergent beam of ionizing radiation like X-rays and a 2D area detector mounted on a rotated gantry to acquire multiplanar sequential projection images in one single scan around the area of interest and the scanning software collects this projection data and reconstructs it, and producing volumetric data [8]. Imaging may be performed with the patient seated, supine, or standing. The patient’s head is positioned and stabilized

between the x-ray generator and detector by a head holding apparatus [7].

**3.1 Advantage of Cone shaped x-ray beam over fan shape:**

Fan beam CT scanners produce images in slices. The slices need to be put together in the correct order and orientation to construct the volume from which subsequent reoriented slices can be made and precision in measurement can be compromised and anisotropic type of image are formed. In Cone beam CT scanners [8] (Figure 2)



**Fig 2:** X-ray beam projection scheme comparing a single detector array fan-beam CT (a) and cone-beam CT (b) geometry

**3.2 CBCT Image Reconstruction**

It consist of two stages: acquisition and reconstruction. CBCT involves the rotational scan exceeding 180 degree of an x ray source and reciprocating area detector moving simultaneously. During rotation many exposure are made at fixed interval. A single projection image is called basis image and a complete series of basis image is called raw or projection images which cannot be view directly (Acquisition stage). This images undergoes sophisticated mathematical algorithm in the reconstruction stage which recombined all the images to form a volumetric data which is equal in all dimension [8].

**3.3.2 Sub millimeter Resolution**

CBCT units use megapixel solid state devices for x-ray detection providing a minimal voxel resolution of between 0.07 mm and 0.25 mm isotropically, exceeding most high grade multislice CT capabilities in terms of spatial resolution. This nominal resolution approaches that required for the most discerning tasks in orthodontics-the determination of periodontal ligament space, particularly in cases of suspected ankylosis.

**3.3 CBCT Advantages [8].**

**3.3.1 Variable Field of View (FOV)**

An optimal FOV can be selected for each patient based on disease presentation and the region designated to be imaged. While an orthodontist is likely to wish to see the full maxillofacial complex images, regional high resolution scans might be appropriate for such tasks as evaluating the position of impacted teeth.

**3.3.3 High speed scanning**

CBCT generally acquires all basis projection images in a single rotation, so scan time can be minimized. When compared with medical fan beam CT systems, particularly for high resolution, each slice thickness sequence can take up to several tens of seconds. Although faster scanning time usually means fewer basis images from which to reconstruct the volumetric data set, motion artifacts due to subject movement are reduced.

### 3.3.4 Dose Reduction

Reports indicate that CBCT patient absorbed dose is reported to be significantly reduced when compared with conventional CT [9-11].

### 3.3.5 Voxel isotropy

CBCT uses a 2D detector and the same high resolution is obtained in the longitudinal slice (body axis direction) and lateral slice (transverse direction). This voxel representation is known as isotropic. Because of this characteristic, coronal MPR of CBCT data has the same resolution as axial data. In conventional CT, the voxels are anisotropic - rectangular cubes where the longest dimension of the voxel is the axial slice thickness and is determined by slice pitch, a function of gantry motion.

### 3.3.6 Real-Time Analysis and Enhancement

Reconstruction of CBCT data is performed natively using a personal computer. As the original data are isotropic, it can be reoriented such that the patient's anatomic features are realigned. This is particularly important for cephalometric analysis. Finally, the availability of cursor-driven measurement algorithms provides the clinician with an interactive capability for real-time dimensional assessment.

### 3.3.7 Display Modes Unique to Maxillofacial Imaging

CBCT units initially reconstruct the projection data to provide standard viewing layouts in three orthogonal planes-frontal (sagittal), lateral, and superior (axial) (Figure 3).

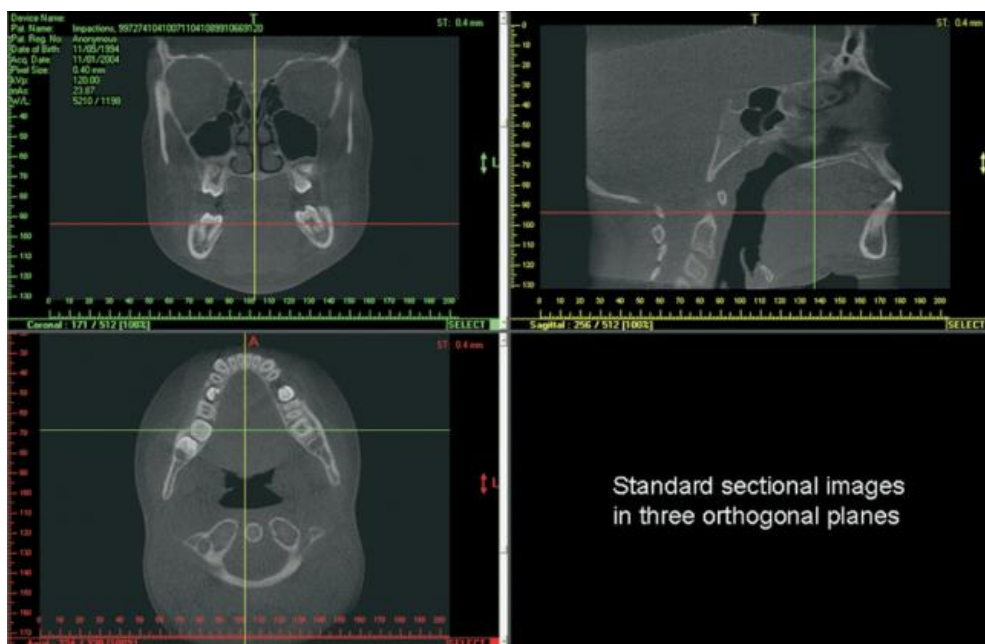


Fig 3: Initial presentation of CBCT image slices in three orthogonal planes

### 3.3.8 Multiplanar Reformating

Reformatting images at a nonorthogonal or oblique orientation, referred to as multiplanar reformatting (MPR), the same spatial resolution as the original voxel size. Structures are not particularly well visualized and represented as

displayed in the sagittal and/or coronal planes -----MPR can be useful in these instances. The orientation of this formatting is viewer derived and can be:

- Linear oblique (useful for temporomandibular joint assessment) (Fig. 4)

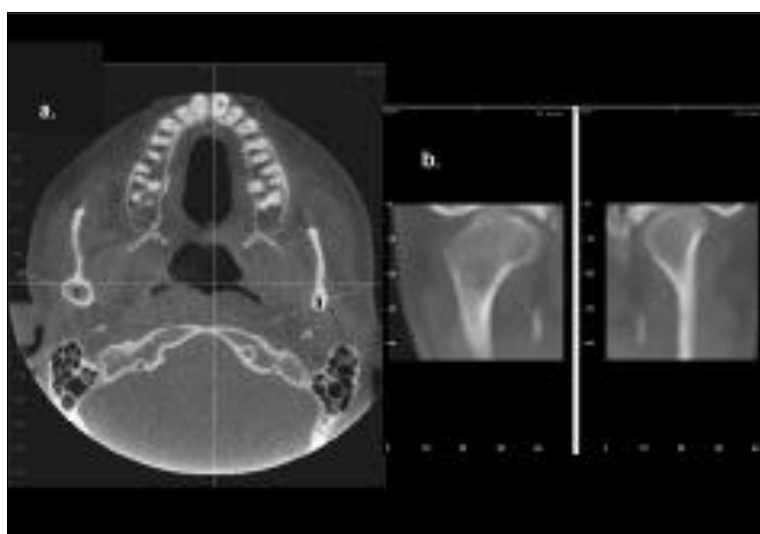
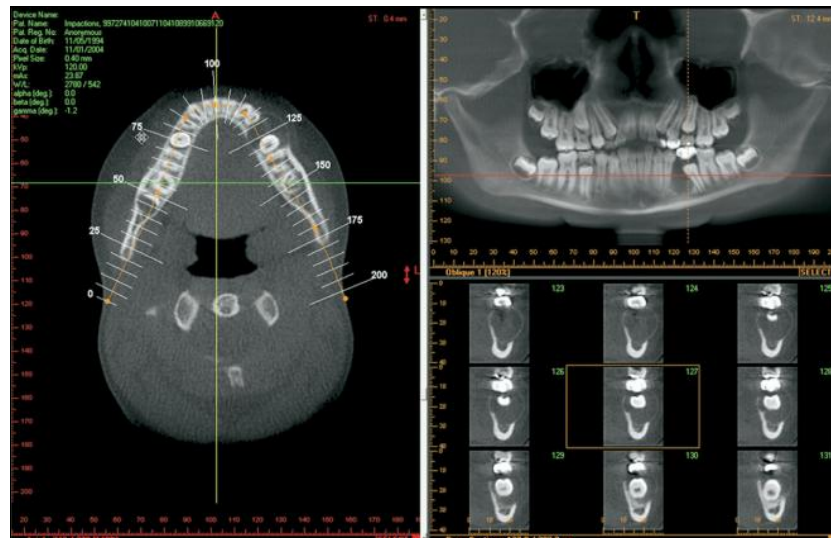


Fig 4: Bilateral linear oblique multiplanar reformation through lateral and medial poles of the mandibular condyle on the axial image (a) providing corrected coronal, limited field-of-view, thin-slice temporomandibular views (b) demonstrating right condylar hyperplasia

- Curved oblique (providing a “panoramic” image) (Fig. 5) or
- Serial transplanar (providing sequential contiguous cross-sectional imaging orthogonal MPR) (Fig. 5)



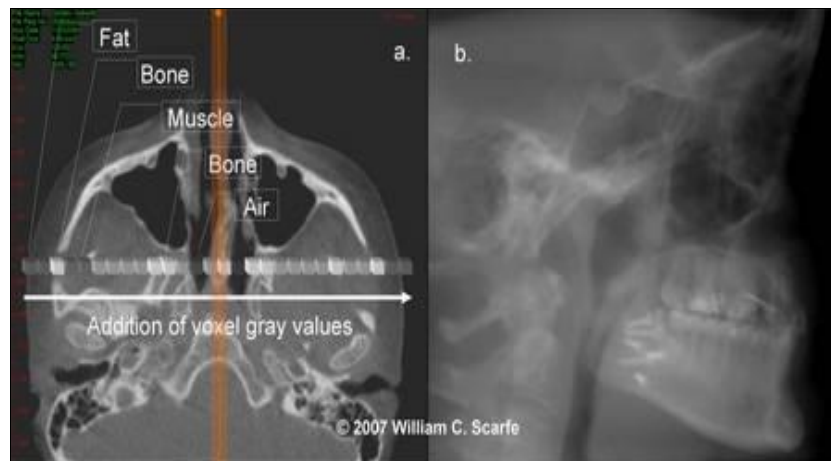
**Fig 5:** Reformatted panoramic image (a) providing reference for multiple narrow trans-axial thin cross-sectional slices (b) of radiolucent bony pathology in the left mandible, demonstrating bucco-lingual expansion and location of the inferior alveolar canal.

### 3.3.9 Voxel Vision

Volumetric vision refers to the approaches that can be applied to visualize 2D data in a 3D mode. Because of the large number of component slices in any MPR image and the difficulty in relating adjacent structures, three techniques have been developed to visualize adjacent voxels:

- Variable slice thickness viewing
- Maximum intensity projection (MIP)
- Indirect volume rendering (IVR)
- Variable slice thickness viewing

Most simply, any multi-planar image or orthogonal image can be "thickened" by increasing the number of adjacent voxels included in the display. This creates an image that represents a specific volume of the patient. The addition of intensity values of adjacent voxels throughout a particular section slice by increasing the section thickness creates a "slab" of the section referred to as a "ray sum". This mode can be used to generate simulated projections such as lateral cephalometric images. These can be created from full thickness (130-150 mm) perpendicular MPR images (Fig. 6).

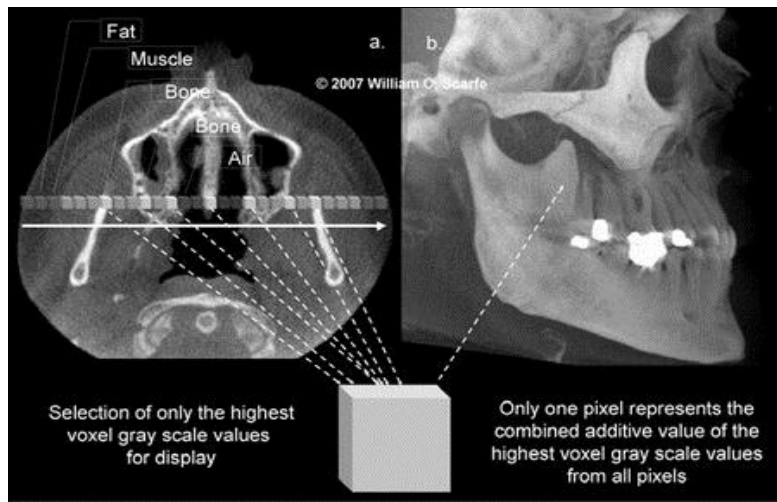


**Fig 6:** An axial projection (a.) is used as the reference image. A section slice is identified (orange) which, in this case, corresponds to the mid-sagittal plane and the thickness of this increased to include both left and right sides of the volumetric dataset. As the thickness of the "slab" increases, adjacent voxels representing elements such as air, bone and soft tissues are added. The resultant image generated (b.) provides a simulated lateral cephalometric.

- **Maximum intensity projection (MIP)** <sup>[12]</sup>

MIP is a 3D visualization technique that is achieved by evaluating each voxel value along an imaginary projection ray from the observer's eyes within a particular volume of interest. It is a simpler process. MIP images are achieved by displaying only the highest voxel value within a particular thickness. This mode produces a “pseudo” 3D structure and is particularly useful in representing the surface morphology of

the maxillofacial region. MIP is particularly useful in representing the bony surface morphology of the maxillofacial region. In maxillofacial imaging, it is often better than surface rendered 3D images to evaluate the location of third molars or can be applied to evaluate the presence of a foreign body material or calcification in soft tissue structures (Fig 7).

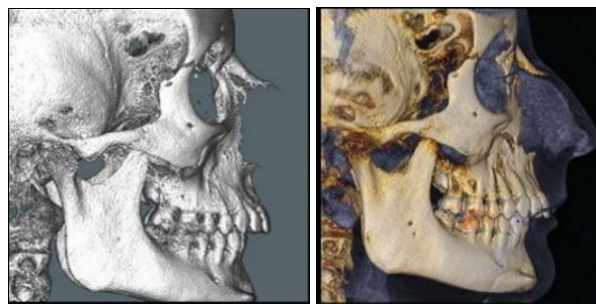

**Fig 7:** In this example, an axial projection (a.) is used as the reference image. A projection ray is identified (orange) throughout the entire volumetric dataset along which individual voxels are identified, each with varying grayscale intensity corresponding to various tissue densities such as fat, muscle, air and bone.

• **Indirect volume rendering/ Shaded Surface Rendering (SSR)** [15, 16]

It is a complex process requiring selection of intensity or density of the grayscale level of the voxels to be displayed within a an entire data set (called “segmentation“).This is technically demanding as it is necessary for the operator to

provide either pre-set or manual inputs as to which voxels should be included. It is also computationally difficult, requiring specific software. However, the process provides a volumetric surface reconstruction with depth (Fig. 8).

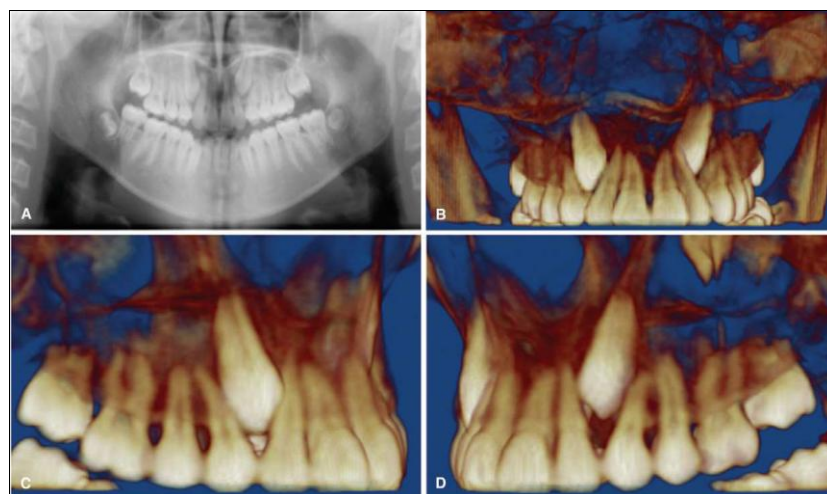


**Fig 8 A).** Visualization of the full data volume by mean of a shaded surface display with the threshold set to show hard tissues (bone and teeth) only. **B)** The data attenuation values corresponding to the soft tissues were made partially transparent, allowing for visualization of the underlying skeleton and teeth.

**4. Application of CBCT in Orthodontics**

**4.1 Impacted and transposed teeth** [14, 15]

Most common indications for CBCT imaging in orthodontics (Fig. 9)

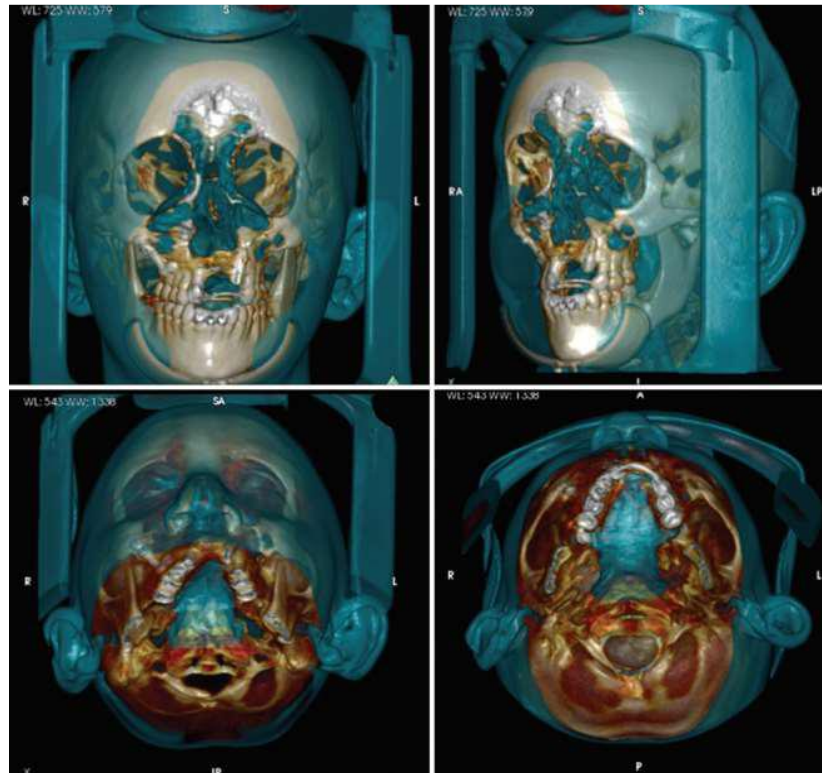


**Fig 9:** Depiction of impacted maxillary canines using a conventional 2D panorex (A) and 3D volumetric rendering. The 3D images permit clear visualization of the location and relationships of the impacted canines to adjacent structures, as well as the presence of any root resorption. It facilitates treatment decisions, including determination of teeth to be extracted. If yes then the optimal surgical approach, appropriate placement of attachments, and biomechanics planning.

**4.2 Cleft lip and palate (CL/P)** [14]

3D volumetric reconstructions of a patient with bilateral CL/P are useful in obtaining detailed information on the magnitude

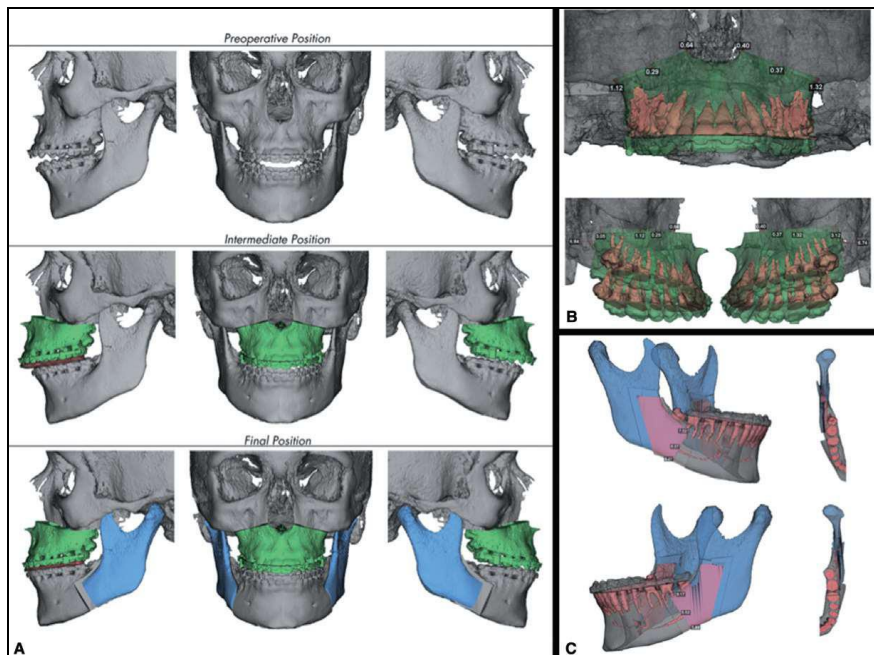
of the defect and the status and position of teeth at the defect site (Fig. 10).



**Fig 10:** Surface rendered volumetric reconstruction of patient having cleft lip defect

**4.3 Orthognathic and craniofacial anomalies surgical planning and implementation** [14] CBCT combined with computer-aided surgical simulation (CASS) or computer-aided Orthognathic surgery (CAOS) offers refining diagnosis

and optimizing treatment objectives in 3D virtual treatment planning to improve surgical procedures and outcomes (Fig. 11).

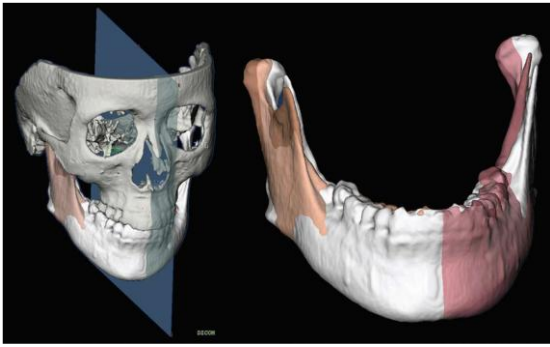


**Fig 11:** Virtual surgical treatment planning for a patient to visualize and determine the magnitude of maxillary and mandibular

**4.4 Asymmetry** [14, 16]

When large differences exist between bilateral structures, CBCT scans enable the use of a technique called “mirroring” in which the normal side is mirrored onto the discrepant side

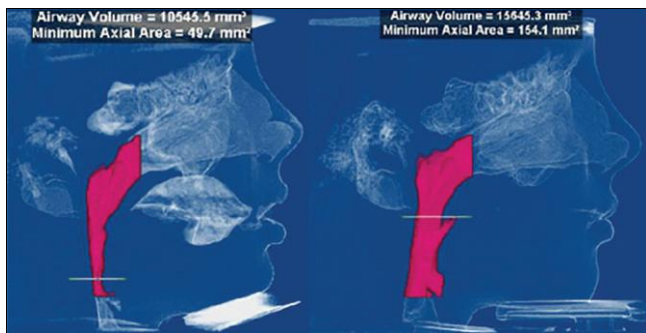
so as to simulate and visualize the desired end result, as well as to plan the surgery to facilitate correction (Fig. 12). (Metzger *et al.* 2007)



**Fig 12:** Mirroring on a mid-sagittal plane for quantitation of mandibular asymmetry

**4.5 CBCT in OSA (Obstructive Sleep Apnea) [17]**

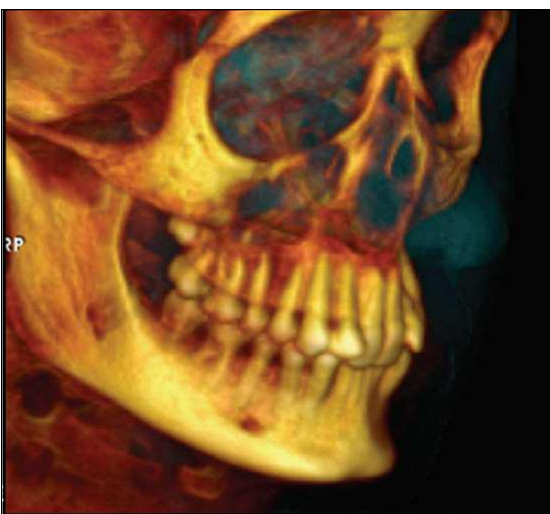Measuring the size and shape of the pharynx is critical to diagnose obstructive sleep apnea and when contemplating surgery, particularly maxillary or mandibular setback procedures. In cross-section the pharynx is more elliptical than round and thus 2D information from a lateral cephalogram may be insufficient or misleading for diagnosis of obstructive sleep apnea (Fig. 13).



**Fig 13:** Cone-beam computed tomography image of the pharyngeal airway

**4.6 Alveolar boundary conditions [14]**

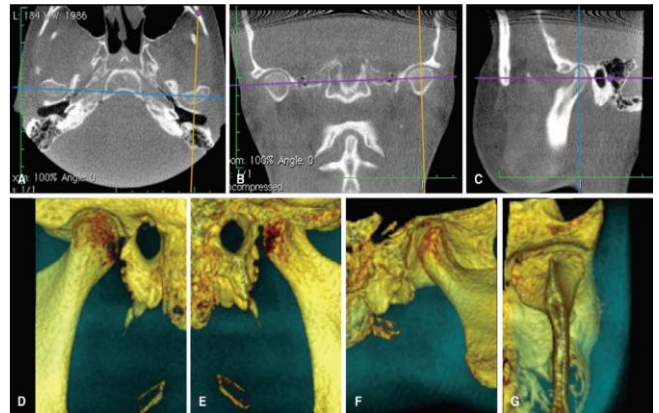
Compromised pretreatment alveolar boundary conditions may limit or interfere with the planned or potential tooth movement. Failure to diagnose compromised alveolar bone prior to treatment and to involve this into the treatment plan likely will lead to worsening of the problem during orthodontic treatment (Fig 14).



**Fig 14:** A severe Class II division 2 malocclusion presents with upper incisor roots that have limited buccal bone support that could be placed into

**4.7 TMJ degeneration, progressive bite changes functional shifts, and responses to therapy**

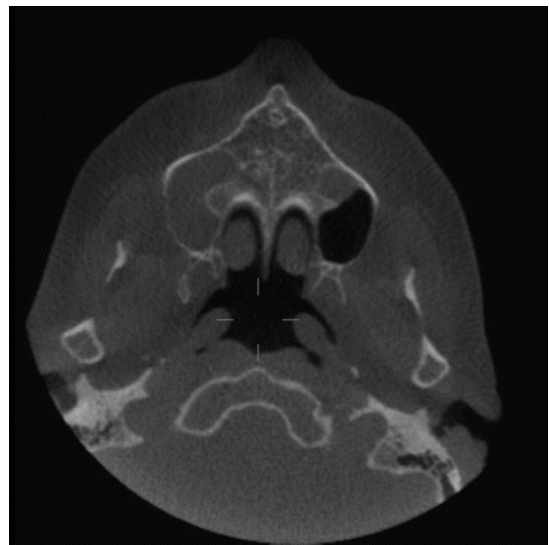
The comparison of the CBCT imaging with complex panoramic radiography and linear tomographic views was made by Honey *et al.* where he presented the accuracy and superior reliability of the CBCT images for the diagnosis of condylar morphology and erosion [18] (Figure 15)



**Fig 15:** Visualization of the TMJ in the axial (A), coronal (B), and sagittal (C) planes, as well as 3D volumetric reconstructions here visualized from the buccal (D), medial (E), medio-inferior (F), and antero-inferior (G). In 3D can help in the identification of pathologic changes, including sclerosis, flattening, erosions, osteophytes, abnormalities in joint spaces, and responses of the joint tissues to therapy.

**4.8 Interpreting the Cone Beam Data Volume for Occult Pathology [19]**

Sinus blockage, a calcified plaque, osteoarthritic changes in the vertebral bodies or temporomandibular joint (TMJ) condyle, or even a cysts, tumor, were not anticipated or suggested by clinical examination or the medical history. These findings are termed “occult” (Fig. 16).



**Fig 16:** An axial view showing mucosal change filling the right antrum entirely, and left partially at the level of the nasopalatine foramen. Other axial slices and additional views in other planes of section will completely characterize the changes, radiographically.

**5. Conclusion**

This technique hugely expands the fields for diagnosis and treatment possibilities. It provides clinicians with sub-millimetre spatial resolution images of high diagnostic quality with relatively short scanning times (10–70 seconds) and a

reported radiation dose equivalent to that needed for 4 to 15 panoramic radiographs. However CBCT should be used with careful consideration, it should not be used deliberately where 2D imaging suffices.

## 6. References

1. Broadbent BH. A new x-ray technique and its application to orthodontia. *Angle Orthod.* 1931; 1(3):45-66.
2. European Federation of Orthodontic Specialists Association (FOSA) Radiation Guidelines, 2017.
3. Larson BE. Cone-beam computed tomography is the imaging technique of choice for comprehensive orthodontic assessment. *Am J Orthod Dentofacial Orthop.* 2012; 141(4):402-11.
4. Filler AG. The History, Development and Impact of Computed Imaging in Neurological Diagnosis and Neurosurgery: CT, MRI, and DTI. *IJN.* 2010; 7(1):1-85.
5. MUDr. Lukas Miksik, KZM FN Motol. Basic principles of computed tomography.
6. Scarfe WC, Farman AG, Sukovic P. Clinical Applications of Cone-Beam Computed Tomography in Dental Practice. *J Can Dent Assoc.* 2006; 72(1):75-80.
7. Radiology: Principles and Interpretation. 5th ed. Stuart C. White & Michael J Pharoah.
8. Allan Farman G, William Scarfe C. The Basics of Maxillofacial Cone Beam Computed Tomography. *Semin Orthod.* 2009; 15(1):2-13.
9. Ludlow JB, Davies-Ludlow LE, Brooks SL. Dosimetry of two extraoral direct digital imaging devices: New Tom cone beam CT and Orthophos Plus DS panoramic unit. *Dentomaxillofacial Radiol.* 2003; 32(4):229-234.
10. Ludlow JB, Davies-Ludlow LE, Brooks SL, Howerton B. Dosimetry of 3 CBCT units for oral and maxillofacial radiology. Presented at the 15th International Congress of the International Association of Dento-Maxillo-Facial Radiology, Cape Town, South Africa, 2005.
11. Ngan DC, Kharbanda OP, Geenty JP, Darendeliler MA. Comparison of radiation levels from computed tomography and conventional dental radiographs. *Aust Orthod J.* 2003; 19(2):67-75.
12. Scarfe WC, Farman AG. Voxel Vision using Maxillofacial CBCT: Clinical Applications of the Maximum Intensity Projection. American Association of Dental Maxillofacial Radiographic Technicians. Summer, 2007.
13. David Hatcher C. Operational Principles for Cone-Beam Computed Tomography. *JADA.* 2010; 141(10):3S-6S.
14. Sunil Kapila D. Cone Beam Computed Tomography in Orthodontics: Indications, Insights, and Innovations, 2014.
15. Tamimi D, ElSaid K. Cone Beam Computed Tomography in the Assessment of Dental Impactions. *Semin Orthod.* 2009; 15(1):57-62.
16. Metzger MC, Hohlweg-Majert B, Schwarz U, Teschner M, Hammer B, Schmelzeisen R. Manufacturing splints for orthognathic surgery using three-dimensional printer. *Oral Surg Oral Med Oral Pathol Oral Radiol Endod.* 2008; 105(2):e1-7.
17. McCrillis MJ *et al.* Obstructive Sleep Apnea and the Use of Cone Beam Computed Tomography in Airway Imaging: A Review. *Semin Orthod.* 2009; 15(1):63-69.
18. Honey OB, Scarfe WC, Hilgers MJ, Klueber K, Silveira AM, Haskell BS *et al.* Accuracy of cone-beam computed tomography imaging of the temporomandibular joint: Comparisons with panoramic radiology and linear

tomography. *Am J Orthod Dentofacial Orthop.* 2007; 132(4):429-38.

19. Dale Miles A. Interpreting the Cone Beam Data Volume for Occult Pathology. *Semin Orthod.* 2009; 15(1):70-76.