



ISSN Print: 2394-7489  
ISSN Online: 2394-7497  
IJADS 2019; 5(3): 79-83  
© 2019 IJADS  
www.oraljournal.com  
Received: 07-05-2019  
Accepted: 09-06-2019

**Mohammed Sabe-Alarab**  
Prof, PhD in Oral and  
Maxillofacial Surgery, Faculty of  
Dentistry, Hama University  
Hama, Syria

**Yaman Shomal**  
PhD Student in Oral and  
Maxillofacial Surgery, Faculty of  
Dentistry, Hama University  
Hama, Syria

**Fawaz Jaber**  
PhD Student in Oral and  
Maxillofacial Surgery, Faculty of  
Dentistry, Hama University  
Hama, Syria

**Ali N Harba**  
Master in Oral and Maxillofacial  
Surgery, Faculty of Dentistry,  
Damascus University,  
Damascus, Syria

**Correspondence**  
**Mohammed Sabe-Alarab**  
Prof, PhD in Oral and  
Maxillofacial Surgery, Faculty of  
Dentistry, Hama University  
Hama, Syria

## Alveolar ridge preservation with $\beta$ -TCP a randomized controlled trial

Mohammed Sabe-Alarab, Yaman Shomal, Fawaz Jaber and Ali N Harba

### Abstract

**Purpose:** Resorption of the alveolar bone is an unavoidable consequence of tooth extraction when appropriate alveolar ridge preservation (ARP) measures are not taken. The objective of this trial was to test the hypothesis that dimensional changes in the alveolar bone after tooth extraction would be reduced by using beta tricalcium phosphate ( $\beta$ -TCP) to fill the alveolus (as ARP), in comparison to extraction with untreated alveoli.

**Methods:** In this randomized clinical trial, 40 single root teeth from the mandible of 32 patients (Male=11 Female=21 mean aged  $55.3\pm 8.9$  years; age range, 37–72 years) were extracted. Twenty teeth were directly treated with  $\beta$ -TCP material after extraction (in the ARP group). The other twenty teeth served as a control group. After extraction, no further treatment (i.e., no socket preservation measures) was performed in the control group. Changes in the height of alveolar process after three months of extraction and after six months were evaluated by means of cone-beam computed tomography CBCT.

**Results:** Both the ARP and control groups showed a reduction of bone height in the alveolar area after tooth extraction. However, significantly less bone height resorption was detected in the ARP group after three and six months compared to control group. The median bone height reduction after three months was  $1.29\pm 0.25$  mm in the ARP group and  $2.89\pm 0.49$  mm in the control group ( $P = 0.032$ ). And the median bone height reduction after six months was  $1.78\pm 0.32$  mm in the ARP group and  $3.93\pm 0.51$  mm in the control group ( $P = 0.041$ ).

**Conclusions:** The proposed hypothesis that inserting a  $\beta$ -TCP in the fresh socket after extraction would lead to a difference in alveolar bone preservation which could be accepted for the clinically relevant height. In this area, implantation of  $\beta$ -TCP material led to significantly less alveolar bone resorption.

**Keywords:** Alveolar bone loss, alveolar ridge augmentation, bone regeneration, biocompatible materials  $\beta$ -TCP, Tooth extraction

### 1. Introduction

After tooth extraction, the main changes take place in the resorption characteristics of the alveolar process [1]. In particular, significant resorption of the buccal portion of the empty cavity of the alveolus can be detected [2]. The basis for natural regeneration and bone regeneration is that the defect fills with blood. A stable blood clot is overgrown by epithelium, which seals the wound. Within the blood clot, fibrin forms a natural support structure and scaffold, which facilitates the formation of osteoid and its subsequent calcification [3]. Bone regeneration is complete after approximately 120 days, and the periosteum fully stabilizes after approximately 180 days [4, 5]. The regeneration processes start from the empty alveolus and result in mature and mineralized bone. These Processes occur over intervals that vary widely among individuals and are not predictable [6]. However, bone regeneration does not lead to complete replacement of the alveolar bone. A recent review showed that the above-described defect healing process results in a mean horizontal degeneration of the alveolar process of 3.8 mm in the vestibular-oral direction and a mean vertical degeneration of 1.2 mm over the first 6 months after tooth extraction [7, 8]. During this process, vestibular/buccal degeneration is significantly more pronounced, which could be due to a reduced blood supply to the thin vestibular bone [9]. Methods of stabilizing the bone, thereby reducing the extent of the resorption process, include the insertion of different materials into the alveolar cavity for alveolar ridge preservation (ARP) [10-12]. Apart from autologous bone, allogenic, xenogeneic, and synthetic bone replacement materials are available for ARP [1, 7, 8]. It has been shown that the various ARP materials result in a reduction of the dimensional change in the hard and soft

tissue of the extraction alveoli, but cannot entirely prevent resorption [8]. Adequate bone regeneration is significant for the functional and aesthetic prognosis of an implant [13].

A procedure for reducing bone resorption by applying a  $\beta$ -TCP material alone would therefore be of interest.

A systematic literature search regarding the use of  $\beta$ -TCP material alone for ARP using the search terms (clinical AND (trial OR study OR systematic review) AND (ARP OR "alveolar ridge preservation" OR "socket preservation" OR (tooth OR teeth AND (ridge preservation OR socket preservation) AND  $\beta$ -TCP)) revealed no studies describing the clinical efficacy of ARP with a  $\beta$ -TCP material alone compared with untreated post-extraction alveoli.

The objective of this trial was to investigate the clinical application of  $\beta$ -TCP material alone for bone preservation and to compare the results to those observed in untreated post-extraction alveoli. The proposed hypothesis was that using  $\beta$ -TCP material alone for ARP that might reduce the dimensional changes of the alveolar bone after tooth extraction to a significant extent in comparison with sites untreated after extraction.

## 2. Materials and Methods

### 2.1 Trial design

The trial was performed as a monocentric, parallel-group randomized human clinical trial in accordance with the Declaration of Helsinki. It is reported according to the Consort guidelines [14-15]. No modifications of the method were made after the trial began. Recruitment and enrollment of patients were performed from August 2016 to March 2018. The trial was designed in accordance with the following:

- The World Medical Association's Declaration of Helsinki
- Clinical Investigation of Medical Devices for Human Subjects-Good Clinical Practice (ISO 4155:2011)
- Guidelines of Good Clinical Practice (2001/20/EC).

The study protocol was approved by the Scientific Committee of Hama University (approval on 8th of June, 2016).

After receiving oral and written information about the study and before participating, all patients eligible for the study and willing to take a part provided written consent.

### 2.2 Participants

Thirty-two patients took part in this study, each of them requiring the extraction of one or more mandible single root tooth (premolar 1 or 2). The indication for the extraction was the severe destruction because of caries or trauma. All patients visited the Oral and Maxillofacial Surgery department's clinic in the Faculty of Dentistry, Hama University for a teeth extraction. Depending on the clinical examination, a tooth or more needed to be extracted. The patients were first verbally informed by the clinical examiner about the possibility of taking part in the trial. The written information for patients was handed out afterwards. Patients provided informed consent at the next appointment, if they wanted to take part in the study.

Participation in the trial was also subject to the following conditions:

- Age over 18 years, as the participants had to be legally competent.
- Non-smoker status or smoking fewer than 10 cigarettes/day.
- No administration of bisphosphonates.
- No pregnancy.
- No alcohol or drug abuse.

- No infectious disease, such as hepatitis or human immunodeficiency virus (HIV) and/or acquired immunodeficiency syndrome (AIDS).
- No uncontrolled severe diabetes mellitus. In patients with diabetes.

All patients were recruited at the OMFS (Oral and Maxillofacial Surgery) department's clinic. All interventions and follow-up assessments were performed at this clinic by the clinical investigator who was the only dentist who treated all participating patients.

### 2.3 Interventions

All patients were treated under local anesthesia (huons Lidocaine 2%: 1:80,000, Sampyeong-dong, InnoValley Korea). Periostomes were used for atraumatic extraction and removal of the teeth after complete mobilization. The alveolus in the area of extraction was then carefully curettage and rinsed with sterile sodium chloride solution. No further measures were taken in the control group. In the ARP group, a  $\beta$ -TCP (CERASORB®, Nuremberg, Germany) were inserted in accordance with the manufacturer's instructions. This synthetic graft material has particle size of granules between 100-150  $\mu$ m it is a pure phase  $\beta$ -TCP it is completely resorbed in 4-12 months and it is porous scaffold during that time helps the natural bone-forming to occur. It does not contain HA (Hydroxy apatite) so its resorption occurs completely uniformly and parallel to the formation of the surrounding bone. The granules are radio opaque resorbing gradually from the inside to outside so it is easy to monitor the status of grafted site. A full thickness mucoperiosteum envelope flap was elevated. The soft tissue was mobilized to insure the alveolus was primarily closed by mucosa. The  $\beta$ -TCP graft mixed with patient blood then inserted into the alveolus with little pressure. A cross mattress suture was applied to stabilize the position flap edges using silk braded 3/0 suture material. The wounds were visually inspected after 1 week. At that time, the suture was removed from the patients in the ARP group.

After extraction, all patients received the following instructions for care for the next 24 hours:

- Avoid eating until the anesthetic effect subsides.
- Abstain completely from alcohol, coffee, and caffeinated drinks and cigarettes or other smoking products.
- Avoid rinsing the extraction wound to keep the blood clot in place.
- Avoid manual manipulation of the wound (e.g., pulling the lip, rigorous cleaning of the wound, etc.).

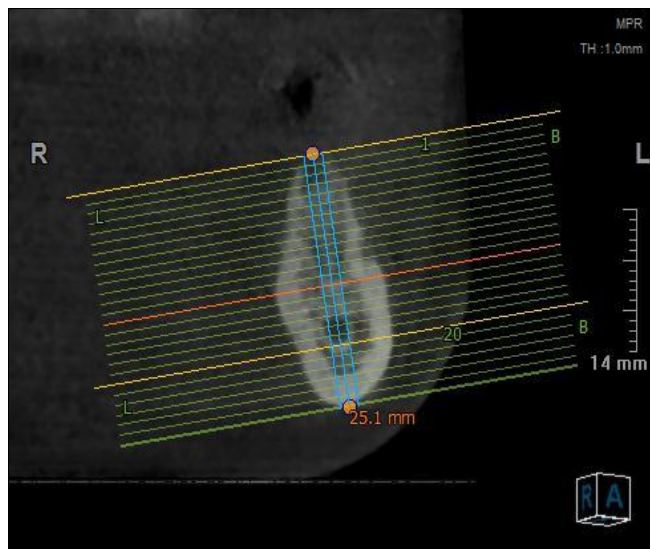
The patients were prescribed 600 mg of ibuprofen for pain reduction, to be self-administered as needed. No prophylactic antibiotics were prescribed. A provisional interim prosthesis was applied in exceptional cases only (e.g., for aesthetics when the front teeth were involved or for function where multiple teeth were lost) only for the patients who requested to receive implant therapy, the implants was fitted after 11 ( $\pm$ 1) weeks. While for the patients who planned for fixed bridge it was fitted after 4 ( $\pm$ 1).

### 2.4 Outcomes

The objective of this study was to determine the extent of resorption of the alveolar bone in the post-extraction alveolus area. The bone height was inspected at the time of the extraction (T0) and after a healing time of 12 ( $\pm$ 1) weeks (T1) and after a healing time of 24 ( $\pm$ 1) weeks (T2).

A cone-beam computed tomography (CBCT) image (vatech smart, Vatech Dental Systems, Korea) with a resolution of 0.1 voxels was produced at time T0, T1 and T2. This image was used for making measurements of the alveolar height and was the basis for the template-guided implantation if implant placement was planned, which was performed at 11 ( $\pm 1$ ) weeks after tooth extraction.

Quantitative measurements of the alveolar height were performed using (Ez-3D Plus 2009 Vatech Dental Systems, Korea) software (Figure 1). The measurements was made on the Axial sections at the center of the alveoli.



**Fig 1:** The measuring method on Axial sections using (Ez-3D Plus 2009 Vatech Dental Systems, Korea) software

**2.5 Sample size**

Due to a lack of clinical data, case numbers could not be estimated in advance. To achieve high clinical significance, 32 patients who required 40 single root tooth extraction (20 ARP and 20 control) from the mandible participated in the trial. The determination of the number of cases was based on similar studies, which, however, investigated the feasibility of other materials for ARP [8,16]. From the biostatistical point of view, the trial was of an exploratory nature. Thus, all outcomes from the statistical tests must be interpreted as generating hypotheses and not as a proof of efficacy. We performed a post hoc power analysis to provide a basis for future comparative studies.

**2.6 Randomization**

The randomization was done by flip a coin to determine in which group the tooth is going to be in ARP group or control group.

**2.7 Blinding**

Blinding of the socket treatment was not possible. However, the digital datasets acquired from the CBCT images taken at T0, T1, and T2 were forwarded to the analyst (ID) in blinded and anonymized form. Deblinding was performed only after completion of the analysis, documentation, and statistical analysis. The deblinding was performed locally and by individuals who were not involved in the analysis.

**2.8 Statistical methods**

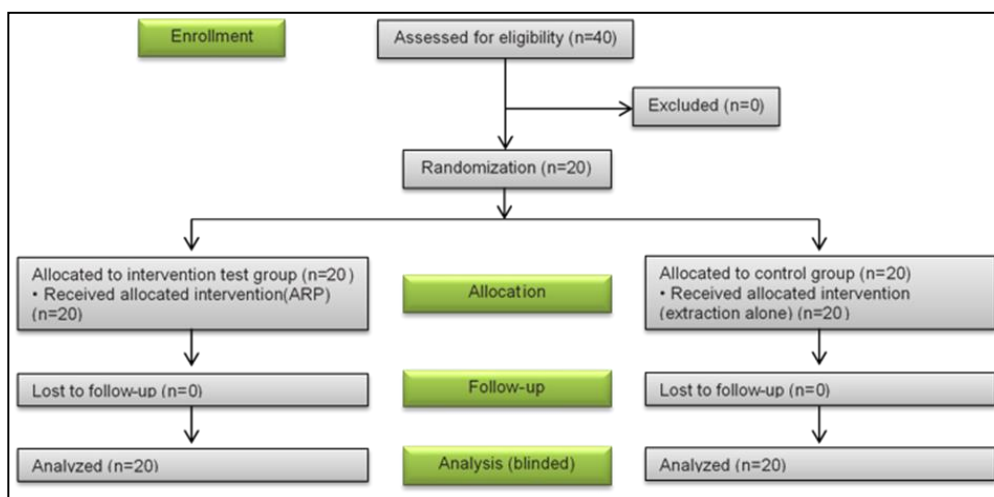
The maxima, medians, are reported for the metric target parameters.

The differences between the ARP and control groups were analyzed using the Wilcoxon rank-sum test. Due to the exploratory nature of the trial, all outcomes of statistical tests must be interpreted as generating hypotheses and not as proof. All statistical tests were performed at a significance level of  $\alpha=0.05$  (2-tailed) (Minitab®18). There was no adjustment for multiple testing. The power analysis and calculation of the sample size were carried out using the Proc Power feature of Minitab®18 For sample size calculation, a power of 80% and a 2-sided type 1 error of  $\alpha=0.05$  were assumed. For the post hoc power analysis, a 2-sided type 1 error of  $\alpha=0.05$  was assumed. All calculations were based on means and standard deviations.

**3. Results**

All patients were treated according to the clinical protocol (Figure 6). There were no postoperative complications. All enrolled patients completed the trial. Forty single root teeth from the mandible at 32 patients were extracted. Twenty tooth were assigned to the APR group as a result of randomization. Twenty tooth formed the control group and underwent extraction without further concomitant measures. The mean patient age was 42.3 years (range, 24–58 years).

The analysis revealed significantly less bone height resorption was detected in the ARP group after three and six months. The median bone height reduction after three months was  $1.29 \pm 0.25$  mm in the ARP group and  $2.89 \pm 0.49$  mm in the control group ( $P = 0.032$ ). And the median bone height reduction after six months was  $1.78 \pm 0.32$  mm in the ARP group and  $3.93 \pm 0.51$  mm in the control group ( $P = 0.041$ ).



**Fig 2:** Follow diagram of this randomized trial comparing extraction alone to a ridge preserving procedure of alveolar bone after tooth extraction

### 3.1 APR: Alveolar ridge preservation

No significant reduction in the bone height degeneration of the teeth was observed in the ARP group after three and six months (Table 1). However, the examination of the tooth regions highlighted a massive reduction of the bone height in

the teeth in the control group after both three and six months, with a median value of  $2.89 \pm 0.49$  and  $3.93 \pm 0.51$  mm respectively (ARP group:  $1.29 \pm 0.25$  mm and  $1.78 \pm 0.32$  mm) (Figure 3), (control: 1.35 mm, ARP: 1.10 mm).

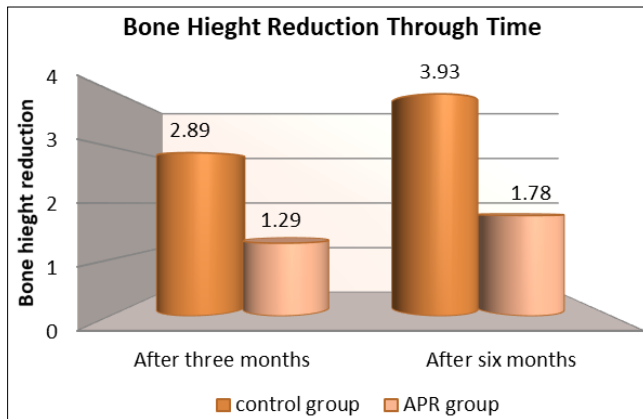
**Table 1:** Bone degeneration after tooth extraction in the ARP group and control group, including the maxima, medians.

Parameter	Time	Group	Cases No.	Median	Standard Deviation	Max	Min	P Value
Bone height changes	Three months post surgery	APR	20	1.29	0.25	2	1	0.032
		Control	20	1.78	0.32	3.8	1.9	
	Six months post surgery	APR	20	2.61	0.44	2.5	1.3	0.041
		Control	20	3.93	0.51	4.6	2.9	

The distances are reported in millimeters (mm). The total sample size was 40 patients (20 ARP and 20 control)

ARP: alveolar ridge preservation.

a) Statistically significant differences at  $P < 0.05$ , Wilcoxon rank-sum test.



**Fig 3:** Significantly less bone degeneration was found along the alveolar ridge height in the ARP group (mm).

APR: Alveolar ridge preservation.

## 4. Discussion

This trial was designed in such a way that post-extraction changes in the mandible alveolus were compared to a healing process without external influences as a baseline. Moreover, a non-invasive procedure was implemented for data acquisition, which also permitted independent review and testing of the outcomes.

The outcomes in this trial revealed a significant difference in the alveolar bone reduction at three and six months post-surgery between alveoli treated with the insertion of  $\beta$ -TCP material and untreated alveoli. Bone height degeneration differed significantly between the control and ARP groups after three months ( $1.29 \pm 0.25$  mm and  $2.89 \pm 0.49$  mm respectively ( $P = 0.032$ )). And also after six months ( $1.78 \pm 0.32$  mm and  $3.93 \pm 0.51$  mm respectively ( $P = 0.041$ )).

Bone height reduction after tooth extraction appeared more pronounced on the CBCT images than in clinical measurements using periodontal probes or similar measurement devices. For example, the mean bone height degeneration in control patients was measured as the difference between CBCT-based measurements before extraction and at 3 months post-extraction, has been reported as 5.36 mm for single-rooted teeth and 5.89 mm for multi-rooted teeth [10].

A further trial based on the analysis of CBCT images revealed comparable results: the mean reduction of bone height 8 weeks after tooth extraction was 5.2 mm (range, 0.7–12.2) [2]. The magnitude of bone height loss was also confirmed in this trial. Conversely, a meta-analysis based primarily on clinical measurement outcomes reported buccal bone reductions of  $-1.1$  to  $-3.5$  mm in the test groups and  $-1.0$  to  $-4.2$  mm in the

control groups [17].

The hypothesis that the application of the  $\beta$ -TCP material would lead to a reduction in bone degeneration after tooth extraction was therefore confirmed.

The power analysis calculated in this study showed that a sample size of 40 tooth at 32 patients, using the linear measurement method, would be needed to detect differences in clinically relevant bone height degeneration. The number of cases used in this study can therefore be regarded as sufficient.

Numerous clinical studies have used different clinical or radiological measurement methods in addition to diverse materials and surgical methods for ARP [5,8,16]. Consequently, standardized measurement protocols in trial designs have been called for [1]. The protocol used in this trial, which involved the measurement of alveolar changes after three and six months after surgery using CBCT, appears to be appropriate. A possible source of error with the use of CBCT data for bone modeling may be the detectability of incompletely mineralized bone. However, it was possible to demonstrate that marginal bone was visible in CBCT images with an accuracy of 0.6 mm, and that this measurement exhibited high reliability [18]. The ability to validate and reproduce the measurements must also be regarded as strengths of this method [13].

In the authors' opinion, methods involving digitalization and semi-automated software analysis offer significant benefits in terms of reproducibility, and they facilitate higher comparability than clinical measurement with probes. The method described in this study appears to offer lower rates of error and deviation due to measurement errors [22].

The choice of measurement time ( $T_1$ ,  $T_2$ ) and the condition of the healed alveolar bone have a significant effect on the assessment of the outcomes. It was expected that after 3 months, bone healing would not be complete [3]. The 3 months time point was chosen in the present trial to detect the ability of early implantation after grafting the alveoli (6 months post extraction), which would allow patients to benefit from the potential advantages of this timing [13].

In addition, differences in surgical methods affect bone resorption outcomes. For example, even the choice to close the alveolus using primary wound closure or by covering the alveolus with a membrane has a significant effect on wound healing [11].

A further external factor is the type of defect, which further complicates comparability. Classifications into defined defect classes after tooth extraction (for example, according to the number and state of the alveolar walls or the defect size itself) would be useful [19]. The thickness of the alveolar walls could

also have a major effect on healing and regeneration and/or the ARP procedures<sup>[4]</sup>. However, under clinical conditions, the ability to determine the extent of the defect before surgery is limited. In the same way, it is almost impossible to reproduce the assessment of the alveolus in the context of a clinical trial. A CBCT image taken before tooth extraction could supply this information, but such imaging is generally ruled out for ethical reasons and to minimize radiation exposure. In such cases, it would be suitable to use the relevant recommendations to improve trial quality for future research<sup>[20, 21]</sup>.

Currently, it must be assumed that ARP measures cannot entirely prevent the loss of bone tissue; however, it appears that appropriate measures can reduce it. Minimizing bone resorption requires further research, and there is a need for procedures that match patients' individual situations with materials that are appropriate to the indication. One of the main indications for ARP is the potential prevention of the need for additional interventions in the form of augmentations. In addition to preventing the risks and side effects of additional surgery, ARP might also lead to improvements in the cost-to-benefit ratio and patient comfort. In conclusion, the proposed hypothesis, according to which there would be a difference in bone reduction between alveoli treated with  $\beta$ -TCP material and untreated alveoli, can be accepted based on the outcomes of this trial. This hypothesis predicted improved bone preservation as a result of the implantation of the  $\beta$ -TCP material. Significantly less bone resorption was detected in the bone height of the ARP group. Therefore, the use of the  $\beta$ -TCP material can be recommended based on the available data.

## 5. References

1. Tan WL, Wong TL, Wong MC, Lang NP. A systematic review of post-extraction alveolar hard and soft tissue dimensional changes in humans. *Clin Oral Implants Res.* 2012; 23(5):1-21.
2. Chappuis V, Engel O, Reyes M, Shahim K, Nolte LP, Buser D. Ridge alterations post-extraction in the esthetic zone: a 3D analysis with CBCT. *J Dent Res.* 2013; 92:195S-201S.
3. Schmidlin PR, Jung RE, Schug J. Prevention of alveolar ridge resorption after tooth extraction--a review. *Schweiz Monatsschr Zahnmed.* 2004; 114:328-36.
4. Iyer S, Haribabu PK, Xing Y. Part II. Minimizing alveolar bone loss during and after extractions. Protocol and techniques for alveolar bone preservation. *Alpha Omegan.* 2014; 107:14-25.
5. Mardas N, Chadha V, Donos N. Alveolar ridge preservation with guided bone regeneration and a synthetic bone substitute or a bovine-derived xenograft: a randomized, controlled clinical trial. *Clin Oral Implants Res.* 2010; 21:688-98.
6. Trombelli L, Farina R, Marzola A, Bozzi L, Liljenberg B, Lindhe J. Modeling and remodeling of human extraction sockets. *J Clin Periodontol.* 2008; 35:630-9.
7. Sanz I, Garcia-Gargallo M, Herrera D, Martin C, Figuero E, Sanz M. Surgical protocols for early implant placement in post-extraction sockets: a systematic review. *Clin Oral Implants Res.* 2012; 23(5):67-79.
8. Ten Heggeler JM, Slot DE, Van der Weijden GA. Effect of socket preservation therapies following tooth extraction in non-molar regions in humans: a systematic review. *Clin Oral Implants Res.* 2011; 22:779-88.
9. Misch CE, Dietsh-Misch F, Misch CM. A modified socket seal surgery with composite graft approach. *J Oral Implantol.* 1999; 25:244-50.
10. Crespi R, Capparè P, Gherlone EF. Bone recontouring in fresh sockets with buccal bone loss: a cone beam computed tomography study. *Int J Oral Maxillofac Implants.* 2014; 29:863-8.
11. Vittorini Orgeas G, Clementini M, De Risi V, de Sanctis M. Surgical techniques for alveolar socket preservation: a systematic review. *Int J Oral Maxillofac Implants.* 2013; 28:1049-61.
12. Pagni G, Pellegrini G, Giannobile WV, Rasperini G. Postextraction alveolar ridge preservation: biological basis and treatments. *Int J Dent.* 2012; 2012:151030.
13. Lambert F, Vincent K, Vanhoutte V, Seidel L, Lecloux G, Rompen E. A methodological approach to assessing alveolar ridge preservation procedures in humans: hard tissue profile. *J Clin Periodontol.* 2012; 39:887-94.
14. Moher D, Schulz KF, Altman DG consort. The Consort statement: revised recommendations for improving the quality of reports of parallel group randomized trials. *BMC Med Res Methodol.* 2001; 1:2.
15. Moher D, Hopewell S, Schulz KF, Montori V, Gøtzsche PC, Devereaux PJ *et al.* Consort 2010 Explanation and Elaboration: Updated guidelines for reporting parallel group randomised trials. *J Clin Epidemiol.* 2010; 63:e1-37.
16. Fickl S, Zuhr O, Wachtel H, Stappert CF, Stein JM, Hürzeler MB. Dimensional changes of the alveolar ridge contour after different socket preservation techniques. *J Clin Periodontol.* 2008; 35:906-13.
17. De Avila ED, Filho JS, de Oliveira Ramalho LT, Real Gabrielli MF, Pereira Filho VA. Alveolar ridge augmentation with the perforated and nonperforated bone grafts. *J Periodontal Implant Sci.* 2014; 44:33-8.
18. Leung CC, Palomo L, Griffith R, Hans MG. Accuracy and reliability of cone-beam computed tomography for measuring alveolar bone height and detecting bony dehiscences and fenestrations. *Am J Orthod Dentofacial Orthop.* 2010; 137:S109-19.
19. Seibert JS, Cohen DW. Periodontal considerations in preparation for fixed and removable prosthodontics. *Dent Clin North Am.* 1987; 31:529-55.
20. De Buitrago JG, Avila-Ortiz G, Elangovan S. Quality assessment of systematic reviews on alveolar ridge preservation. *J Am Dent Assoc.* 2013; 144:1349-57.
21. Hämmerle CH, Araújo MG, Simion M. Osteology Consensus Group 2011. Evidence-based knowledge on the biology and treatment of extraction sockets. *Clin Oral Implants Res.* 2012; 23(5):80-2.
22. Schulze R, Heil U, Gross D, Bruellmann DD, Dranischnikow E, Schwanecke U *et al.* Artefacts in CBCT: a review. *Dentomaxillofac Radiol.* 2011; 40:265-73.