



International Journal of Applied Dental Sciences

ISSN Print: 2394-7489
ISSN Online: 2394-7497
IJADS 2019; 5(3): 360-365
© 2019 IJADS
www.oraljournal.com
Received: 04-05-2019
Accepted: 08-06-2019

Dr. Munaif V

Department of Orthodontics and
Dentofacial Orthopaedics, JSS
Dental College and Hospital
Mysuru, Karnataka, India

Dr. Raghunath N

Department of Orthodontics and
Dentofacial Orthopaedics, JSS
Dental College and Hospital
Mysuru, Karnataka, India

Dr. Jyothikiran H

Department of Orthodontics and
Dentofacial Orthopaedics, JSS
Dental College and Hospital
Mysuru, Karnataka, India

Dr. Naveen Chandran

Department of Orthodontics and
Dentofacial Orthopaedics, JSS
Dental College and Hospital
Mysuru, Karnataka, India

Dr. Sanjeed Kabeer

Department of Orthodontics and
Dentofacial Orthopaedics, JSS
Dental College and Hospital
Mysuru, Karnataka, India

CBCT: A break through in orthodontic diagnosis

Dr. Munaif V, Dr. Raghunath N, Dr. Jyothikiran H, Dr. Naveen Chandran and Dr. Sanjeed Kabeer

Abstract

The advent of CBCT has opened newer avenues and has improved the accuracy of diagnosis and treatment in orthodontics. 3D imaging is quickly emerging as the standard of care in orthodontics as new ultralow-dose CBCT technology offers safer and more affordable volumetric scanning than ever before.

Keywords: CBCT, diagnosis

Introduction

Cone beam technology was first introduced in the European market in 1996 by QR s.r.l. (New Tom 9000) and into the US market in 2001. October 25, 2013, during the "Festival della Scienza" in Genova, Italy, the original members of the research group: Attilio Tacconi, Piero Mozzo, Daniele Godi and Giordano Ronca received an award for the cone-beam CT invention. 3D imaging is quickly emerging as the standard of care in orthodontics as new ultralow-dose CBCT technology offers safer and more affordable volumetric scanning than ever before. The advantages of CBCT over traditional 2D imaging are numerous. The advent of CBCT has opened newer avenues and has improved the accuracy of diagnosis and treatment planning in growing patients. The images of head and neck are obtained in all 3 planes, including cervical vertebrae, with the use of CBCT. As a result of recent advances in the field of radiology, cone-beam computed tomography (CBCT) is becoming more popular as an investigating tool for orthodontic patients.

Why 3D??

A conventional X-ray image is basically a shadow. Shadows give you an incomplete picture of an object's shape. This is the basic idea of computer aided tomography. In a CT scan machine, the X-ray beam moves all around the person, scanning from hundreds of different angles.




Fig 1: 3 dimensional imaging

1. 3D treatment planning and the transverse dimension
2. Airway centered treatment from information not available using 2D imaging
3. Improved pre-existing TMJ knowledge and avoiding surprises during treatment
4. Mixed dentition and eruption guidance in 3D imaging
5. Visual Craniometric Analysis (VCA) – a new paradigm in 3D Cephalometrics

Correspondence

Dr. Munaif V

Department of Orthodontics and
Dentofacial Orthopaedics, JSS
Dental College and Hospital
Mysuru, Karnataka, India

How CBCT works??



Fig 2: CBCT machine

and current to provide the x ray tube with the power needed to produce an x ray beam of desired peak kilo voltage (kVp) and current (mA). X ray tube anode cathode tube envelop tube housing Collimator Size of the anode matters. smaller the size of the anode intensity of the x ray increases

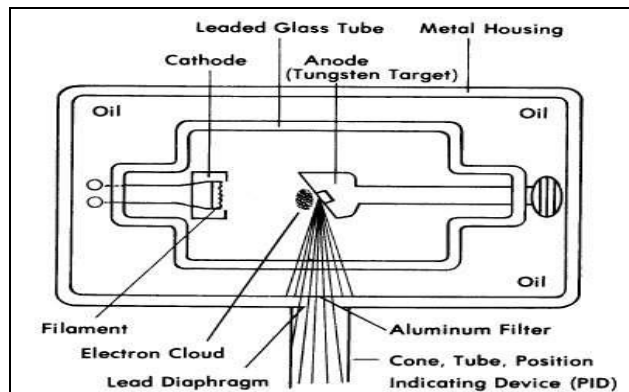


Fig 4: x- ray generator

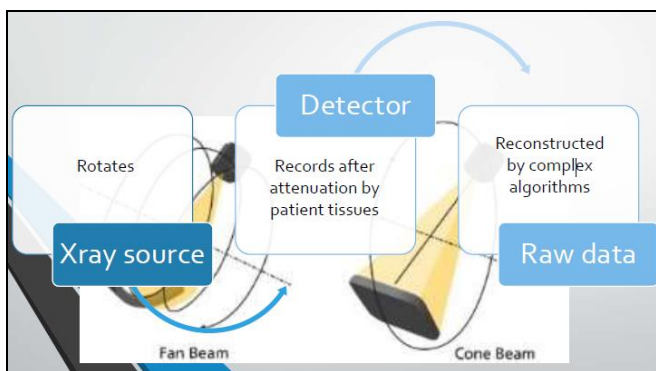


Fig 3: Process of CBCT

- Exposure factors can be controlled manually or automatically
- Scout images
- KvP 60 to 90
- mA 6 to 10
- Pulsed or continuous x ray generation
- 180 or 360 degree rotation of the x ray generator and sensor

Image sensor

- PSP (Photo stimulable phosphorus plates)
- CCD sensors
- FPD (Flat panel detector)

Direct
Indirect

A sensor which has smaller pixel size has better resolution. One pixel can be 0.007 to 0.3mm size. A sensor which has a higher bit rate, can identify more areas of black and white.

Image reconstruction

Steps in image reconstruction are

Component of CBCT

- X-ray generator
- Image sensor
- Image reconstruction

X-ray generator

- High voltage generator which modifies incoming voltage

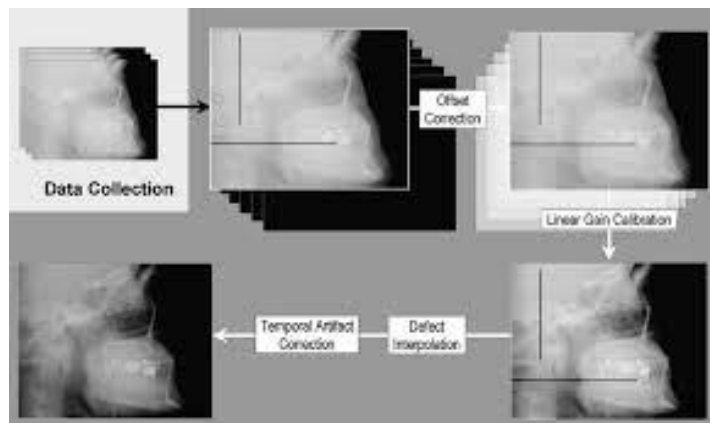


Fig 5: Image re construction

What is field of view (FOV)???

Collimation of x ray beam by adjustment of FOV limits the radiation to one ROI. These depend on the detector size and

shape, beam projection geometry and the ability to collimate or not. It is desirable to limit the field size to the smallest volume that can accommodate the region of interest.

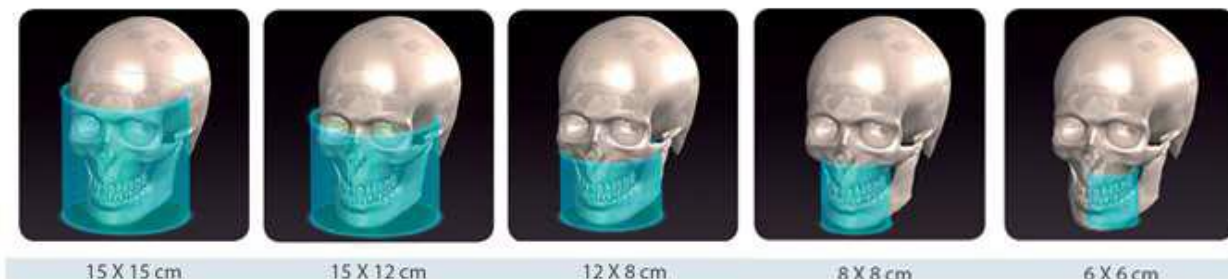

Fig 6: Different FOVs

Effective radiation dosage

FOV>15 cm	52 to 1073 μSv
FOV 10 to 15cm	61 to 603 μSv
FOV of < 10 cm	18 to 333 μSv
Multislice CT	426-1600 μSv
Panaromic	6-50 μSv
Cephalogram	2 -10 μSv
IOPA	2-8 μSv

American academy of oral and maxillofacial radiology (AAOMR)

Advantages and disadvantages of CBCT

Advantages	Disadvantages
Rapid scan time	Scatter
Beam limitation	Motion artifacts due to increased scan time
Image accuracy	Scan volume in sufficiency
Reduction in patient radiation dose when compared to medical CT	Poor contrast resolution, thus soft tissue cannot be viewd
Interactive display modes	Image noise is detrimental
Better images with good spatial resolution	Increase in radiation dose compared to conventional radiographs
comfortable and safe	Less economical

Applications of CBCT in orthodontics

1. Impacted and transposed teeth

Most common indications for CBCT imaging in orthodontics. CBCT has been shown to improve diagnosis and contribute to modifications in treatment planning in a significant number of subjects.

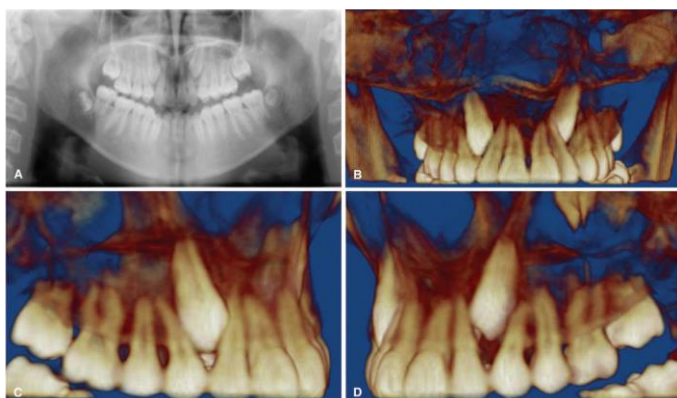


Fig 7: CBCT of canine impaction

Depiction of impacted maxillary canines using a conventional 2D panorex (A) and 3D volumetric rendering. The 3D images permit clear visualization of the location and relationships of

the impacted canines to adjacent structures, as well as the presence of any root resorption. It facilitates treatment decisions, including determination of teeth to be extracted. If yes then the optimal surgical approach, appropriate placement of attachments, and biomechanics planning.

2. Cleft lip and palate

valuable in determining the volume of the alveolar defect and therefore, the amount of bone needed for grafting in CL/P patients for determining the success of bone fill following surgery (Oberoi *et al.*, 2009; Shirota *et al.*, 2010) [23, 26]. Numbers, quality, and location of teeth in proximity to the cleft site (Zhou *et al.*, 2013) [25], The eruption status and path of canines in grafted cleft sites (Oberoi *et al.*, 2010) [24]

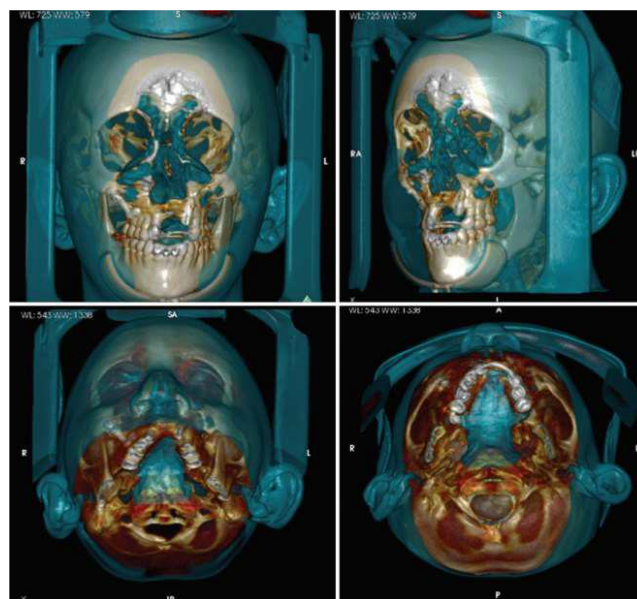


Fig 8: CBCT of cleft lip and palate

3D volumetric reconstructions of a patient with bilateral CL/P are useful in obtaining detailed information on the magnitude of the defect and the status and position of teeth at the defect site.

3. Orthognathic and craniofacial anomalies surgical planning and implementation

CBCT combined with computer-aided surgical simulation (CASS) or Computer-aided Orthognathic surgery (CAOS) offers

- Refining diagnosis and optimizing treatment objectives in 3D
- Virtual treatment planning to improve surgical procedures and outcomes.

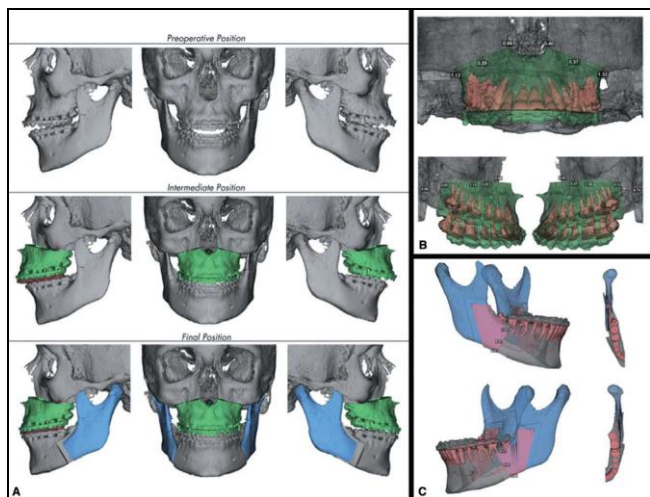


Fig 8: CBCT images of craniofacial anomalies

Virtual surgical treatment planning for a patient to visualize and determine the magnitude of maxillary and mandibular movements, as well as any complication such as proximal segment interferences that may arise during surgery.

4. Asymmetry

3D CBCT imaging in the diagnosis and treatment planning of asymmetries, where discrepancies often manifest in all three planes of space. When large differences exist between bilateral structures, CBCT scans enable the use of a technique called “mirroring”. In which the normal side is mirrored onto the discrepant side so as to simulate and visualize the desired end result, as well as to plan the surgery to facilitate correction (Metzger *et al.*, 2007) [20]

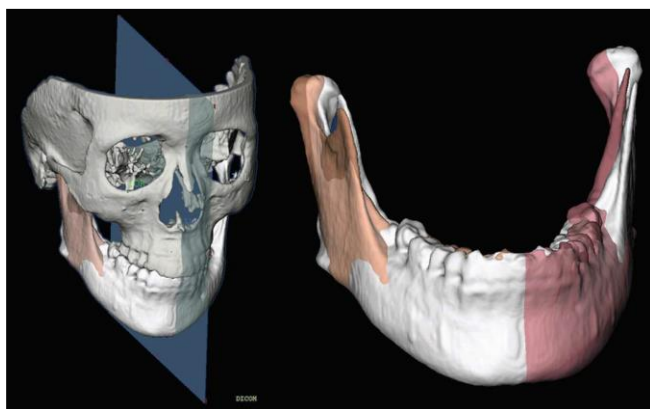


Fig 9: CBCT of facial asymmetry

Mirroring on a mid-sagittal plane for quantitation of mandibular asymmetry. A midsagittal plane was defined for this patient based on Na, Ba, and ANS. The left ramus was mirrored onto the right side using this plane.

Limitation of mirroring

Mirroring using mid-sagittal plane generates and clinically irrelevant results for patients

1. Cleft palate with facial features that affect the midline position of the points (NA, ANS, Ba) used to define this plane.
2. In patients with asymmetries involving the cranial base,

registration on the cranial base also results in suboptimal results.

This implies that patient specific methods may be indicated for optimal localization and quantification of mandibular asymmetries.

5. Root resorption

Detection of buccal or lingual root resorption by CBCT that is not visualized by 2D radiographs could differentiate pre- or in-treatment decisions made with the two imaging modalities. So the dilemma, in this scenario is how and when a clinician would decide that a patient has undergone buccal and/or lingual root resorption to justify taking CBCT scan.

6. Alveolar boundary conditions

Compromised pretreatment alveolar boundary conditions may limit or interfere with the planned or potential tooth movement, as well as the final desired spatial position and angulation of the teeth. Failure to diagnose compromised alveolar bone prior to treatment and to involve this into the treatment plan likely will lead to worsening of the problem during orthodontic treatment.

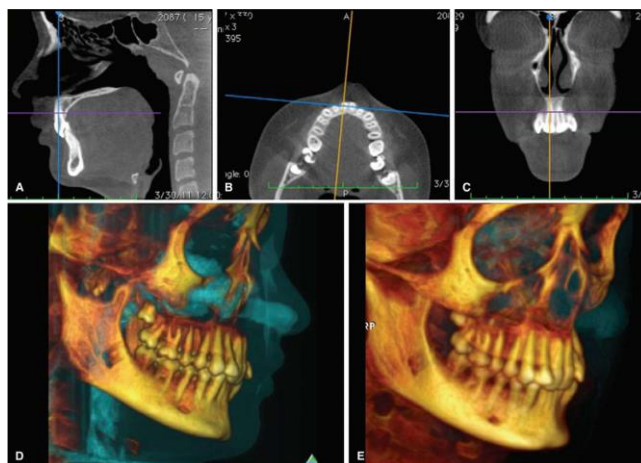


Fig 10: CBCT showing alveolar boundary conditions

Determination of anterior boundary conditions in a case with severely retroclined maxillary and mandibular incisors using sagittal (A), axial (B) and coronal (C) multiplanar, and 3D volumetric (D and E) reconstructions. A severe Class II division 2 malocclusion presents with upper incisor roots that have limited buccal bone support that could be placed into a better relationship with the bone

7. TMJ degeneration, progressive bite changes functional shifts, and responses to therapy

Conventional 2D radiography of the TMJ including panoramic radiographs and cephalograms do not provide an accurate characterization of the joint because of distorted images with superimposed structures. CBCT imaging of entire joint spaces with visualization of osseous hard tissue morphologic changes resulting from pathology and adaptive processes allows for accurate detection and evaluation of pathological changes.

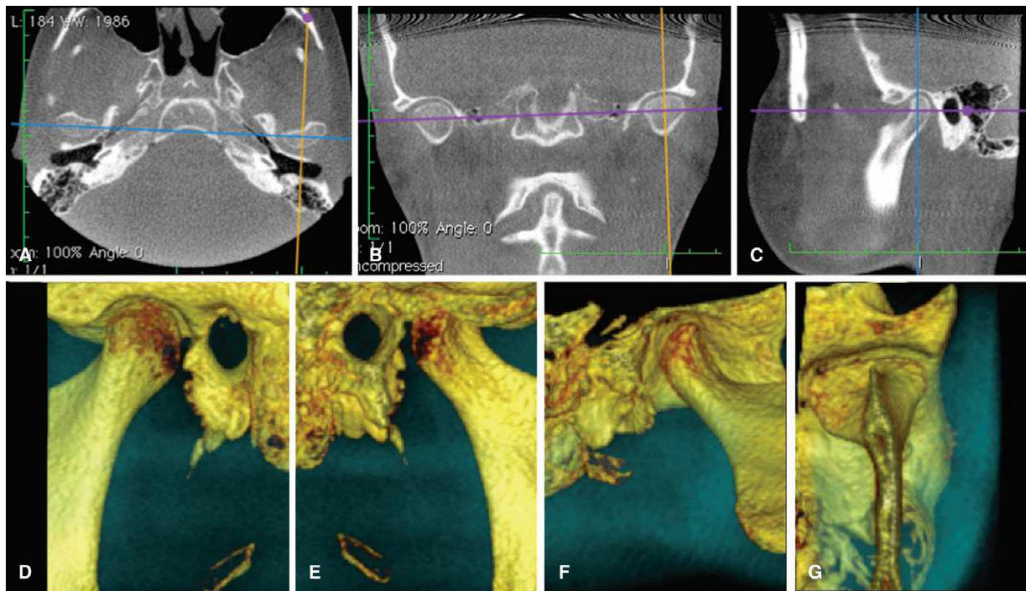


Fig 11: CBCT images of TMJ disorders

Visualization of the TMJ in the axial (A), coronal (B), and sagittal (C) planes, as well as 3D volumetric reconstructions here visualized from the buccal (D), medial (E), medio-inferior (F), and anteroinferior (G) in 3D can help in the identification of pathologic changes, including sclerosis, flattening, erosions, osteophytes, abnormalities in joint spaces, and responses of the joint tissues.

Conclusion

This technique hugely expands the fields for diagnosis and treatment possibilities, not to forget many more research frontiers as well. However CBCT should be used with careful consideration, it should not be used where 2D imaging suffices. The contributions of CBCT to the field of dentistry have been demonstrated in several studies of technology appraisal, in craniofacial morphology as it relates to health and disease, and in the usefulness of CBCT images for diagnosis, treatment planning, and treatment outcome. Accumulating evidence continues to demonstrate that CBCT is a valuable tool, and it is particularly important in cases where conventional radiography cannot provide adequate diagnostic information. The latter includes cases of cleft palate, craniofacial syndromes, supernumerary teeth, assessment of multiple impacted teeth, identification of root resorption caused by impacted teeth, and planning for orthognathic surgery. CBCT imaging may also be applied to other types of cases in which it is likely to provide valuable diagnostic information following verification of a positive benefit.

References

- Hatcher DC. Operational principles of cone beam computed tomography JADA, 2010.
- Joshi V, Yamaguchi Tetsutaro, Matsuda Yukiko, Kneko Norikazu, Maki Kotarou, *et al*. Skeletal maturity assessment with use of cone beam computed tomography J of oral and Maxillofacial Radiology. 2012; 113; 6:841-849.
- White, Pharrow. Oral radiology edition. 2014, 7.
- European SEDENTEXCT guidelines for CBCT, 2012.
- ICRP-international commission on radiological protection publication, 2007.
- American academy of oral and maxillofacial radiology, 2009.
- Prima Immagine. Cone-Beam-1994-07-01-3" by Daniele Godi - Own work.
- Hatcher DC. Operational principles of cone beam computed tomography JADA, 2010.
- Incidental findings arising with cone beam computed tomography imaging of the orthodontic patient, Sheelagh *et al*, Angle Orthodontist. 2011; 81:2.
- Diagnostic accuracy of 2 cone-beam computed tomography protocols for detecting arthritic changes in temporomandibular joints, Sumit Yadav, Am J Orthod Dentofacial Orthop, 2015.
- Impact of cone-beam computed tomography on orthodontic diagnosis and treatment planning, Ryan J *et al*. Am J Orthod Dentofacial Orthop, 2013.
- Accuracy of cone-beam computed tomography in detecting alveolar bone dehiscences and fenestrations, Liangyan Sun *et al* Am J Orthod Dentofacial Orthop, 2015.
- Three-dimensional monitoring of root movement during orthodontic treatment, Robert *et al*, Am J Orthod Dentofacial Orthop, 2015.
- Comparison of transverse analysis between posteroanterior cephalogram and cone-beam computed tomography by Kyung- Min Lee *et al*, Angle Orthod, 2014.
- Accuracy, and reliability of cone-beam computed tomography measurements: Influence of head orientation, Amr Ragab *et al*, AJODO, 2011.
- Scarfe WC, Farmna AG, Sukovic P. Clinical applications of cone beam tomography in dental practice. J Can Dent Assoc. 2006; 72:75-80.
- Ludlow JB, Ivanovic M. Comparative dosimetry of dental CBCT devices and 64-slice CT for oral and maxillofacial radiology. Oral surg oral med oral pathol oral radiol endod. 2008; 106:106-114.
- Upadhyay M, Yadav S, Patil S. Mini-implant anchorage for en-masse retraction maxillary anterior teeth: A clinical cephalometric study. Am J orthod dentofacial orthop. 2008; 134:803-810.
- Jung BA, Wehrbein H, Wagner W *et al*. Preoperative diagnostic for palatal implants: is CT or CBCT necessary? Clinical implant dentistry and related research. 2012; 14(3):400-405.
- Metzger MC, Hohlweg-Majert B, Schon R *et al*.

- Verification of clinical precision after computer-aided reconstruction in craniomaxillofacial surgery. *Oral Surgery, Oral Medicine, Oral Pathology, Oral radiology and endodontology*. 2007; 104(4):e1-e10.
21. Walker L, Enciso R, Mah J. Three dimensional localization of maxillary canines with cone-beam computed tomography. *American journal of orthodontics and dentofacial orthopedics*. 2005; 128(4):418-423.
 22. Oberoi S, Chigurupati R, Gill P *et al*. Volumetric assessment of secondary alveolar bone grafting using cone beam computed tomography. *The Cleft Palate–Craniofacial Journal*. 2009; 46(5):503-511.
 23. Oberoi S, Gill P, Chigurupati R *et al*. Three-dimensional assessment of the eruption path of the canine in individuals with bone-grafted alveolar clefts using cone beam computed tomography. *The cleft palate–craniofacial journal*. 2010; 47(5):507-512.
 24. Zhou W, Li W, Lin J *et al*. Tooth lengths of the permanent upper incisors in patients with cleft lip and palate determined with cone beam computed tomography. *Cleft palate–craniofacial journal*. 2013; 50(1):88-95.
 25. Shirota T, Kurabayashi H, Ogura H *et al*. Analysis of bone volume using computer simulation system for secondary bone graft in alveolar cleft. *International journal of oral and maxillofacial surgery*. 2010; 39(9):904.