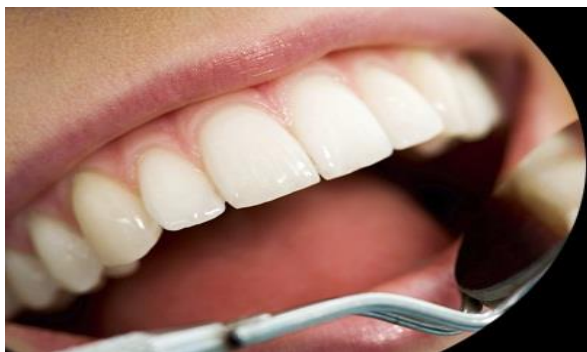



International Journal of Applied Dental Sciences

ISSN Print: 2394-7489
ISSN Online: 2394-7497
IJADS 2019; 5(4): 09-15
© 2019 IJADS
www.oraljournal.com
Received: 03-08-2019
Accepted: 06-09-2019

Dr. Siddharth Bhalchandra Deshmukh
Associate Professor, Yogita
Dental College and Hospital,
Khed, Ratnagiri, Maharashtra,
India

Dr. Kishor Sonawane
Professor and HOD, Yogita
Dental College and hospital,
Khed, Ratnagiri, Maharashtra,
India

Dr. Sheetal Korde
Professor, Ymt's Dental College
and Hospital, Navi Mumbai,
Maharashtra, India

Odontogenic keratocysts to keratocystic odontogenic tumor

Dr. Siddharth Bhalchandra Deshmukh, Dr. Kishor Sonawane and Dr. Sheetal korde

Abstract

Scientists from time to time have suggested multiple classifications and renamed Odontogenic keratocyst (OKC). Recently WHO classified OKC and renamed it as Keratocystic Odontogenic Tumor (KCOT) based on its behavior and aggressiveness. Studies have concluded that the role of various factors responsible to be calling it as a neoplasm, some of which are Loss of Heterozygosity (LOH), involvement of PTCH1 gene and expression of various factors and proteins. It is now well established that the OKC is an aggressive cystic lesion that has a propensity for recurrence if not adequately removed and may undergo malignant changes. In spite of several classifications and nomenclature the clinicians still have to face difficulties in the management of this commonly found jaw lesion. This article is an effort to provide an overview for different various aspects of OKC with emphasis on nomenclature and molecular. As these lesions included into a neoplasm hence should be treated as same. Various newer inhibitor drugs have been introduced for treatment of cancer might be useful for the treatment of aggressive cystic lesion like KCOT.

Keywords: Odontogenic keratocysts, keratocystic odontogenic

Introduction

Odontogenic cysts are one of the most common osseous-destructive lesions affecting the jaws. These cysts arise from the epithelial components of the odontogenic apparatus or its remnants that lie entrapped within bone or in the gingival tissue [1].

There is a considerable literature on possible mechanisms of cyst initiation and subsequent enlargement. Theories have ranged from the osmotic/hydrostatic pressure concept to differential growth and inflammatory mediators, such as prostaglandins and interleukins [2]. More recently, various angiogenic factors and secretory proteins are also implicated in the growth and expansion of cysts. Expression of these molecules in the epithelium and in connective tissue is related to different clinical and biological behavior of various types of odontogenic cysts.

OKC is a distinctive form of developmental odontogenic cyst that deserves special consideration because of its specific histopathologic features and biological behavior. The OKC is noteworthy because of its ability to attain a large size before any clinical signs and a symptom develops, its high recurrence rate and an association with Nevoid Basal Cell Carcinoma Syndrome (NBCCS) [3]. Most authors believe that dentigerous cyst (DC) and radicular cyst (RC) continue to enlarge as a result of increases osmotic pressure within the lumen of the cyst. This mechanism does not appear to hold true for OKC and their growth may be related to unknown factors inherent in the epithelium itself or enzymatic activity in the fibrous wall. The inflammatory exudates playing a negligible role in the OKC enlargement was pointed out in a number of studies [4].

Its aggressively invasive behavior has led some workers to suggest that it might be a benign neoplasm rather than a simple cystic lesion and a number of investigations have been undertaken to identify the molecular characteristics that determine the behavior of this lesion. An evidence of the neoplastic rather than developmental nature of OKC has been supplied by the presence of allelic imbalance of tumor suppressor genes in the majority of OKC [5].

Corresponding Author:
Dr. Siddharth Bhalchandra Deshmukh
Associate Professor, Yogita
Dental College and Hospital,
Khed, Ratnagiri, Maharashtra,
India

Infiltration And Invasion	Multicentric Growth Potential	
Self Sufficiency In Growth Signals	Intrinsic Growth Potential	Ki-67, PCNA, P-63
Insensitivity To Growth Inhibitory Signals:	Tumor Suppressor Genes	Loss of heterozyosity PTCH And SMO
Apoptosis	Bcl-2	
Angiogenesis And Invasion Into ECM	VEGF and MMP-9	
Epigenetic Changes		
Micro mRNAs		
High Recurrence Rate		

Nomenclature and classifications

Jaw cysts had hundreds of years of historical clinic pathological development, and it is believed that the first report of a jaw cyst dated back to 1774 by the anatomist John Hunter [1, 2].

OKC is an enigmatic developmental cyst, which Mikulicz in 1876 first described it as a part of familial condition affecting the jaws. However in 1926 it was first known as a cholesteatoma [2].

The term ‘primordial cyst’ was first used by Robinson (1945) to describe a cyst of the jaw that he was suggested to be derived from the enamel organ in its early stages of development by degeneration of the stellate reticulum before any calcified structures had been laid down³. He stated that primordial cysts may occur in single or multiple form arising either from an enamel organ of a single tooth of the regular series or from numerous aberrant dental anlage which become cystic.

The term ‘odontogenic keratocyst’ was coined by Philipsen in 1956 [2, 3, 4]. Reichart and Philipsen renamed OKC as keratinizing cystic odontogenic tumor (KCOT). The most recent classification of the World Health Organization (WHO) reallocated keratocyst within the classification of tumors under the term “Keratocystic Odontogenic Tumor” (KOT).

WHO has chosen to rename this cyst keratocystic odontogenic tumor, but some authors like Marx and Stern prefer to retain old terminology [5, 6].

Pindborg and Hansen were first to point out the aggressive behavior of OKC. Toller as early as 1967 suggested that OKC

should be considered as a benign neoplasm rather than a conventional cyst mainly because of their clinical behavior. Ahlfors and others in 1984 suggested OKC to be classified as a true benign cystic epithelial neoplasm. Shear labeled OKC as a benign cystic neoplasm. Regezi and others have attempted to explain the pathogenetic mechanisms of OKC [7].

Osmolality Cytokines and growth factors

Despite initiating the idea that the OKC might be a benign cystic neoplasm, Toller continued to believe that raised osmolalities played a role in the expansive growth of the cyst while an alternative view was that mural growth in the form of epithelial proliferation was the essential process involved in the enlargement⁴. The latter view was supported by others who believed that the multilocular and loculated outlines exhibited by some OKCs suggested a multicentric pattern of cyst growth brought about by the proliferation of local groups of epithelial cells against the semi-solid cyst contents [5].

Interleukin 1 (IL-1) and Tumour Necrosis Factor (TNF), cytokines that are particularly associated with chronic inflammatory lesions, had been shown to account for much of the bone resorbing activity attributed to osteoclast activating factor produced by mononuclear leukocytes. Studies on RCs and DCs were undertaken to investigate the possibility that IL-1 might be produced by odontogenic cysts and might account for the raised levels of prostaglandin and collagenase synthesis that had been demonstrated in cyst capsules [4, 5]. In a follow-up paper on OKCs it was pointed out that while in the RCs the stimulus for the production of IL-1 was presumed to be bacterial products, this was unlikely to be a factor in

OKCs. Considering that keratinocytes had been shown to synthesize IL-1 and IL-6 and that these cytokines and TNF had potent bone resorbing properties, it was postulated that these might account for raised levels of prostaglandin and collagenase synthesis by the uninflamed OKC capsule. They proposed therefore that IL-1a was the principal osteolytic cytokine produced by OKCs leading to bone resorption.

Following on earlier studies, it was shown that levels of IL-1a were significantly higher in the fluids of OKCs than in fluids of DCs and RCs. In this work there was focus on the effects IL-1a on both the secretion and activation of MMP-9 in odontogenic jaw cysts. OKC fragments in explant culture secreted considerably larger amounts of IL-1a than the other two cyst types and spontaneously secreted both proMMP-9 and an active form of MMP-9 [5]. The secreted proMMP-9 was also activated in the presence of IL-1a and plasminogen fluids. The results suggested that IL-1a may up-regulate not only proMMP-9 secretion but also proMMP-9 activation by inducing proMMP-3 and u-PA production in the epithelial

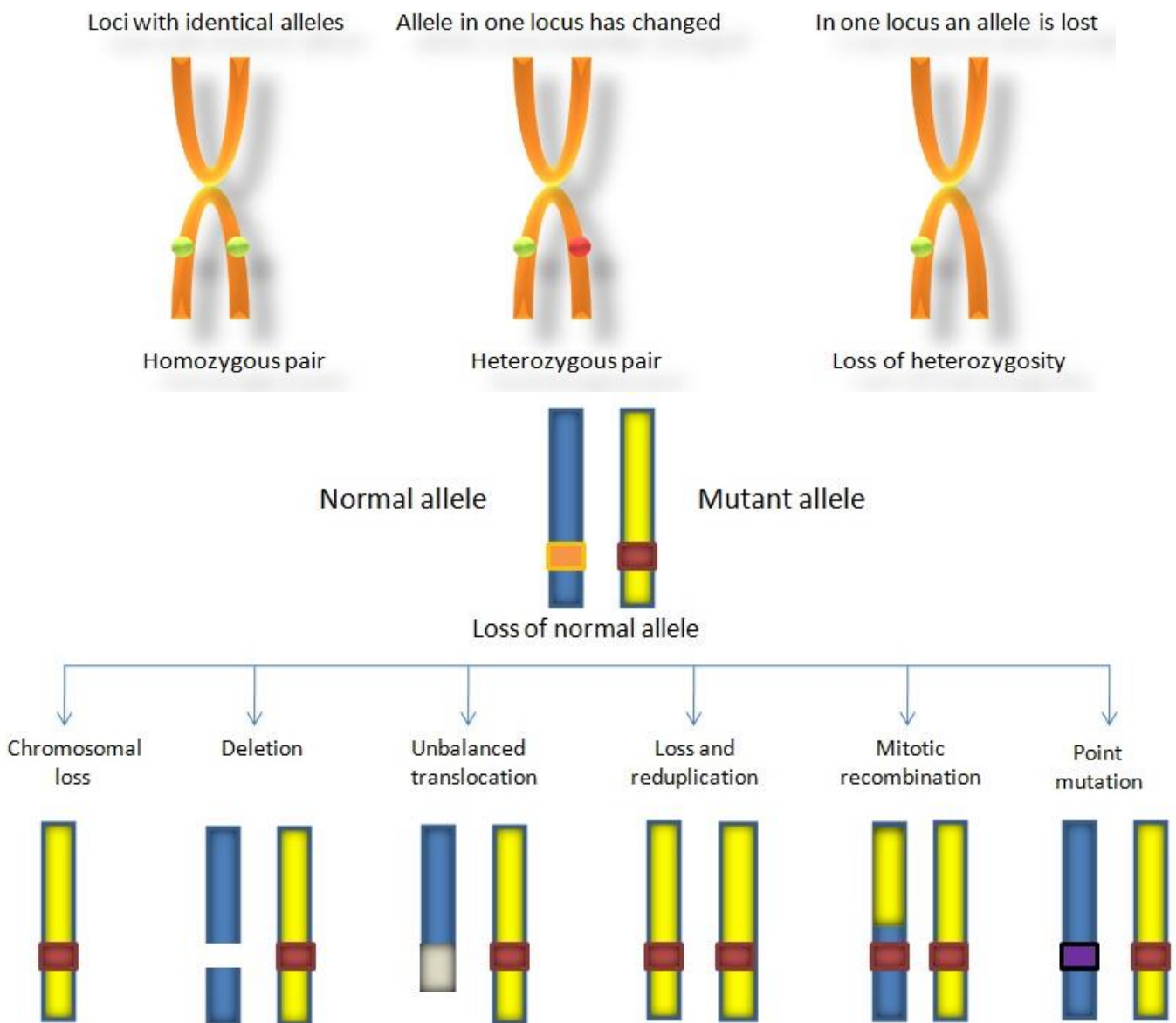
cells by autocrine/paracrine regulatory mechanisms [5, 7].

Loss of heterozygosity

Loss of genomic material in one of a pair of chromosomes is designated loss of heterozygosity (LOH). LOH at chromosomal regions supposed to contain tumor suppressor genes might be related to the process of malignant development, although it is recognized that the development of malignancies, in general, requires multiple genetic alterations (Renan, 1993) of oral lesions [7, 8].

Recently, some studies have focused on the molecular aspects of OKC. The neoplastic concept of OKC is supported by molecular studies that demonstrated the loss of heterozygosity [8, 9].

LOH is an important genetic mechanism, giving rise to neoplasms. Although OKC derived from NBCCS have a germline mutation and a "single" hit is enough to cause OKC, for sporadic OKC, two somatic mutations are required.



The authors of these studies found evidence of allelic loss mainly in the p16, p53, PTCH, MCC, TSLC1, LTAS2 and fragile histidine triad (FHIT) genes. Taking into consideration that all of these genes are tumour-suppressor genes associated with different types of human neoplasia, these findings give

further support to explain the aggressive behavior of the OKC. In addition, observations have been made that daughter cysts are associated with a higher frequency of allelic loss [10, 11].

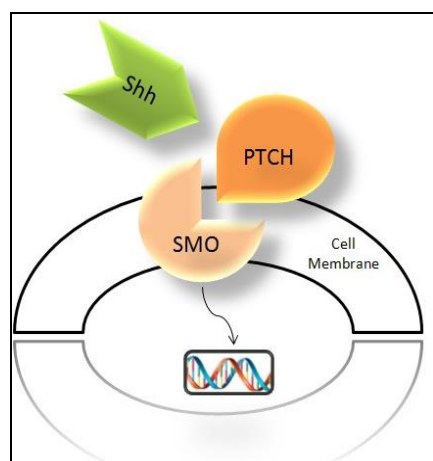
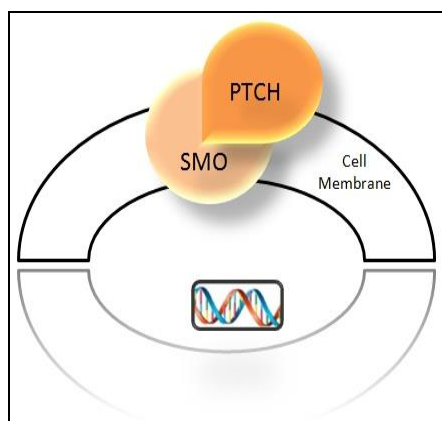
Molecular approaches of KCOT have been the subject of

several studies. Point mutations in the patched (PTCH) tumor suppressor gene have been reported for both the sporadic or nevoid basal cell carcinoma syndrome [11, 12]. Also, the most substantially over-expressed gene in this lesion is cytokeratin 6B, inferred as cytoskeletal response to increased proliferation of epithelial cells. Other over-expressed genes found include epidermal growth factor receptor 3 and glioma-associated oncogene homologue 1. In addition, disruption of fragile histidine triad (FHIT) and p53 genes were detected in many KOT, suggesting participation in the pathogenesis of the lesion, probably due to alteration in proliferative and apoptotic pathways. However, specific role in KOT remains controversial

PTCH and SMO

The most important genetic alteration reported in the OKC is in the *Drosophila* Patched gene (PTCH1) [9, 10]. The PTCH1 encodes a transmembrane receptor for Sonic Hedgehog (SHH) and other Hedgehog proteins. Normally, the PTCH1 represses the functions of the signaling effectors Smoothed (SMO). The binding of HH on the PTCH1-SMO complex releases SMO, leading to the activation of target genes by the GLI family of transcription factors [11]. The discovery that germline mutations of PTCH1 are the underlying cause of Nevoid Basal Cell Carcinoma Syndrome (NBCCS), prompted several authors to investigate the role of the HH pathway in the pathogenesis of a number of tumours associated with this syndrome, including the OKC.

Mutations of PTCH1 in OKC associated with NBCCS were first described by Lench and Colleagues. Subsequently, PTCH1 gene mutation was reported in the epithelial lining of sporadic cases of human OKC. Recently, Pan and Li demonstrated that Ki-67 labelling index in the epithelium of OKCs with PTCH1 mutation was significantly higher than in cases with no PTCH1 mutation [11, 12].



MicroRNAs

Recently, Gomes *et al.* proposed a future molecular approach in the study of KCOT pathogenesis, questioning the possible role of altered expression of oncogenic and/or tumor suppressor microRNAs (miRNAs), which is an established event in cancer [12, 13].

Epigenetic factors

Epigenetic alterations are considered important events in the tumorigenesis of benign and malignant tumours of the head and neck. The genes can be modified through this mechanism, without having their DNA sequences changed. DNA methylation is an epigenetic event characterized by the addition of a methyl group in cytosines within CpG islands, remodelling the chromatin and selectively activating or inactivating genes [12]. The PTCH1 methylation has been suggested as an alternative to mutational causes of the PTCH pathway deregulation in tumours associated with NBCCS syndrome, such as medulloblastoma and basocellular carcinoma.

Proliferative and antiapoptotic activity

The proliferative activity in the OKC was studied by various investigators and it was compared to other odontogenic cysts and tumors. Most of the researchers have found increased immune histo chemical expression of the proliferation markers Ki67 and PCNA in the OKC compared to other odontogenic lesions [13].

Although there is general agreement that some aspects of the OKC's behavior equate with neoplasia, notably the relatively high rate of proliferation, controversies over the nature of OKC still exist. Differences in proliferative activity between sporadic and NBCCS-associated OKCs have also been demonstrated in a number of studies [14].

P63

Although the p53 family members p63 and p73 are structurally related to p53, they have not been directly linked to tumor suppression, although they have been implicated in apoptosis Flores *et al.* (2000). Their experiments showed that the combined loss of p63 and p73 resulted in the failure of cells containing functional p53 to undergo apoptosis in response to DNA damage. Lo Muzio *et al.* (2005) studied the expression of p63 in OKCs and in other odontogenic cysts showed that OKCs displayed a more intense and diffuse p63 staining [14, 15]. Statistical analysis of their semi-quantitative data showed significantly higher p63 positivity in OKCs compared with other cysts concluded that the more intense and diffuse expression of p63 in parakeratinised OKCs could help to explain the differences in the clinical and pathological behaviour of the OKCs, pointing to an abnormal control of the cell cycle leading to an intrinsic growth potential.

Our study supports the hypothesis that p53 and bcl-2 are often expressed in an independent manner but with similar effects on tumorigenesis in accordance with previous studies demonstrating a cooperative action of these oncoproteins. OKC epithelial lining cell survival, promoted by bcl-2, increases the risk of epithelial cells becoming exposed to a secondary event such as a p53 mutation causing abnormal cell proliferation [14, 15]. We have also demonstrated that other non-oncogenic factors including Epidermal Growth Factor receptor (EGFr) and Insulin like Growth factor-1 receptor (IGF-1r) are expressed although localisation of the different growth factor receptors varies amongst samples. Both bcl-2 and p53 require growth factor receptors and their ligands for

cell growth. While cells remain viable due to increased expression of anti-apoptotic bcl-2, p53 often binds with growth factor receptor ligand and antagonises its action. Expression of mutated p53 in OKC indicates that it does not have any control over growth factor receptors, hence OKC epithelium displays increase expression of EGFR and IGF-1r. The cystic epithelium is capable of onco-gene and growth factor mediated cell proliferation. Increased expression of cell proliferation marker such as Ki-67 and PCNA indicate that OKC epithelium is highly proliferative in the presence of bcl-2, p53 and growth factor receptors [16].

An interesting observation of this study is absence of apoptosis in OKC. Although both bcl-2 and p53 have direct role over apoptotic pathway but our result showed no evidence of apoptosis in any sample tested. If cell death is occurring then it is at a very low rate with the emphasis in the cyst lining being proliferating. Bcl-2, which is thought to prevent apoptosis was present in almost 78% of basal cells indicating a possibility of lack of apoptosis due its role in the basal cells. This may be due to increased expression of IGF-1, which helps in preventing apoptosis allowing cells to proliferate at a high rate. This observation may have a role in proliferation status of basal cells. When bcl-2 is expressed in the basal layer it only prevents apoptosis, keeping cells viable for further genetic insult. The rate of proliferation is low at this stage, however, these clone of cells give two daughter cells and start migrating towards superficial layers, where the cells encounter further genetic abnormality including p53, EGFR and IGF-1r, which turns these cells into high proliferation status. These daughter cells in presence of bcl-2 retain their capacity to further division. Epithelial differentiation known to be influence by several cellular and chemical factors and change of this can be result from the alteration in the epithelial cytoskeletal protein [17].

Vascular endothelial growth factor

Humans are complex multicellular organisms and all cells require a dependable finely controlled supply of oxygen. Therefore, a highly developed vascular system has evolved to ensure that all cells should get proper supply of oxygen [52]. The system needs to be maintained through angiogenesis, the process of new blood vessel development from pre-existing vasculature. Angiogenesis is subject to a complex control system with proangiogenic and antiangiogenic factors. In adults, angiogenesis is tightly controlled by this "angiogenic balance", i.e., a physiological balance between the stimulatory and inhibitory signals for blood vessel growth. In normal circumstances, the formation of new blood vessels occurs during wound healing, organ regeneration, placenta formation and in the female reproductive system during ovulation and menstruation [18, 19]. It is also an important factor in several pathological processes such as tumor growth, rheumatoid arthritis, diabetic retinopathy and psoriasis. One of the most important proangiogenic factors is VEGF. VEGF also potentiates microvascular hyperpermeability, which can both precede and accompany angiogenesis. VEGF has been implicated in the pathogenesis of cystic tumors. VEGF is a dimeric, heparin-binding glycoprotein, critical for many of the individual steps involved in the complex process of angiogenesis and a potent inducer of vascular permeability. It stimulates proliferation and migration of endothelial cells, promotes survival and differentiation of endothelial cells, triggers the production of MMPs that are required for the degradation of basement membranes, contributes to the formation of tumor stroma and attracts monocytes that

produce angiogenic factors [18, 19].

VEGF expression is regulated by various factors such as hypoxia, cytokines, endotoxins, estrogens, growth factors. Has been found to be important in the progression of oral dysplasia and oral squamous cell carcinoma and of periodontitis. One of the mechanisms involved in the growth of jaw cysts could be the formation of new vessels [20].

VEGF is capable of inducing microvascular permeability leading to extravasation of plasma protein and a predictable sequence of proangiogenic stromal changes. Therefore VEGF has been implicated as an important factor in cyst enlargement [1, 19, 12].

Vascular endothelial growth factor is a sensitive measure of the angiogenic potential of a lesion and it is well known that tumors need a rich vascular supply.

Accumulation in the cystic fluid of OKCs, DCs, and RCs of serum proteins from the vasculature have been thought to elevate the hydrostatic pressure and maintain their expansion. Smith *et al.*, considered VEGF as a potent inducer of vascular permeability. On the other hand, mechanical forces have been shown to up-regulate VEGF and its inducing growth factors (TGF, PDGF, and FGF) in endothelial cells [3]. Thus, it would be reasonable to suggest that there is a positive feedback mechanism, where VEGF induces an increase in cystic pressure and this is induced by the pressure exerted on the lining epithelium from the cystic fluid [1].

Matrix Metalloproteinase

Extracellular Matrix (ECM) is important for creating the cellular environments required during development and morphogenesis. Matrix Metalloproteinase (MMPs), collectively called matrixins, are proteinases that participate in ECM degradation [1]. MMP enzymes are strongly involved in a kaleidoscope of normal, pathological, physiological and biological processes such as embryogenesis, normal tissue remodeling, wound healing and angiogenesis, and in diseases such as atheroma, arthritis, cancer and tissue ulceration.

MMPs are considered key players in the regulation of both cell-cell and cell-ECM interactions and the elucidation of their potential as drug targets in disease or as important features of the repair process will be dependent upon careful analysis of their role in different cellular locations and at different disease stages. MMP-9 plays an essential role in the resorption of collagen during bone remodelling and development (Meikle *et al.* 1992) and its overexpression is also connected to the inflammatory reaction in lung and periodontal diseases (Westerlund *et al.* 1996). Tumor cells and their metastatic potential, as well as cell invasion, are also linked to MMP-9 (Stetler-Stevenson 1990). MMP-9 is thought to be involved in odontogenic cyst expansion [18]. It has shown that an active form of MMP-9 may present in OKC fluids more frequently than DC and RC fluids. Recently it has been shown that MMPs i.e., MMP-1, MMP-8, MMP-2 and MMP-9 are present in odontogenic cyst wall extracts and cyst fluids (Teronen *et al.*, 1995), and it has been speculated that the enzymatic degradation of the osteoid extracellular matrix and basement membrane by these MMPs might be involved in odontogenic cyst expansion (Donoff *et al.*, 1972; Sorsa *et al.*, 1988; Teronen *et al.*, 1995).

Silveira *et al.* observed the expression of MMP-9 in the fibrous capsule of the odontogenic lesions, with the tendency toward higher expression of this protein in the fibrous capsule of OKCs as compared to DCs and RCs [58]. Kumamoto *et al.*, analyzing the expression of MMP-9 in ameloblastomas, also detected strong reactivity to this metalloproteinase in the

stroma of these tumors, suggesting that an increased production of this protein by neoplastic cells is related to the neoplastic transformation of odontogenic tissues and aggressiveness of these tumors⁵⁸. Taken together, these findings and the results of the present study suggest that the higher expression of MMP-9 in the mesenchymal component of OKCs contributes to the more aggressive behavior of these cysts as compared with RCs and DCs by promoting the degradation of extracellular matrix.

Relation of VEGF and MMPS

The importance of the MMPs in the induction of the angiogenic process has recently been described. MMPs, which are produced by microvascular endothelial cells, break down the extracellular matrix. This is one of the earliest and sustained events in the process of new capillary formation. VEGF-A has been shown to modulate the production and activity of these proteins (Grunstein *et al.*, 1999). Fang *et al.* (2000) reported that the suppression of MMP-2 alone inhibits the transition from the prevascular to the vascular stage during tumor development. They showed that MMP-2 is required to switch to the angiogenic phenotype during the development of chondrosarcoma and during the progression of plasma cell tumors^[1, 19]. Bergers *et al.* (2000) showed that MMP-9 is a functional component of the angiogenic switch during multistage pancreatic angiogenesis. Activation of MMP-9 induces an up-regulation of VEGF-A.

Future treatment modalities

The Sonic Hedgehog (SHH) pathway is important in embryological development and is highly conserved throughout evolution. It involves a dynamic relationship between a series of tumor suppressor genes and oncogenes and the alterations in this pathway have been described in many human tumors such as basal cell carcinoma, pancreatic, breast, and prostate cancer^[21, 22].

This provided insights into the development of molecular therapeutic approaches. Vismodegib is a low-molecular-weight systemic inhibitor of the hedgehog-signaling pathway that was approved by the Food and Drug Administration in January 2012 for the treatment of locally advanced or metastatic basal-cell carcinomas^[22].

Early studies of these molecular therapeutic approaches have hinted at possible novel treatment methods for KCOT, such molecules are, Cyclopamine, CUR622414, and GDC-0449. In 2006, Zhang *et al.* postulated that any strategy to develop antagonists of active receptors-transcriptional factors of SHH signaling pathway would prove therapeutically effective for the OKC^[22]. They suggested that intra-cystic injection of SMO protein-antagonist might be the most promising treatment option.

In theory, blocking angiogenesis should arrest tumor growth. The main strategies include blocking growth-factor activity, including VEGF signaling; inhibiting the matrix metalloproteinase responsible for breaking down the extracellular matrix and allowing blood vessels to spread; and targeting endothelial cells directly^[21, 24].

Angiogenesis inhibitors interfere with various steps in this process. For example, bevacizumab is a monoclonal antibody that specifically recognizes and binds to VEGF. When VEGF is attached to bevacizumab, it is unable to activate the VEGF receptor. Other angiogenesis inhibitors, including sorafenib and sunitinib, bind to receptors on the surface of endothelial cells or to other proteins in the

downstream signaling pathways, blocking their activities. The FDA has approved other drugs that have antiangiogenic activity including sorafenib, sunitinib, pazopanib, and everolimus. Sorafenib is approved for hepatocellular carcinoma and kidney cancer, sunitinib and everolimus for both kidney cancer and neuroendocrine tumors, and pazopanib for kidney cancer. Researchers are exploring the use of angiogenesis inhibitors to treat other types of cancer. In addition, angiogenesis inhibitors are being used to treat some diseases that involve the development of abnormal blood vessel growth in non-cancer conditions, such as macular degeneration.

Mmp inhibitors

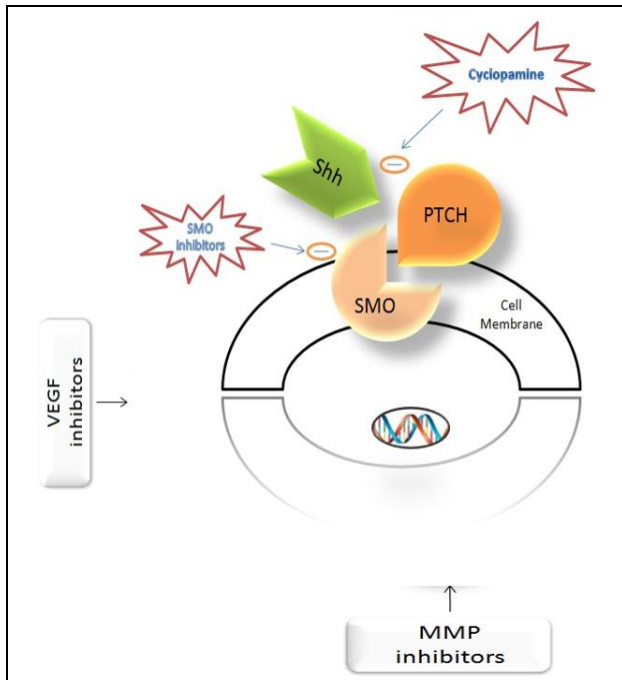
Several MMP inhibitors have entered clinical trials as a result of impressive data in animal models, although only one MMP inhibitor, Ro32-3555 (Trocade), a collagenase selective inhibitor, has been fully tested in the clinic, but it did not prevent progression of joint damage in patients with rheumatoid arthritis^[24].

The early development of MMP inhibitors was greatly restricted by a lack of oral bioavailability. An example of this was the broad spectrum inhibitor, marimastat (BB94), developed for oncology, which owing to its poor solubility had to be given by intraperitoneal injection^[24]. Consequently, this compound was replaced by marimastat (BB2516), also a broad spectrum inhibitor with improved oral bioavailability, but still at a low 10%. In contrast, the more recent Bay-12-9566, another relatively broad spectrum inhibitor with activity against gelatinase and stromelysin, developed in both oncology and OA, has an oral bioavailability in excess of 80%. Mmp in oa MMPs. Targeting MMPs in disease treatment is complicated by the fact that MMPs are indispensable for normal development and physiology and by their multi-functionality, possible functional redundancy or contradiction, and context-dependent expression and activity. This complexity was revealed by previous efforts to inhibit MMP activity in the treatment of cancer patients that yielded unsatisfactory results^[24].

A few polyphenols and flavonoids that exhibit MMPI activities may have chemopreventive and neuro- and cardiovascular-protective effects. A new generation of potent and selective MMPIs with novel ZBGs and inhibition mechanisms have been designed, synthesized, and tested. Although only one collagenase inhibitor (Periostat, doxycycline hyclate) has been approved by the Food and Drug Administration as a drug for the treatment of periodontal disease, new hope is emerging in the form of natural and synthetic MMPIs for the prevention and treatment of stroke, cardiovascular disease, cancer, and other medical conditions.

MMPS in Cancer

Many studies incorporating human specimens have implicated matrix metalloproteinase in multiple types of cancer, including those of the lung, breast, skin, and colon, among many others. The expression and activity of MMPs are elevated in and around human tumors, and are often associated with high tumor grades and stages. Moreover, excessive MMP expression has been correlated with cancer susceptibility and mortality, implicating MMPs in both early and late stages of the evolving disease^[23, 24]. *In vivo* experiments confirm that MMPs are potent players in the genesis and progression of cancer



References

1. Khot K, Deshmukh SB, Alex S. Comparative analysis of the immuno histochemical expression of vascular endothelial growth factor and matrix metalloproteinase-9 in keratocystic odontogenic tumor, dentigerous cyst and radicular cyst. *J Cancer Res The.* 2015; 11:635-40.
2. Deepak Passi, Deepika Singhal, Mahinder Singh, *et al.* Odontogenic Keratocyst (Okc) or Keratocystic Odontogenic Tumor (Kcot). Journey of Okc From Cyst To Tumor To Cyst Again: Comprehensive Review With Recent Updates on Who Classification. *International Journal of Current Research.* 2017; 9(7):54080-54086.
3. Lawal AO, Adisa AO. and of Sigbeku. Cysts of the orofacial region: A Nigerian experience. *J Oral Maxillofac Pathol.* 2012; 16(2):167-171.
4. Roopan Prakash, Shyamala K, Girish HC, Sanjay Murgod, Sneha Singh, Vidya Rani PS. Comparison of components of odontogenic cyst fluids: A review. *Journal of Medicine, Radiology, Pathology & Surgery.* 2016; 2:15-17.
5. Li J, Farthing PM, Thornhill MH. Cytokine regulation of major histocompatibility complex antigen expression by human oral and skin keratinocytes. *Arch Oral Biol.* 1996; 41(6):533-8.
6. Keerthi K Nair, Ashok Lingappa, Poornima Rangaiah, Pramod Gujjar Vittobarao. Keratocystic odontogenic tumor: A case report and review of literature. *Journal of Indian Academy of Oral Medicine and Radiology.* 2015; 27(2):253-258.
7. Singh HP, Shetty DC, Kumar A, Chavan R, Shori DD, Mali J. A Molecular Insight into the Role of Inflammation in the Behavior and Pathogenesis of Odontogenic Cysts. *Ann Med Health Sci Res.* 2013; 3(4):523-528.
8. Meghanand T. Nayak, Anjali Singh, Abhishek Singhvi, and Rohit Sharma. Odontogenic keratocyst: What is in the Name? *J Nat Sci Biol Med.* 2013; 4(2):282-285.
9. Darren P. Cox. p53 expression and mutation analysis of odontogenic cysts with and without dysplasia. 2012; 113(1):90-98.
10. Barreto DC, Gomez RS, Bale AE, Boson WL, De Marco L. PTCH gene mutations in odontogenic keratocysts. *J Dent Res.* 2000; 79(6):1418-22.
11. Yan-Yan Guo, Jian-Yun Zhang, Xue-Fen Li, Hai-Yan Luo, Feng Chen, Tie-Jun Li. PTCH1 Gene Mutations in Keratocystic Odontogenic Tumors: A Study of 43 Chinese Patients and a Systematic Review. *PLoS One.* 2013; 8(10):e77305.
12. Zhang Rui, Peng Li-Ying, Qu Jia-Fei, Hong Ying-Ying *et al.* Smoothed gene alterations in keratocystic odontogenic tumors. *Head Face Med.* 2014; 10:36.
13. Asevedo Campos de Resende T, de Fátima Bernardes V, Carolina da Silva J, De Marco LA. Loss of heterozygosity of MIR15A/MIR16-1, negative regulators of the antiapoptotic gene BCL2, is not common in odontogenic keratocysts. *Oral Surg Oral Med Oral Pathol Oral Radiol.* 2018; 125(4):313-316.
14. Gadiputi Sreedhar, Vijaya Raju M., Kiran Kumar Metta, Manjunath SM, Sujan Shetty, Rakesh Kumar Agarwal. Immunohistochemical analysis of factors related to apoptosis and cellular proliferation in relation to inflammation in dentigerous and odontogenic keratocyst. *J Nat Sci Biol Med.* 2014; 5(1):112-115.
15. Naz I, Mahmood MK, Nagi AH. Expression of Bcl-2 in Primary and Recurrent Odontogenic Keratocysts in Comparison with Other Odontogenic Lesions. *Asian Pac J Cancer Prev.* 2015; 16(15):6289-92.
16. Tapan G Modi, Monali Chalishazar, Malay Kumar. Expression of Ki-67 in odontogenic cysts: A comparative study between odontogenic keratocysts, radicular cysts and dentigerous cysts. *J Oral Maxillofac Pathol.* 2018; 22(1):146.
17. Pedro Paulode Andrade Santos, MSc Ana Rafaela Luzde Aquino, MScAlessandra Oliveira Barreto DDS, MScRoseanade Almeida Freitas DDS, MSc, P Immuno histochemical expression of nuclear factor κB, matrix metalloproteinase 9, and endoglin (CD105) in odontogenic keratocysts, dentigerous cysts, and radicular cysts. *Oral Surgery, Oral Medicine, Oral Pathology, Oral Radiology, and Endodontology.* 2011; 112(4):476-483.
18. Donia Sadri, Sareh Farhadi, Zahra Shahabi, Samaneh Sarshar. Expression of Vascular Endothelial Growth Factor in Odontogenic Cysts: Is There Any Impression on Clinical Outcome. *The Open Dentistry Journal.* 2016; 10:752-759.
19. Donia Sadri, Fatemeh Shahsavari, Sareh Farhadi, Zahra Shahabi, Zahra Mehran. Angiogenesis concept in odontogenic keratocyst: A comparative study. 2017; 28(3):275-280.
20. Ren C, Amm HM, DeVilliers P, Wu Y, Deatherage JR, Liu Z *et al.* Targeting the sonic hedgehog pathway in keratocystic odontogenic tumor. *J Biol Chem.* 2012; 287(32):27117-25.
21. Nazanin Bashardoust, Sara Bagheri, Saedeh Attarbashi, Nastaran Alizadeh, Shirin Modabbernia. Angiogenesis: A Critical Role in Locally Aggressive Behavior of Keratocystic Odontogenic Tumor. 2017; 6(4):97-102.
22. Keratocystic odontogenic tumor: A retrospective analysis of genetic, immuno histochemical and therapeutic features. Proposal of a multicenter clinical survey tool
23. Fraunfelder FT, Fraunfelder FW. Oral Anti-Vascular Endothelial Growth Factor Drugs and Ocular Adverse Events. *J Ocul Pharmacol Ther.* 2018; 34(6):432-435.
24. Florescu A, Mărgăritescu C, Simionescu CE, Stepan A. Immunohistochemical expression of MMP-9, TIMP-2, E-cadherin and vimentin in ameloblastomas and their implication in the local aggressive behavior of these tumors. *Rom J Morphol Embryol.* 2012; 53(4):975-84.