



ISSN Print: 2394-7489  
ISSN Online: 2394-7497  
IJADS 2019; 5(4): 156-158  
© 2019 IJADS  
www.oraljournal.com  
Received: 10-08-2019  
Accepted: 12-09-2019

**Dr. Astha Jaikaria**  
MDS, Pedodontics and  
Preventive Dentistry, HPGDC,  
Shimla, Himachal Pradesh,  
India

**Dr. Pooja Negi**  
MDS, Prosthodontics, MO  
(Dental), HPGDC, Shimla,  
Himachal Pradesh, India

**Dr. Suhani Kukreja**  
MDS, Prosthodontics, HPGDC,  
Shimla, Himachal Pradesh,  
India

**Corresponding Author:**  
**Dr. Pooja Negi**  
MDS, Prosthodontics, MO  
(Dental), HPGDC, Shimla,  
Himachal Pradesh, India

## **Apexification: Use of MTA and Biodentin to form apical barrier in immature permanent teeth**

**Dr. Astha Jaikaria, Dr. Pooja Negi and Dr. Suhani Kukreja**

### **Abstract**

The management of an immature tooth with pulpal necrosis and periapical pathology poses a great endodontic challenge. The conventional apexification using calcium hydroxide has certain drawbacks such as the need for long term therapy to enable barrier formation. The recent trend is to form a fragile dentinal bridge as an artificial apical stop. This case report observes apexification and successful healing with the use of Biodentine and MTA as an apical barrier matrix in root end apexification procedure.

**Keywords:** Immature tooth, apexification, MTA, Biodentin

### **1. Introduction**

The completion of root development and closure of the root apex occurs up to three years following eruption of the tooth. If, during root formation, the tooth is affected by caries, trauma or other pulpal pathoses, dentin formation is interrupted and root development will cease.

Apexification is a viable option for management of immature permanent tooth with open apex. It is defined as a method to induce a calcified barrier in a root with an open apex or continued apical development of an incompletely formed root in teeth with necrotic pulp tissue<sup>[1]</sup>. Several materials have been proposed for apical barrier formation. Calcium hydroxide has been widely used for apexification. The alkaline pH of the calcium hydroxide which denatures dentinal proteins can cause fracture of thin dentinal walls of the root canal. Considering the various drawbacks associated with calcium hydroxide apexification, the use of the apical plug method seems to be a suitable alternate treatment plan for these cases<sup>[2]</sup>.

Mineral trioxide aggregate (MTA) became the chosen material to induce the formation of the apical barrier because of its sealing properties and biocompatibility. Several studies demonstrated its capacity to induce odontoblastic differentiation, good radiopacity, low solubility, high pH, expansion after setting, and antimicrobial activity<sup>[3, 4]</sup>. However, the prolonged setting times, handling difficulties, and possible coronal staining associated with MTA<sup>[5]</sup> had led to a search for other alternative materials.

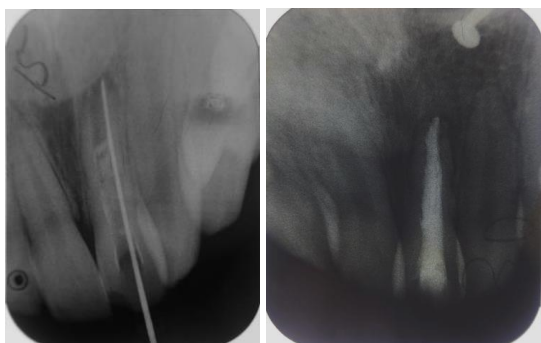
A new calcium-silicate based material, Biodentine (Septodont, Saint-Maur-des-Fosses, France), has been formulated with the intention of preserving the properties and clinical applications of MTA without its negative characteristics. Biodentine is superior to MTA as its consistency is better suited to clinical use, ensuring better handling and safety, the material does not require a two-step obturation and, as the setting is faster; there is a lower risk of bacterial contamination<sup>[6]</sup>.

This material can be used for substitution of dentin in coronal restorations, pulp linings, pulpotomies, reparation of root perforations, internal and external resorptions, formation of apical barriers in apexification treatment, regenerative procedures, and as retrofilling material in endodontic surgery<sup>[7]</sup>. In contrast, a possible disadvantage of Biodentine is its low radiopacity<sup>[8]</sup>.

The present clinical case series reports symptomatic immature permanent tooth with pulp necrosis and apical periodontitis that was treated after the apexification procedure with Biodentine and MTA.

### Case 1

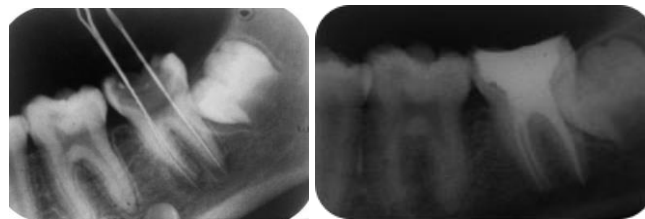
A 12 year old female patient reported with a chief complaint of pain and swelling in relation to maxillary left lateral incisor. History revealed that the patient had suffered trauma at the age of 8 years. The vitality of the tooth was determined by the cold pulp test, using dry ice in a “pencil stick” form. It revealed the negative response. Radiographic examination revealed an immature tooth with a wide open apex and a radiolucent area in proximity of the apex of the tooth. Endodontic access opening was done under local anesthesia, and a periapical radiograph was taken to determine the working length. Biomechanical preparation was done and root canal debridement was done using alternate irrigation with 2.5% NaOCl and saline. The root canal was then dried with sterile paper points. Calcium hydroxide and iodoform combination (Metapex™, META Biomed Co. Ltd., Korea) was placed in the root canal, and the patient was recalled after 1 week. One week later, the calcium hydroxide dressing was removed by hand instrumentation, and irrigation was done. The root canal was then dried with sterile paper points and Biodentin was pushed using root canal plugger. After detremining that the plug had set, obturation was done and the access cavity was sealed using composite resin. IOPA after 6 month revealed in advertent periapical healing and cinically, the tooth was assymptomatic.



**Case 1:** Working length and postobturation followup radiographs of left central incisor showing apexification using Biodentin

### Case 2

A 14 year old female patient reported with a chief complaint of pain in relation to mandibular right second molar. Patient was unable to give any relatable history. The vitality of the tooth was determined by the heat test, using heated gutta percha stick. It revealed the negative response. Radiographic examination revealed an immature tooth with a wide open apex and a radiolucent area in proximity of the apex of the tooth. Under local anesthesia, endodontic access opening was done and a periapical radiograph was taken to determine the working length. After biomechanical preparation and debridement of the root canal, canals were dried using papaer points. Calcium hydroxide and iodoform combination (Metapex™, META Biomed Co. Ltd., Korea) was placed in the root canal, and the patient was recalled after 1 week. The dressing was remonved with hand instrumentation followed by irrigation. MTA [MTA ProRoot, Dentsply, Tulsa, OK, USA]) was mixed with distilled water to a consistency of wet sand and placed in increments in the apical region of the canal was delicately pushed towards the apex using root canal plugger and Wet sterile cotton was placed in the canal above MTA. The tooth was then given a temporary restoration with cavit. On the recall visit, post endodontic restoration was done. A 6 month followup radiograph revealed periapical healing and the tooth was assymptomatic.



**Case 2:** Working length and postobturation followup radiographs of right second mandibular molar showing apexification using MTA.

### Discussion

Management of open apex can have multiple options such as apexification, apexogenesis, or revascularization technique. Apexogenesis is treatment to preserve vital pulp tissue in the apical part of a root canal to complete formation of root apex.<sup>9</sup> Therefore, apexogenesis is only possible when some vital pulp is remaining. However, it was not possible as in our cases, both teeth had necrotic pulps. Revascularization technique has an advantage of formation of pulp dentin complex. It establishes defense mechanisms of pulp. However, long term follow up and uncertainty of results is a disadvantage<sup>[10]</sup>.

The goal of apexification is to obtain an apical barrier to prevent the passage of toxins and bacteria into periapical tissues from the root canal. Technically, this barrier is necessary to allow compaction of root filling material<sup>[11]</sup>. The conventional apexification technique using calcium hydroxide requires at least three to four months and involves multiple appointments. Patient compliance with this protracted treatment protocol may be poor and many fail to return for scheduled appointments. The aim of the treatment described in these cases is to create in a single appointment an apical barrier which will prevent the penetration of toxins and bacteria into periapical tissues from the root canal. Technically, this barrier is also necessary to allow the compaction of root filling material<sup>[12]</sup>.

With the discovery of MTA by Torabinejad *et al.*,<sup>[13]</sup> it has become the material of choice for apexification. Single visit apexification is now a viable treatment option for the immature apex. The main constituents are CaSiO<sub>4</sub>, bismuth oxide, calcium carbonate (CaCO<sub>3</sub>), calcium sulfate, calcium aluminate. It contains a hydrophilic powder that reacts with water and produces a calcium hydroxide and CaSiO<sub>4</sub> hydrated gel. Holland *et al.* theorized that the tricalcium oxide in MTA reacts with tissue fluids to form calcium hydroxide, resulting in an apical barrier<sup>[14]</sup>. The long setting time of ProRoot MTA is a major problem of the material, apart from poor handling characteristics, discoloration potential (Gray MTA), low washout resistance and high material cost<sup>[15]</sup>.

Biodentine is a new bioactive dentin substitute cement, which is composed of powder that consists of tricalcium silicate, dicalcium silicate, calcium carbonate, calcium oxide, zirconium oxide, and CH. The liquid for mixing with the cement powder consists of a water-soluble polymer and calcium chloride, which accelerates the setting reaction<sup>[16]</sup>. Biodentine has a shorter setting time of 12 minutes, as compared with that of MTA, which is 2 hours 45 minutes. Zanini *et al.*<sup>[8]</sup> suggest that Biodentine is bioactive because it induces differentiation of odontoblast-like cells and increases murine pulp cell proliferation and biomineralization. The response of dental pulp after direct capping with Biodentine revealed a complete dentinal bridge formation and a layer of odontoblast-like cells under the osteodentin<sup>[17]</sup>. Biodentine has been shown to lack cytotoxicity, and it is able to stimulate collagen fiber and fibroblast formation. Biodentine has a

limitation that it cannot be used in the presence of moisture unlike MTA.

On radiographic observance, it was noted that initial periapical healing was better in tooth filled with biodentine. However, long term periapical healing of MTA filled tooth was better. This may due to the fact that MTA has superior marginal adaptation<sup>[18]</sup>.

### Conclusion

Single visit apexification with biocompatible materials such as Biodentine and MTA can be considered an effective treatment option for teeth presenting with open apices. From the above case reports, it can be concluded, however, that biodentine showed better initial healing while MTA had better long term effect.

### References

1. Bhasker SN. Orban's Oral Histology and Embryology. 11th ed. St. Louis: Mosby-Year Book; 1991. p382.
2. American Association of Endodontists. Glossary of Endodontic Terms. 7th ed. Chicago, IL: American Association of Endodontists; 2003.
3. Sheehy EC, Roberts GJ. Use of calcium hydroxide for apical barrier formation and healing in nonvital immature permanent teeth: a review. *Br Dent J.* 1997; 183:241-6.
4. Parirokh M, Torabinejad M. Mineral trioxide aggregate: a comprehensive literature review—part III: clinical applications, drawbacks, and mechanism of action. *J Endod* 2010; 36:400-13.
5. Camilleri J. Scanning electron microscopic evaluation of the material interface of adjacent layers of dental materials. *Dent Mater* 2011; 27:870-8.
6. Balasubrahmaniam A, Sabna BS, Ramesh Kumar M, *et al.* One visit apexification using a novel dental material, Biodentine – A case report. *IOSR Jnl Dent Med Sci.* 2014; 13(5):90-2.
7. Camilleri J, Sorrentino F, Damidot D. Investigation of the hydration and bioactivity of radiopacified tricalcium silicate cement, Biodentine and MTA Angelus. *Dent Mater.* 2013; 29:580-93.
8. Zanini M, Sautier JM, Berdal A, *et al.* Biodentine induces immortalized murine pulp cell differentiation into odontoblast-like cells and stimulates biomineralization. *J Endod.* 2012; 38:1220-6.
9. Heasman P, McCracken G. Harthy's Dental Dictionary. 3rd ed. London: Churchill Livingstone, Elsevier; 2007.
10. Iwaya S, Ikawa M, Kubota M. Revascularization of an immature permanent tooth with periradicular abscess after luxation. *Dent Traumatol.* 2011; 27:55- 8.
11. Komabayashi T, Spångberg LS. Comparative analysis of the particle size and shape of commercially available mineral trioxide aggregates and Portland cement: A study with a flow particle image analyzer. *J Endod.* 2008; 34:94- 8.
12. Trope M. Treatment of immature teeth with non-vital pulps and apical periodontitis. *Endotopic.* 2007; 14:51- 9.
13. Torabinejad M, Watson TF, Pitt Ford TR. Sealing ability of a mineral trioxide aggregate when used as a root end filling material. *J Endod.* 1993; 19:591- 5.
14. Holland R, de Souza V, Nery MJ, Otoboni Filho JA, Bernabé PF, Dezan Júnior E. Reaction of rat connective tissue to implanted dentin tubes filled with mineral trioxide aggregate or calcium hydroxide. *J Endod.* 1999; 25:161-6.
15. Maroto M, Barberia E, Planells P *et al.* Treatment of a non-vital immature incisor with mineral trioxide aggregate (MTA). *Dent Traumatol.* 2003; 19:165-9.
16. Grech L, Mallia B, Camilleri J. Characterization of set intermediate restorative material, biodentine, bioaggregate and a prototype calcium silicate cement for use as root-end filling materials. *Int Endod J.* 2013; 46:632-41.
17. Nowicka A, Lipski M, Parafiniuk M, *et al.* Response of human dental pulp capped with biodentine and mineral trioxide aggregate. *J Endod.* 2013; 39:743-7.
18. Soundappan S, Sundaramurthy JL, Raghu S, Natanasabapathy V. Biodentine versus mineral trioxide aggregate versus intermediate restorative material for retrograde root end filling: An in vitro study. *J Dent (Tehran).* 2014; 11:143-9.