



ISSN Print: 2394-7489
ISSN Online: 2394-7497
IJADS 2020; 6(1): 63-65
© 2020 IJADS
www.oraljournal.com
Received: 01-11-2019
Accepted: 05-12-2019

Dr. Avanti Merchant
3rd Year Postgraduate Student,
Department of Prosthodontics,
DY Patil University School of
Dentistry, Navi Mumbai,
Maharashtra, India

Dr. Rubina Tabbassum
Professor, Department of
Prosthodontics, DY Patil
University School of Dentistry,
Navi Mumbai, Maharashtra,
India

Dr. Gaurang Mistry
HOD, Department of
Prosthodontics, DY Patil
University School of Dentistry,
Navi Mumbai, Maharashtra,
India

Dr. Omkar Shetty
Dean, Professor, Department of
Prosthodontics, DY Patil
University School of Dentistry,
Navi Mumbai, Maharashtra,
India

Corresponding Author:
Dr. Avanti Merchant
3rd Year Postgraduate Student,
Department of Prosthodontics,
DY Patil University School of
Dentistry, Navi Mumbai,
Maharashtra, India

Implant supported Overdenture: A case report

**Dr. Avanti Merchant, Dr. Rubina Tabbassum, Dr. Gaurang Mistry and
Dr. Omkar Shetty**

Abstract

Edentulism has been a long standing concern in the field of prosthodontics. Implant therapy today has seen to help overcome several limitations of traditional denture therapy. Implant supported overdentures are seen to be a treatment modality of choice, as they are seen to improve the retention, stability, aesthetics as well as overall patient comfort. This case report aims to throw light on a case of a completely edentulous patient who was rehabilitated with the help of an implant supported overdenture.

Keywords: Implant supported bar overdenture, radiographic guide, surgical stent, lingualized occlusal scheme

Introduction

The transition of a patient from a dentate to an edentulous state can be difficult for a patient. In order to best mimic masticatory functions to as close to normal as possible implant therapy can be used as an adjunctive measure. Overdentures aid to provide better comfort and long term serviceability to the patient. By placing implants in the edentulous mandible and subsequently loading them, bone resorption can be limited as light irritative stimuli lead to changes in bone architecture, shape and volume resulting in sub periosteal growth ^[1]. Implant-supported overdentures increase patient satisfaction and quality of life. It has been suggested that an overdenture with 2 implants is the first choice of treatment in the edentulous mandible ^[2]. Bar-retained implant overdentures (IODs) are a common treatment option in implant prosthodontics, and the implants that support the prosthetic restorations exhibit high survival rates ^[3]. Ball attachments, magnetic attachments, bar attachment systems, and telescopic crowns have been used to anchor the overdenture. Among these systems, bar attachment system has the greatest retention ^[4]

Implant supported prosthesis vary in design based on the, available bone, the amount of interarch space available and the affordability of the patient.

Case report

A 55year old male patient reported to the department of prosthodontics to the DY Patil School of dentistry. He presented with the chief complain of missing teeth which caused him inability to eat, and speak properly. The patient was screened according to protocol for his general health and treatment possibilities. He was also bothered with his appearance and hence desired treatment of the same. On intra oral examination, it was noted that the patient was completely edentulous and had a highly resorbed mandibular ridge. Due to the resorption pattern seen in the patient he was informed about the poor prognosis of constructing a mandibular denture. Different treatment options were put forward to the patient including implant therapy which would be best suited for him. After obtaining his consent we went about the treatment.

At first diagnostic impressions were made of the patient using impression compound (Fig.1) Primary models were poured in type for 1 dental plaster on which custom trays were fabricated. With the help of these trays border moulding with green stick low fusing impression sticks and the final impressions were made with (Aquasil addition silicone light body impression material) (Fig. 1). Final models were obtained from these impressions and record bases and wax rims were fabricated on the same. The patients jaw relation and centric relation was recorded, a facebow transfer was obtained and this relation was mounted on a semi adjustable articulator (Hanau Wide Vue). This mounting was used as a diagnostic aid to

Judge the available interarch space that was available in the patient which measured to be around 15mm. A trial denture arrangement was done and a ligualised occlusal scheme was used. This denture was then acrylized and duplicated with clear acrylic resin, gutta percha pointers were placed in the

favourable implant positions and the patient was asked to take a CBCT wearing the same which acted as a radiographic guide (Fig. 2). With the help of this CBCT and digital imaging software the implant treatment planning was done and the implant locations, size and diameter were determined.

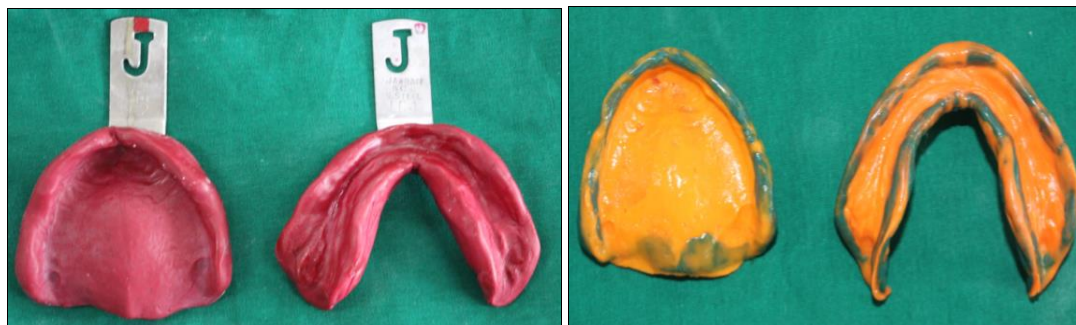

Fig 1: Maxillary and Mandibular Primary and Final Impressions.

Surgical phase

The same radiographic guide was used as a surgical template was fabricated (Fig. 2). two implants (DIO Implants, 3.0 mm in diameter and 11.5 mm in length) were placed at B and D

positions following standard protocol. After 48 hours, tissue surface of mandibular denture was relieved and relined using temporary soft denture liner.

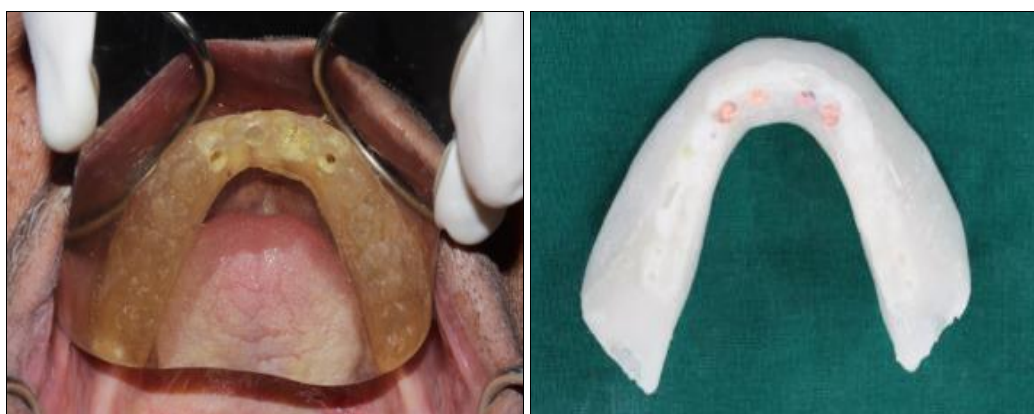

Fig 2: Radiographic and Surgical Guide.

After a healing phase of 3 months and after complete osseointegration the surgical site was reopened and stage two surgery was performed. Gingival formers were placed on the implants and allowed to sit for a period of 1 week to allow for the formation of a proper gingival collar. A customized impression tray was fabricated and open tray impression copings were used to make the final impression with polyether impression paste. A new jaw relation and centric record were taken and mounted on the semiadjustable

articulator. UCLA plastic abutments were provided to the laboratory which were attached to a plastic bar sleeve. A castable bar system (Ceka attachment, Preci Line) was used (Fig. 3). The height of the bar was adjusted to facilitate ease in maintaining oral hygiene. The bar-abutment pattern assembly was then cast. The bar was finished and polished and checked in patient intraorally and radio graphically for passive fit. The plastic bar pattern was cut to the desired length and attached to the UCLA abutments.

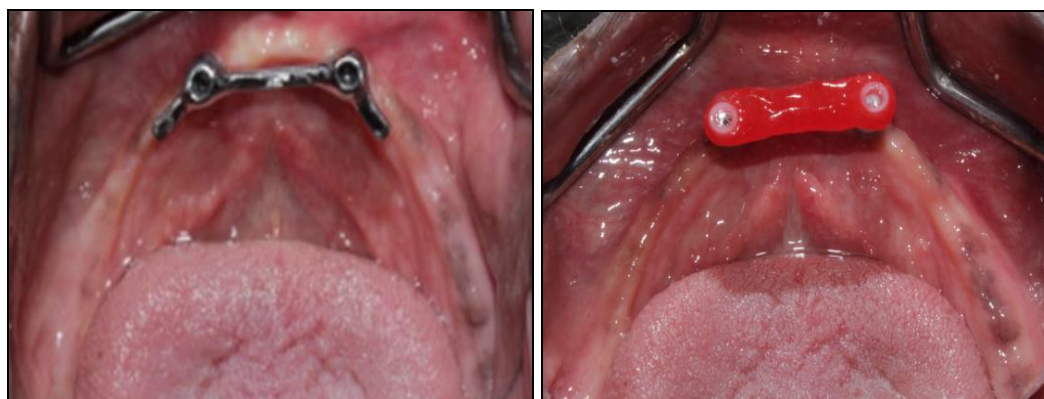


Fig 3: Castable plastic sleeve and Final Finished Bar superstructure

The trial denture base was articulated onto the bar with the positioner clips and the metal housing. The intaglio surface was blocked out and then processed traditionally to avoid any flow of acrylic resin between the clip and bar. The finished bar was placed in the patients mouth and screwed in with a torque of 35Ncm (Fig. 3). The screw openings were blocked

with composite resin and the denture was inserted into the patients mouth and checked for proper occlusal contacts and extensions (Fig.4). The patient was called back for follow up recall visits to evaluate the final denture (Fig. 4). A final OPG was taken to evaluate for implant osseointegration and proper seating of the bar framework (Fig.5).

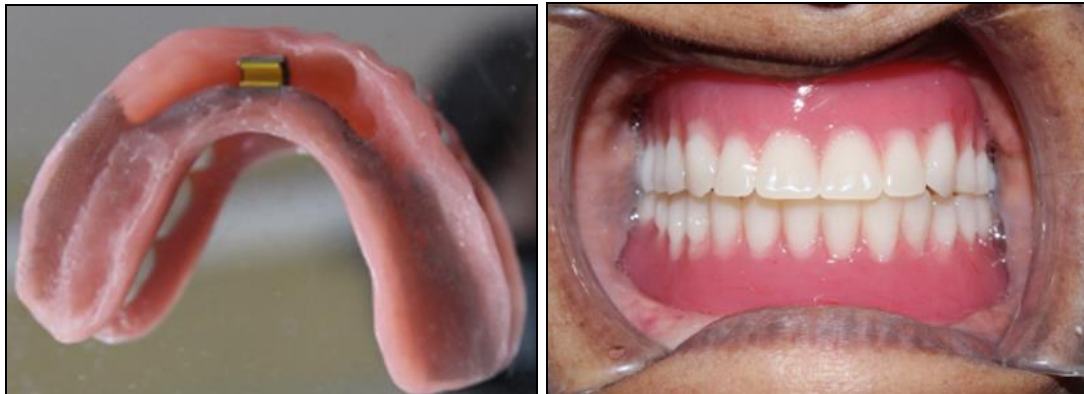

Fig 4: Final Mandibular Denture and Intra Oral View of Final Dentures

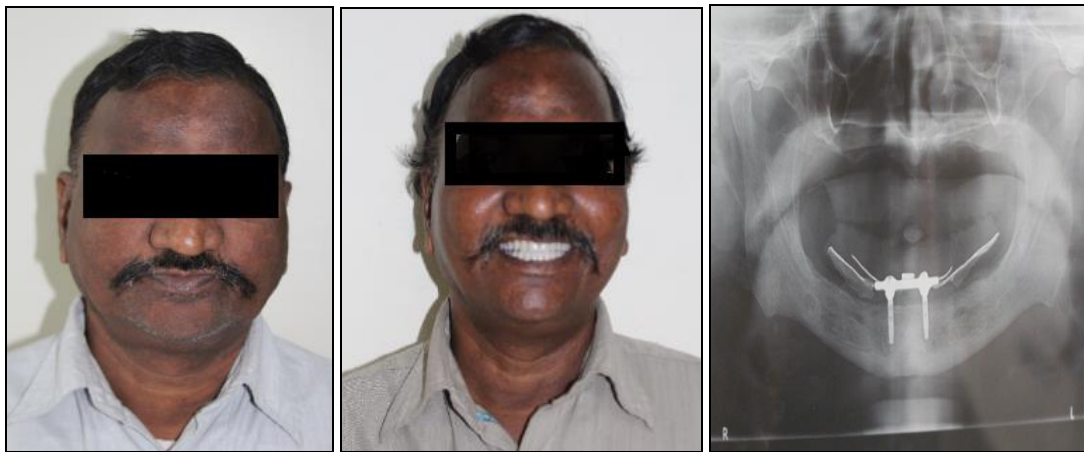

Fig 5: Pre and Post-Operative Extra Oral views and Post-Operative OPG

Conclusion

Literature suggests that bar retained implant supported overdentures are an excellent treatment option for edentulous jaws. These restorations exhibit high implant and prosthesis survival rates (>97%) and a limited incidence of any complications making them a treatment of choice for edentulous mandibles [5].

References

1. Mosnegutu A, Wismeijer D, Geraets W. Implant-supported mandibular overdentures can minimize mandibular bone resorption in edentulous patients: Results of a long-term radiologic evaluation. *Int. J Oral Maxillofac Implants.* 2015; 30:1378-1386.
2. Feine JS, Carlsson GE, Awad MA *et al.* The McGill consensus statement on overdentures: mandibular two-implant overdentures as first choice standard of care for edentulous patients. Montreal, Quebec, May 24–25, 2002. *Int J Oral Maxillofac Implants.* 2002; 17:601-602.
3. Krennmair G, Krainhöfner M, Piehslinger E. The influence of bar design (round versus milled bar) on prosthodontic maintenance of mandibular overdentures supported by 4 implants: a 5-year prospective study. *Int. J Prosthodont.* 2008; 21:514-520.
4. Takeshita S, Kanazawa M, Minakuchi S. Stress analysis of mandibular two-implant overdenture with different

attachment systems. *Dent Mater J.* 2011; 30:928-934.

5. Ueda T, Kremer U, Katsoulis J, Mericske-Stern R. Long-term results of mandibular implants supporting an overdenture: implant survival, failures, and crestal bone level changes. *Int. J Oral Maxillofac Implants.* 2011; 26:365-372.