



ISSN Print: 2394-7489
ISSN Online: 2394-7497
IJADS 2020; 6(2): 22-24
© 2020 IJADS
www.oraljournal.com
Received: 14-02-2020
Accepted: 18-03-2020

Nabeeh PK

PG student, Department of
pediatric & preventive dentistry
Kannur dental college
Kannur, Kerala, India

Faizal C Peedikayil

Head of the Department
Department of pediatric &
preventive dentistry
Kannur dental college
Kannur, Kerala, India

Dhanesh Narasimhan

Reader, Department of pediatric
& preventive dentistry
Kannur dental college
Kannur, Kerala, India

Corresponding Author:

Nabeeh PK

PG student, Department of
pediatric & preventive dentistry
Kannur dental college
Kannur, Kerala, India

Accidental ingestion of endodontic instrument in child patient: A case report

Nabeeh PK, Faizal C Peedikayil and Dhanesh Narasimhan

Abstract

During endodontic treatment, a four year old, male child, suddenly moved his head, due to which an endodontic instrument slipped from the operator's hand. Anteroposterior radiograph of the chest revealed the presence of a sharp foreign body in the fundus of the stomach. The endodontic instrument was then retrieved with endoscope, under full visualization in the screen throughout the retrieval process.

Keywords: Aspiration, ingestion, foreign body, endodontic file, isolation

Introduction

Incidences of accidental ingestion of endodontic instruments are rare in clinical practice, but if it occurs it can be serious and need urgent medical attention. Due to lack of use of rubber dam cases have been reported of accidental ingestion of files, reamers, irrigation needles, crowns, inlays, onlays, posts and rubber clamps [1-2].

Ingestion or aspiration of materials can even occur after the dental treatment is over like partial removable and fixed prosthesis, orthodontic appliances such as brackets and broken molar bands etc [3]. Uncooperative Children, Medically compromised patients such as Psychosis, Alzheimer's disease, Parkinson's disease, mentally retarded, excessive gag reflex, patients who have undergone oral cavity surgery, compromised motor function etc are prone to such accidents [4].

Grossman [5] noted that 87% of accidentally ingested foreign bodies entered alimentary tract whereas 13% aspirated into respiratory tract. Ingestion/Aspiration can be life threatening or can cause serious complications like choking, esophageal tissue perforation, intestinal ulceration or perforation, bronchial stenosis, abscess formation, hemorrhage or fistula [6].

Proper measures must be taken by the dentist to prevent accidental ingestion of endodontic instruments. For e.g. proper use of rubber dam minimizes the risk of ingestion. Likewise patient in whom coordination of deglutition and cough reflex is affected must be seated in an upright position and the objects prone for swallowing must be tether with ligature. Generally, it is advisable to seat patients in an upright position to avoid such accidents. For radiographic examination, X-ray films or digital sensors should be tethered or use of paralleling technique is more appropriate to prevent accidents [7-8].

Case report

A four year old, male child, reported to the Department of Pedodontics & Preventive dentistry with the chief complaint of pain on his lower right back tooth since 2 weeks. Based on the history and clinical and radiographic examination tooth number #85 was diagnosed with a chronic irreversible pulpitis and pulpectomy was advised. During the subsequent visit local anesthesia was given and an attempt to place rubber dam was made. As the patient exhibited discomfort with the placement of the rubber dam, the procedure was carried out without rubber dam isolation. During the cleaning and shaping of the root canal, the patient suddenly moved his head, due to which an endodontic instrument (Pro Taper hand file, Dentsply) slipped from the operators hand. The procedure was stopped immediately and measures were taken to retrieve the file from the posterior region of oral cavity but were not visible in the oral cavity. The patient didn't have choking or cough with no obvious signs of respiratory distress.

A radiograph of head & neck was taken to see for the presence in that region. As the radiograph revealed no signs of instrument, patient was immediately shifted to medical emergency centre. Anteroposterior radiograph of the chest and stomach revealed the presence of a sharp foreign body in the fundus of the stomach (Figure 1).

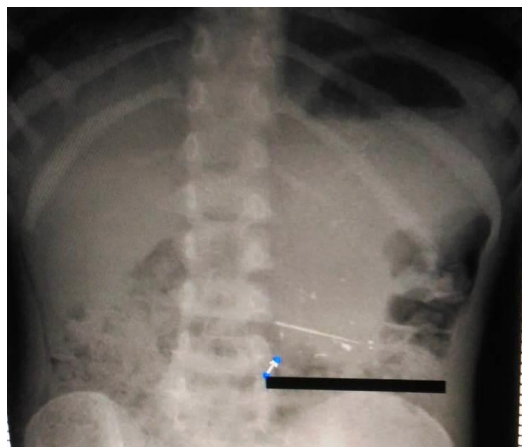


Fig 1: The fundus of the stomach

As the endodontic instrument has a sharp edge which is piercing the mucosa, an emergency endoscopy procedure was advised under general anesthesia. Endoscopy revealed that the endodontic instrument had pierced the mucosal folds tangentially, and was embedded in the left wall of fundus of the stomach (Figure 2).

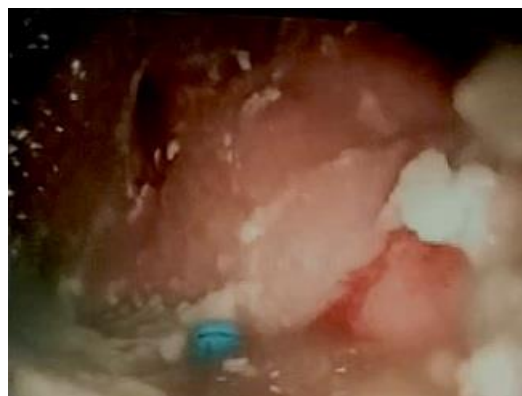

Fig 2: The stomach

Using an endoscopic grasper, the handle of the endodontic instrument was grasped, gently pulling it out of the mucosal fold. (Figure 3)

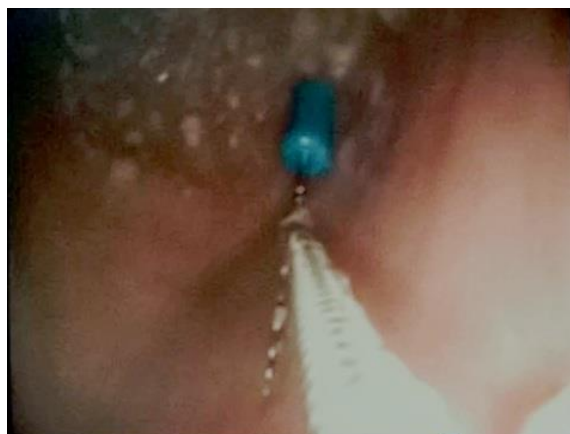

Fig 3: The mucosal fold

The site of penetration of the mucosa was inspected for bleeding and perforation. The endodontic instrument was then retrieved along with the withdrawal of the endoscope, under full visualization in the screen throughout the retrieval process. The patient was subsequently discharged with no complaints of discomfort. Patient was followed up after 15 days for routine check up and the dental treatment was completed.

Discussion

The management of a clinical situation wherein a child has swallowed a dental instrument is difficult due to considerable anxiety of the patient and the parent. As the first line of treatment, the dental practitioner should immediately confirm that there are no signs of airway obstruction such as hypnoea, choking, labored breathing or cyanosis. If the patient is a child, the parent or the bystander should be informed about the complications associated with ingestion and the procedures to be carried out in emergency. The dentist has to comfort the patient and make him/her aware of the situation. The patient should then be then immediately referred for radiographic examination to locate the exact position of the object. Appropriate radiographic examination like Frontal and Lateral chest and abdominal radiograph will reveal position of object. Along with it some specific examination like Fluoroscopy can be used. If the object is not radiopaque, Diagnostic Bronchoscopy or CT is indicated^[9].

The ingested endodontic instrument has 2 pathways. The most common one being the gastrointestinal tract (GIT) and the other one is the respiratory tract.⁶ GIT is the most common and comparatively the less complicated pathway. In most of the instances, post accidental ingestion, patients are asymptomatic and its evacuated within 2-5 days. But, the patient must be under medical surveillance until evacuation of the ingested object. Food with coarse fibers is beneficial during this period. Complications occur when object is lodged in duodenum or colon leading to severe pathological condition such as peritonitis^[10].

Respiratory pathway is the less common, yet the more complicated one. The patient may complain of something stuck in the throat and might present with excessive salivation and gagging. A dentist must be educated on how to manage such emergency situation. Analyzing the situation and a quick action without panicking is very essential in the management of such situation. The most successful method is Bronchoscopy, which retrieves 99% of aspirated dental objects^[11]. If the patient is suspected to have ingested any foreign body, The dentist should try to locate the position of the aspirated object. If it lies in the oropharynx, then the patient should be immediately placed in the Reverse Trendelberg position and tell the patient to cough. Yet, if it's not retrieved Heimlich maneuver should be followed. If the patient is asymptomatic, inform and reassure the patient about the situation and send him for immediate medical examination^[12].

In some cases of accidental ingestion, surgical intervention may be required to prevent complication and to retrieve the ingested object that lies in the digestive tract, stomach, duodenum, colon or appendix. Appropriate radiographic examination is necessary for locating the ingested/aspirated object. For radiopaque objects, chest and abdominal X-rays are used. For radiolucent objects such as acrylic teeth, resin fillings, impression materials, bronchoscopy or CT is indicated. Aspiration of object requires immediate medical care, even if the patient is asymptomatic, like the present case.

The severity of the situation depends on the anatomical direction, anatomical location, size, shape and sharpness of the object; some of which maybe life threatening. The risk of injury increases when the size of the object is >5cm or has a pointed shape. If the ingested instrument stays in the alimentary canal it can cause damage to the digestive tract, or can lead to abscess formation, peritonitis, septicemia, foreign body granuloma, fistulas and duodeno-colonic fissures. The endodontic file has been previously reported to pass out through the gastrointestinal system in 90% of the cases, uneventfully within 7 days of the accident The passage of the object through tract is slow and different in patient having reduced peristaltic movement, e.g. Crohn's disease With sharp object, the most common sites of perforation are the lower esophagus and terminal ileum. Serial radiographs are a reliable method of monitoring the passage of the object, and also about any indication about intestinal perforation. Furthermore, patient and the guardian should look signs such as blood in stools. If object is sharp, non-radiopaque, and long or if multiple instruments are ingested, endoscopy is indicated [13]. The time of endoscopy is extremely important as too much delay may allow the file to cross the pyloric sphincter, into the duodenum after which retrieval may be impossible. Hence, if endoscopy is planned, it should be done preferably within 2 hrs but at the latest within 6 hrs after ingestion. If the position of the object doesn't appear to change in the lower abdomen, then colonoscopy through rectum and laproscopic examination to locate the object and subsequent removal by ileotomy, colonotomy or appendectomy may be necessary [1, 7, 13, 14, 15].

It is advisable to carry endodontic procedures under rubber dam application to avoid any kind of mishaps such as swallowing of endodontic instruments, dental burs, etc in children. Latest barrier methods like optra dam etc can be tried if there is difficulty in placing traditional rubber dam in children. The child's head should be inclined to one side to avoid swallowing of any foreign body. Gauge screens, flossing of the hand files, checking of proper locking of instruments in headpieces, and using high evacuation suction etc can be used as a precaution to prevent accidental instrument ingestion [7, 16].

Conclusion

Even though ingestion of dental instrument is rare in pediatric dental practice, standard protocols of patient safety has to be followed. Early recognition and preliminary emergency management of the accidental ingestion has to be carried out in the dental clinic itself. If the ingested file is not retrieved, patient has to be shifted to the higher centers immediately for comprehensive emergency management.

References

1. Khetani P, Sinha N, Dabas U, Dabas VK. Accidental ingestion and successful retrieval of an endodontic file from the left hypochondriac region using endoscopy. *Endodontology* 2016; 28:183-7
2. Cameron SM, Whitlock WL, Tabor MS. Foreign body aspiration in dentistry: A review. *J Am Dent Assoc* 1996; 127:1224-9
3. Tiwana KK, Morton T, Tiwana PS. Aspiration and ingestion in dental practice: A 10-year institutional review. *J Am Dent Assoc*. 2004; 135:1287-91
4. Venkataraghavan K, Anantharaj A, Praveen P, Rani SP, Krishnan BM. Accidental ingestion of foreign object: Systematic review, recommendations and report of a

- case. *Saudi Dent J*. 2011; 23:177-81.
5. Grossman LI. Prevention in endodontic practice. *J Am Dent Assoc*. 1971; 82:395-6
6. ElBadrawy HE. Aspiration of foreign bodies during dental procedures. *J Can Dent Assoc*. 1985; 51:145-7 7.
7. Bains R, Loomba K, Sinha S, Bains VK. Accidental swallowing of endodontic instrument: Could be a medical emergency. *Eur J Gen Dent*. 2014; 3:202-4
8. Parolia A, Kamath M, Kundubala M, Manuel TS, Mohan M. Management of foreign body aspiration or ingestion in dentistry. *Kathmandu Univ Med J (KUMJ)*. 2009; 7:165-71
9. Tamura N, Nakajima T, Matsumoto S, Ohyama T, Ohashi Y. Foreign bodies of dental origin in the air and food passages. *Int J Oral Maxillofac Surg*. 1986; 15:739-51.
10. Brady PG. Management of esophageal and gastric foreign bodies. *Gastrointest Endosc*. 1995; 42:622-5
11. Dikensoy O, Usalan C, Filiz A. Foreign body aspiration: Clinical utility of flexible bronchoscopy. *Postgrad Med J* 002; 78:399-403.
12. Yadav RK, Yadav HK, Chandra A, Yadav S, Verma P, Shakya VK. Accidental aspiration/ingestion of foreign bodies in dentistry: A clinical and legal perspective. *Natl J Maxillofac Surg*. 2015;6:144-51
13. Smith MT, Wong RK. Foreign bodies. *Gastrointest Endosc Clin N Am*. 2007; 17:361-82, vii.
14. Park JH, Park CH, Park JH, Lee SJ, Lee WS, Joo YE, *et al*. Review of 209 cases of foreign bodies in the upper gastrointestinal tract and clinical factors for successful endoscopic removal. *Korean J Gastroenterol*. 2004; 43:226-33.
15. Henderson CT, Engel J, Schlesinger P. Foreign body ingestion: Review and suggested guidelines for management. *Endoscopy* 1987; 19:68-71.
16. Ahmed HM, Cohen S, Lévy G, Steier L, Bukiet F. Rubber dam application in endodontic practice: An update on critical educational and ethical dilemmas. *Aust Dent J*. 2014; 59:457-63.