



ISSN Print: 2394-7489
ISSN Online: 2394-7497
IJADS 2020; 6(2): 30-33
© 2020 IJADS
www.oraljournal.com
Received: 19-02-2020
Accepted: 23-03-2020

Dr. Moksha Nayak
Principal & Professor, KVG
Dental College & Hospital,
Sullia, Karnataka, India

Dr. Angeline Jose
Post Graduate Student, KVG
Dental College & Hospital,
Sullia, Karnataka, India

Endocrown - an option for rehabilitation of badly mutilated tooth: A case report

Dr. Moksha Nayak and Dr. Angeline Jose

Abstract

Rehabilitation of extensively damaged teeth is the most challenging task. Among the various options available to restore badly mutilated endodontically treated tooth, endocrowns represent a simple, conservative, and esthetic alternative to conventional crowns. Endocrown is a one- piece restoration, usually indicated in cases with decreased crown height. The preparation comprises of “sidewalk” as the cervical margin and a preparation into the pulp chamber. These restorations are self cleansing, prevents interferences with periodontal tissues due to the presence of supragingival position of the margins, maintains natural contact and increases longevity of the tooth. The rationale of this technique is to use the surface area available in the pulpal chamber to achieve stability and retention through adhesive procedures. In this case report, a severely damaged mandibular molar was restored using an all ceramic Endocrown which served as a conservative and esthetic restorative alternative to full coverage crown.

Keywords: endocrown, severely damaged tooth, post endodontic restoration

Introduction

Restoration of teeth with extensive coronal destruction remains a clinical challenge. Endodontically treated teeth (ETT) are weak due to the loss of structural integrity associated with caries, trauma and extensive cavity preparation, as well as due to dehydration or physical changes in dentin ^[1]. Post endodontic restorations mechanically stabilizes the tooth- restoration complex in ETT ^[2]. The choice of a post endodontic restoration is influenced by the type of tooth and the number of walls remaining ^[3, 4]. Restoration of ETT with extensive tooth structure loss should follow a strict protocol, which involves the fabrication of full crown supported on post and cores ^[5]. Various disadvantages of this intraradicular posts have led dentists to think of other alternatives such as endocrowns, an adhesive endodontic crown ^[8, 9].

The terminology “Endocrown” was coined by Bindl and Mormann in 1999 ^[8, 10]. These restorations are anchored to the internal portion of the pulp chamber thus obtaining macromechanical retention provided by the pulpal walls and micro mechanical retention attained using adhesive cementation ^[10].

The purpose of this paper is to present a clinical case in which an extensively damaged mandibular molar with short clinical crown height was restored conservatively using posterior endocrown.

Case report

A 45-year-old male patient reported to K.V.G Dental College and Hospital, Sullia with a chief complaint of decayed tooth in the lower left back teeth region since 1 year. On clinical examination, a large polypoid lesion about 1.5cm ×1.5cm wide, with stalk protruding from the carious cavity of 36 was observed. The tooth presented with extensive coronal tooth structure loss, thin remaining walls and reduced crown height on the lingual aspect (fig 1). On electric pulp testing, tooth showed delayed response. On radiographic examination coronal radiolucency was involving enamel, dentin and pulp and periapically discontinuous lamina dura was present (fig 2). Based on the clinical and radiographic examination the diagnosis was made as chronic hyperplastic pulpitis with apical periodontitis. The treatment plan was formulated as Laser-assisted pulp polyp removal followed by endodontic therapy, laser crown lengthening and restoring the mandibular first molar with an all ceramic endocrown.

Corresponding Author:
Dr. Angeline Jose
Post Graduate Student, KVG
Dental College & Hospital,
Sullia, Karnataka, India

The complete procedure was explained and a written consent was taken from the patient.

Procedure

After administration of local anesthesia, laser-assisted pulp polyp removal was carried out with a diode laser. Root canal treatment was completed in single visit. Due to the insufficient crown height on the lingual aspect of crown, a diode laser at 3.6W in a continuous contact mode was used to perform laser crown lengthening (fig 3). A cervical "sidewalk" preparation was carried out by providing an occlusal reduction of 2mm [8]. Axial preparation was done by only removing undercuts from the access cavity using a tapered bur. Cervical margin was kept supragingival. The depth of the access cavity was kept as 3mm and then 1- mm of gutta- percha was removed from the canals to give access to saddle- like anatomy of floor. A non-uniform ferrule of 1.2 mm was created on the buccal side of the tooth and an occlusal divergence to the cavity walls (fig 4). After the completion of tooth preparation, an impression was taken using gingival retraction cord and polyvinyl siloxane silicone impression material. (fig 5). In this case, a lithium disilicate ceramic (IPS e.Max CAD, fig 6) was chosen due to its superior aesthetics and fracture resistance. The internal surface of the finished restoration was treated with 5% hydrofluoric acid and silane coupling agent (fig 7) while the tooth was etched with 37% phosphoric acid and followed by bonding agent application. The endocrown was cemented on the tooth using dual cure resin cement (fig 8).

Discussion

Endocrowns are minimally invasive preparations which provide maximum tissue conservation [11]. Salient feature of this monolithic ceramic bonded restoration is supragingival butt joint which protects the marginal periodontium, and a central retention cavity inside the pulp chamber. The preparation conserves as much as possible enamel for improved adhesion and invades only the pulp chamber [12]. The cervical sidewalk is the foundation of this restoration, the objective of which is to accomplish a wide, uniform, steady surface resistant to compressive stress [13, 14, 15]. The saddle form of the pulpal floor warrants stability and retention [12].

In today's adhesive dentistry era endocrown can be considered as a conservative and feasible alternative to conventional post & core crown. Endo crowns presented several advantages over posts and cores and crowns as they are easier to prepare and requires lesser clinical time [8, 9]. While preparing endocrown, root strength is preserved and the preparation is done according to pulp chamber anatomic shape. Forces acting on the tooth are dispersed over the cervical butt joint (compression) and axial walls (shear force), thus moderating the load on the pulpal floor. This adhesive restoration can decrease the infiltration of microorganisms from the coronal to the apical part thus improve the clinical success of endodontic treatment [19].

Study conducted by Biacchi *et al.* Showed that Endocrowns are more resistant to compressive forces than the conventional crowns retained by glass fibre posts [20]. Another study observed less stress in teeth with endocrowns compared to teeth with prosthetic crowns. Mandibular molars are subjected to greater masticatory forces and unfavorable stresses [24]. Hence the higher compressive strength combined with lower stress levels acting on tooth made endocrown restoration a suitable option in the present case.

Endocrown is convenient for all molars with suitable pulp

chamber depth, particularly teeth with clinically low crowns, calcified root canals, or narrow canals [25]. But it is not recommended if adhesion cannot be assured, if the pulpal chamber is less than 3mm deep, or the cervical margin is less than 2mm wide for most of its circumference [27].

Endocrown is a perfect combination of biointegration and conservation and can serve as the most appropriate treatment option for restoration of non-vital posterior tooth.

Conclusion

Endocrowns are minimally invasive preparations that preserves the biomechanical integrity of nonvital posterior teeth and can be considered as reliable alternative to post cores and full crowns. It is a promising treatment option for teeth presenting restorative difficulties due to minimal crown height but having sufficient tissue available for stable and durable adhesive cementation.

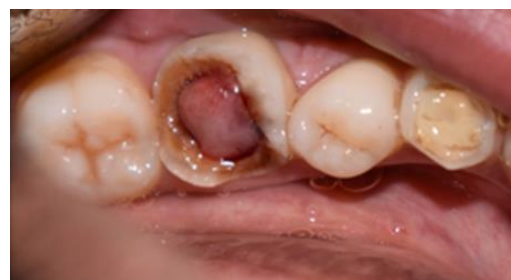

Fig 1: Preoperative clinical photograph

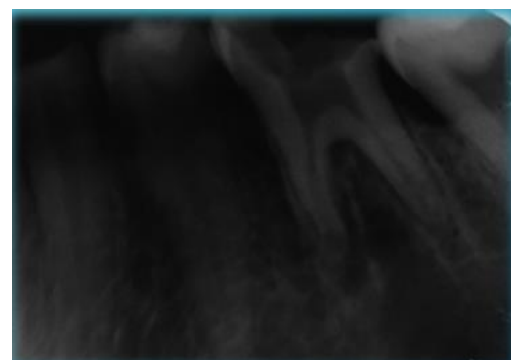

Fig 2: Preoperative radiograph

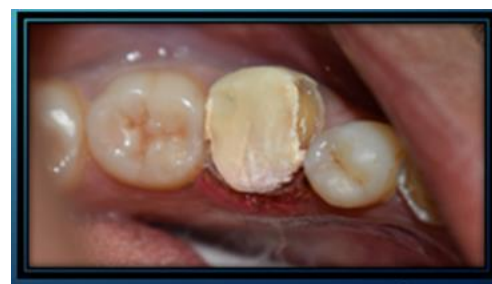

Fig 3: After laser crown lengthening

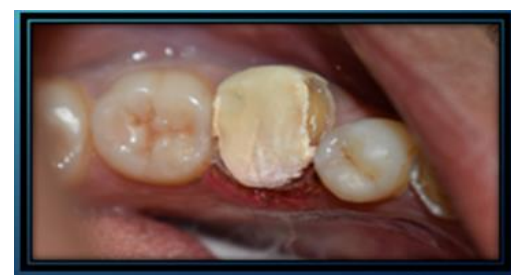

Fig 4: Endocrown preparation

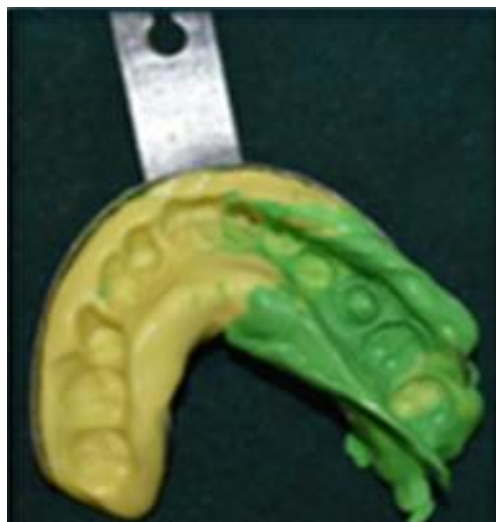

Fig 5: Impression

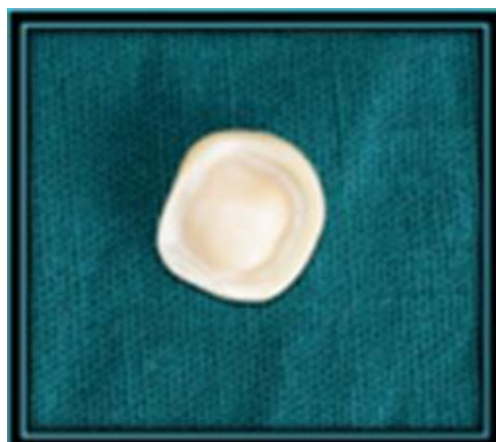
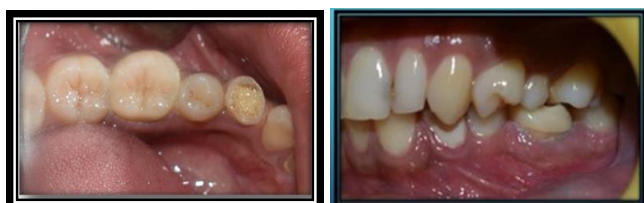
Fig 6: Fabricated all ceramic endocrown




Fig 7: Etching the endocrown



Occlusal view

Buccal view

Fig 8: Final Cemented endocrown

References

1. Christensen GJ. Posts: necessary or unnecessary? The Journal of the American Dental Association. 1996; 127(10):1526.
2. Robbins JW. Restoration of the endodontically treated

- tooth. Dent Clin North Am. 2002; 46:367-84.
3. Rosenstiel S, Land M, Fujimoto J. Contemporary fixed prosthodontics. 5th ed. Philadelphia: Elsevier, 2015, 280-281.
4. Shillingburg H, Sather D. Fundamentals of fixed prosthodontics. 4th ed. Chicago: Quintessence Pub, 2012, 214-216.
5. Rosabiacchi Dds, Ms Beatriz Mello, Dds. Robertatarkany Basting, DDS MS, SCD, PhD The Endocrown: An Alternative Approach for Restoring Extensively Damaged Molars Journal of Esthetic and Restorative Dentistry. 2013; 25(6):383-390.
6. Schwartz RS, Robbins JW. Post placement and restoration of endodontically treated teeth: a literature review. J Endod. 2004; 30:289-30.
7. Sevimli G, Cengiz S, Oruc MS. Endocrowns: review. Journal of Istanbul University Faculty of Dentistry. 2015; 49(2):57-63.
8. Bindl WH Mörmann. Clinical evaluation of adhesively placed cerec endo-crowns after 2 years: preliminary results, The Journal of Adhesive Dentistry. 1999; 1(3):255-265.
9. Göhring TN, Peters OA. Restoration of endodontically treated teeth without posts, American Journal of Dentistry. 2003; 16(5):313-317.
10. Lander E, Dietschi D. Endocrown: a clinical report. Quintessence Int. 2008; 39:99-106.
11. Van Meerbeek B, Perdigão J, Lambrechts P, Vanherle G. The clinical performance of adhesives. J Dent. 1998; 26:1-20.
12. The Endocrown: A Different Type of All-Ceramic Reconstruction for Molars. Michel Fages, DDS, PhD; Bertrand Bennasar, DDS. J Can Dent Assoc. 2013; 79:d140.
13. Endocrown: An Alternative Approach for Restoring Endodontically Treated Molars with Large Coronal Destruction.
14. Debbabi I, Nouira Z, Saafi J, Harzallah B, Cherif M. Endocrown: A Reliable Alternative to Restorate RCT Molar! - Two Case Reports. Adv Dent & Oral Health. 2018; 9(5):555774.
15. Zogheib LV, Saavedra Gde S, Cardoso PE, Valera MC, Araújo MA. Resistance to compression of weakened roots subjected to different root reconstruction protocols. J Appl Oral Sci. 2011; 19(6):648-54.
16. Fages M, Bennaser B. The endocrown: a different type of all-ceramic reconstruction of molars, Journal of the Canadian Dental Association. 2013; 29(79), article d140.
17. Einhorn M, DuVall N, Wajdowicz M, Brewtser J, Roberts H. Preparation ferrule design effect on endocrown failure resistance. J Prosthodont. 2019; 28:e237-42.
18. Taha D, Spintzyk S, Schille C, Sabet A, Wahsh M, Salah T *et al*. Fracture resistance and failure modes of polymer infiltrated ceramic endocrown restorations with variations in margin design and occlusal thickness. J Prosthodont Res. 2018; 62:293-7.
19. Shah RJ, Lagdive S, Verma V, Shah S, Saini S. Rehabilitating endodontically treated mandibular molar having inadequate coronal length with Endocrown - A neoteric clinical approach. IOSR J Diagn Med Sonography. 2017; 16:29- 33.
20. Biacchi GR, Basting RT. Comparison of fracture strength of endocrowns and glass fiber post-retained conventional crowns, Operative Dentistry. 2012; 37(2):130-136.

21. Sedrez-Porto JA, da Rosa WL, Da Silva AF, Münchow EA, Pereira-Cenci T. Endocrown restorations: a systematic review and meta-analysis. *Journal of dentistry*. 2016; 52:8-14.
22. Chang CY, Kuo JS, Lin YS, Chang YH. Fracture resistance and failure modes of CEREC endo-crowns and conventional post and core-supported CEREC crowns. *J Dent Sci*. 2009; 4(3):110-7. 10.1016/S1991-7902(09)60016-7
23. Pashley DH, Tay FR, Breschi L, Tjaderhane L, Carvalho RM, Carrilho M *et al*. State of the art etch-and-rinse adhesives *Dental Materials*. 2011; 27(1):1-16.
24. Dejak B, Młotkowski A, Romanowicz M. Finite element analysis of stresses in molars during clenching and mastication. *The Journal of prosthetic dentistry*. 2003; 90(6):591-7.
25. Biacchi GR, Mello B, Basting RT. The endocrown: an alternative approach for restoring extensively damaged molars, *Journal of Esthetic and Restorative Dentistry*. 2013; 25(6):383-390.
26. De Souza G, Braga RR, Cesar PF, Lopes GC. Correlation between clinical performance and degree of conversion of resin cements: a literature review, *J Appl. Oral Sci*. 2015; 23(4):358-368.
27. Veselinovic V, Todorovic A, Lisjak D, Lazic V. Restoring endodontically treated teeth with all ceramic endo-crowns case report, *Stomatoloski Glasnik Srbije*. 2008; 55:54-64.
28. Litzemberger AP, Hickel R, Richter MJ, Mehl AC, Probst FA. Fully automatic CAD design of the occlusal morphology of partial crowns compared to dental technicians' design. *Clinical oral investigations*. 2013; 17(2):491-6.