



ISSN Print: 2394-7489  
ISSN Online: 2394-7497  
IJADS 2020; 6(2): 06-08  
© 2020 IJADS  
[www.oraljournal.com](http://www.oraljournal.com)  
Received: 04-02-2020  
Accepted: 08-03-2020

**Mahima Gupta**  
3rd yr Post graduate student,  
Department of Orthodontics and  
Dentofacial Orthopedics,  
Subharti Dental College, Meerut,  
Uttar Pradesh, India

**Shalu Jain**  
Associate Professor, Department  
of Orthodontics and Dentofacial  
Orthopedics, Subharti Dental  
College, Meerut, Uttar Pradesh,  
India

**Pradeep Raghav**  
Professor and Head, Department  
of Orthodontics and Dentofacial  
Orthopedics, Subharti Dental  
College, Meerut, Uttar Pradesh,  
India

**Stuti Mohan**  
Associate Professor, Department  
of Orthodontics and Dentofacial  
Orthopedics, Subharti Dental  
College, Meerut, Uttar Pradesh,  
India

**Shreeyesh Gupta**  
3rd yr Post graduate student,  
Department of Orthodontics and  
Dentofacial Orthopedics,  
Subharti Dental College, Meerut,  
Uttar Pradesh, India

**Corresponding Author:**  
**Mahima Gupta**  
3rd yr Post graduate student,  
Department of Orthodontics and  
Dentofacial Orthopedics,  
Subharti Dental College, Meerut,  
Uttar Pradesh, India

## **A conventional yet effective approach to relieve severe crowding due to ectopically erupted lower incisors: A case report**

**Mahima Gupta, Shalu Jain, Pradeep Raghav, Stuti Mohan and Shreeyesh Gupta**

### **Abstract**

Traditionally, patients with severe crowding are treated by extracting teeth, using fixed lingual expansion arch, schwarz appliance or jockey wires. In this case report, an alternative approach for relieving severe lower anterior crowding in 12 year old boy was done. a non extraction treatment protocol was followed using expanded Australian and Stainless Steel archwires. The apparent benefit of this approach was related not only to the esthetic improvement of the smile resulting from elimination of the anterior crowding, but also an alternative conservative and conventional treatment protocol was followed.

**Keywords:** Australian wire, stainless steel wire, expansion, crowding

### **Introduction**

In the profusion of orthodontic complaints, crowding has marked its importance by being at the zenith of the list. Proper diagnosis and accurate treatment planning in such cases are often challenging and demanding. Critical evaluation of models, radiographs and soft tissue down to millimeter contribute in formulating the treatment plan. However, the most valid treatment option depends on patient's choice while orthodontists merely play a guiding role.

For correction of crowding, the conventional extraction protocol is the first option to be followed to bring about the correction without compromising the ideal occlusion<sup>[1-2]</sup>. But, this does not hold true for all orthodontic cases and the final treatment plan should be based on the type of discrepancy present in both upper and lower arch<sup>[3]</sup>.

Apart from this, crowding can also be corrected by expanding the arch and utilizing this expansion space instead of gaining space by extraction.

The present article is a case report of one severely crowded case treated using non-extraction treatment modality

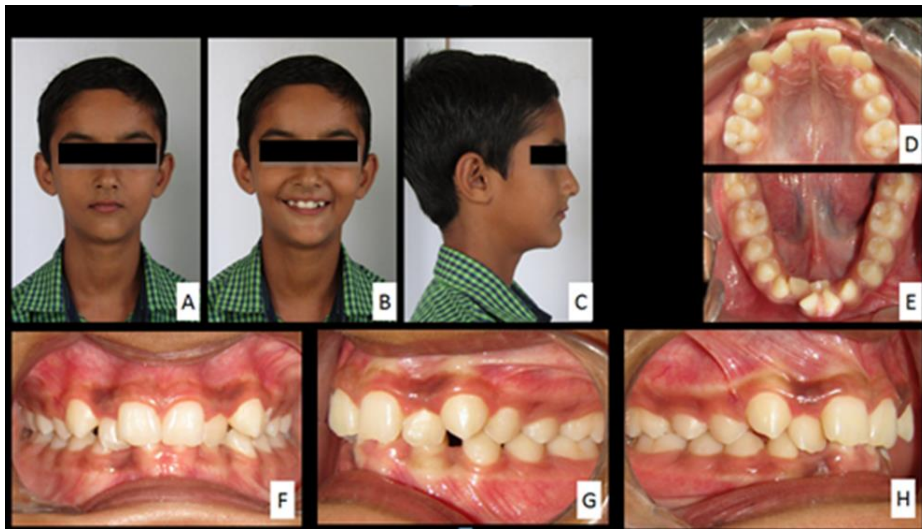
### **Case report**

A 12-year-old boy reported to the department of Orthodontics and Dentofacial Orthopaedics with a chief complaint of irregular teeth. The initial clinical examination showed a slightly retrusive mandible with normal nasolabial angle and competent lips.

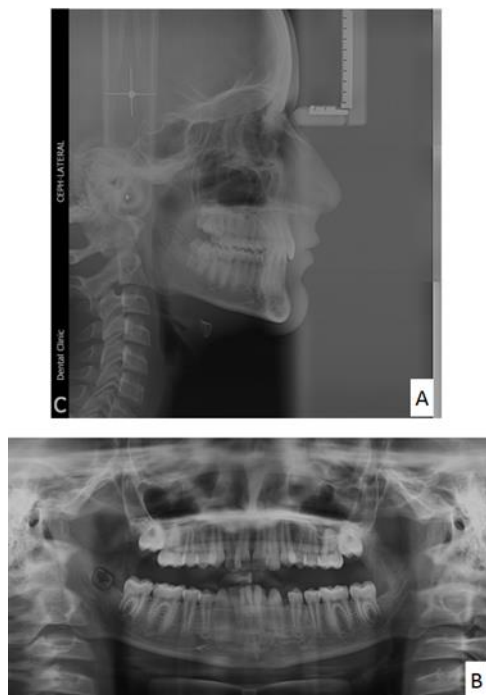
The intraoral examination and study casts exhibited Class I molar relationships on both sides (fig 1). The maxillary right and left lateral incisors were palatally positioned. The maxillary midline was 2.0 mm off to the right of the facial midline, and the mandibular midline was symmetrically correct. Crowding was severe as a result of ectopically placed incisors in both the arches but the situation was worse in lower arch (fig 1D and E).

Study cast analysis showed an overbite of 4.0 mm and an overjet of 1.5 mm. On total space analysis, 3.3 mm of space was available in upper arch and 5 mm of space was available in lower arch.

The Lateral cephalometric analysis showed a Class I skeletal base (ANB 3°) with a orthognathic maxilla and mandible (SNA- 82° and SNB 79°), and low mandibular plane angle (FMA- 20°) (fig 2). Upper and lower incisors were retroclined (UI to NA -11°, LI to NB- 10°). Lower incisors were rotated and upper canines were buccally placed. Ashley howes and ponts analysis were suggestive of expansion in both upper and lower arch.



**Fig 1:** Pretreatment photographs



**Fig 2:** Pretreatment radiographs

### Treatment objectives

1. To relieve crowding by bringing the palatally positioned incisors into alignment in both the arches
2. To restore a satisfactory occlusion with class I molar and canine relationships
3. To correct the shifted midline
4. To create ideal overbite and overjet
5. To improve the facial esthetics

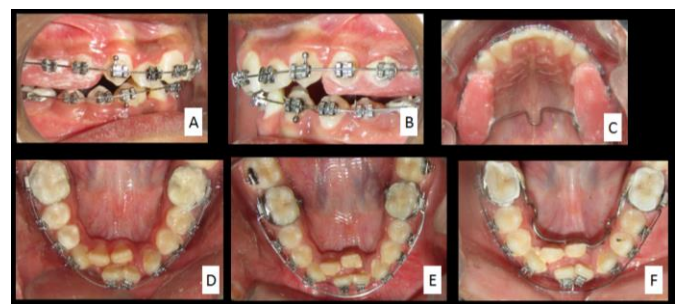
### Treatment plan

This preteen patient had adequate growth potential, with an acceptable profile but with a retroclined maxillary and mandibular anterior dentition. Maxillary lateral incisors and mandibular incisors were palatally positioned, but there were no signs of defects in the overlapping areas between the adjacent dentition. According to total space analysis, space was available in both upper and lower arch. Also Ashley howes and ponts analysis were suggestive of expansion in both upper and lower arch. So a non-extraction treatment plan was proposed.

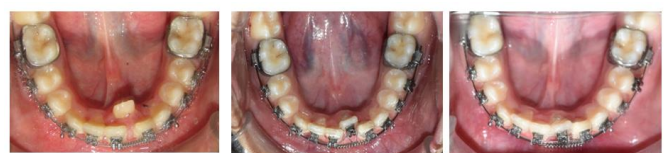### Treatment progress

The treatment began with the bonding of Pre-adjusted 0.018-in brackets (Ormco Corporation, Orange, CA) to the maxillary and mandibular arches, and a 0.012-in nickel-titanium wire was engaged for alignment of teeth. In lower arch, the in-standing lower incisors were not bonded initially. At the same time, lingual holding arch was cemented in lower arch and posterior bite block was placed to open the bite. After the initial wire, 0.014 NiTi, 0.016 NiTi, followed by 0.016×0.022” NiTi wire were placed for the sequential leveling. Stainless steel wire of 016×022” in upper and lower arch was used for final leveling.

After levelling was complete, expanded 0.016X 0.022 stainless steel wire was placed in lower arch. After 2 months, expanded 0.016 australian wire with curve of spee and a stop mesial to molar was ligated in lower arch (fig 3). At the same time lingually placed right central incisor was bonded and sequentially brought into arch using auxillary 0.012 niti wire. To create additional space for bringing the incisors into the arch, open coil spring was added between 32 and 41. Lastly, 31 was brought into arch using wrap around technique (fig 4).



**Fig 3:** Intraoral photographs



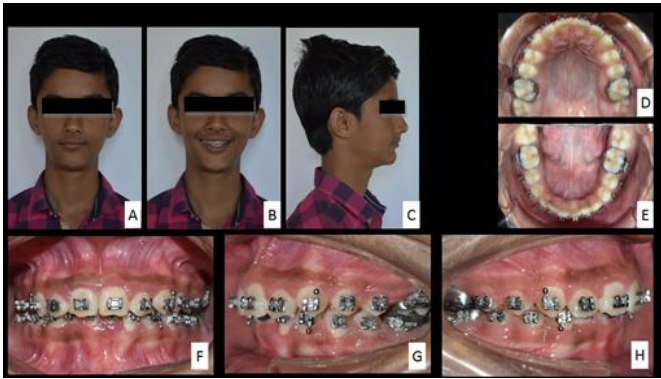
**Fig 4:** Intraoral photographs of wrap around technique

### Treatment results

Severe crowding that resulted from the lingually positioned lower incisors was successfully relieved. The dental midline deviation was also corrected to become consistent with the

facial midline (fig 5).

The posterior occlusal interdigitation was improved and Class I canine and molar relationships on both sides were also achieved. Ideal overbite and overjet relationships were restored. The patient's facial esthetics were also improved.



**Fig 5:** Intraoral and extraoral present photographs

### Discussion

For rectification of severe crowding, the conventional extraction protocol is the first option to be followed to bring about the correction without compromising the ideal occlusion. But, this does not hold true for all orthodontic cases and the final treatment plan should be based on the type of discrepancy present in both upper and lower arch.

Apart from this, crowding can also be corrected by expanding the arch and utilizing this expansion space instead of gaining space by extraction.

The comprehensive orthodontic treatment of this patient who presented with severe lower crowding was completed without extraction of any teeth which similar cases may require.

In today's era, patient's comfort is an important factor during the selection of the orthodontic treatment modality. There are various alternatives for dentoalveolar expansion such as fixed lingual expansion arch and a removable Schwartz appliance<sup>5</sup>. However, these appliances had greater potential to interfere with speech and swallowing.

Another option for achieving expansion is the utilization of Jockey wire appliance. Traditionally, it has been used as a more comfortable option for dentoalveolar expansion<sup>6</sup>. However, this appliance requires headgear tubes on the first molar bands making it a little uncomfortable for an adolescent patient. To overcome this problem, another alternative was to use expanded Australian wire and stainless steel wire that can be passed through the single slot molar tube and still can get the same effect as of jockey wire.

Another advantage of the Australian wire in comparison with the jockey arch appliance is that it is more resilient<sup>7</sup>, making the former more comfortable for the patient.

So, in this patient for correction of the transverse plane, the width of the lower arch was enlarged by using expanded Australian wire as it is highly resilient with property of zero stress relaxation and stainless steel wires. The spaces created by dental expansion were mainly used to align the lower anterior teeth, especially the right lateral incisor and left central incisor, which required considerable space to be labialized.

To treat this patient without extractions, a significant amount of lower arch expansion was critical.

### Conclusion

Adopting conventional method of expanding arch using expanded archwire can be used as an alternative to the

extraction of incisor, but careful case selection is important. Also innovative wrap around method was proved beneficial to bring lingually placed incisor back into arch without tipping.

### References

1. Raju DS, Veereshi AS, Naidu DL, Raju BH, Goel M, Maheshwari A. Therapeutic extraction of lower incisor for orthodontic treatment. *J Contemp Dent Pract.* 2012; 13(4):574-79.
2. Kokich VG, Shapiro PA. Lower incisor extraction in orthodontic treatment. *Angle Orthod.* 1984; 54:139-53.
3. Howe RP, McNamara JA Jr, O'Connor KA. An examination of dental crowding and its relationship to tooth size and arch dimension. *Am J Orthod.* 1983; 83:363-73.
4. Thirunavukkarasu VN, Ramachandra SS, Dicksit DD, Gundavarapu KC. Extraction protocols for orthodontic treatment: A retrospective study. *Contemp clinic dentistry.* 2016; 7(1):41-44.
5. Betts NJ, Vanarsdall RL, Barber HD, Higgins-Barber K, Fonseca RJ. Diagnosis and treatment of transverse maxillary deficiency. *Int J Adult Orthodon Orthognath Surg.* 1995; 10:75-82.
6. Gill D, Naini F, McNally M. The Management of Transverse Maxillary Deficiency ANDA. *JONES Dent Update.* 2004; 31:516-523.
7. Structure, Composition, and Mechanical Properties of Australian Orthodontic Wires (*Angle Orthod.* 2009; 79:97-10).