



## International Journal of Applied Dental Sciences

ISSN Print: 2394-7489  
ISSN Online: 2394-7497  
IJADS 2020; 6(2): 433-435  
© 2020 IJADS  
[www.oraljournal.com](http://www.oraljournal.com)  
Received: 07-02-2020  
Accepted: 09-03-2020

**Dr. Pooja Katkade**  
PG. Student Dept of  
Orthodontics, RDC, Loni,  
Uttar Pradesh, India

**Dr. NG Toshniwal**  
H.O.D, Dept of Orthodontics,  
RDC, Loni, Uttar Pradesh, India

**Dr. Shubhangi Mani**  
Professor, Dept of Orthodontics,  
RDC, Loni, Uttar Pradesh, India

**Dr. Nilesh Mote**  
Professor, Dept of Orthodontics,  
RDC, Loni, Uttar Pradesh, India

**Dr. Vishal Dhanjani**  
Professor, Dept of Orthodontics,  
RDC, Loni, Uttar Pradesh, India

### Fixed- functional appliance therapy using flex developer in a skeletal class II patient

**Dr. Pooja Katkade, Dr. NG Toshniwal, Dr. Shubhangi Mani, Dr. Nilesh Mote and Dr. Vishal Dhanjani**

#### Abstract

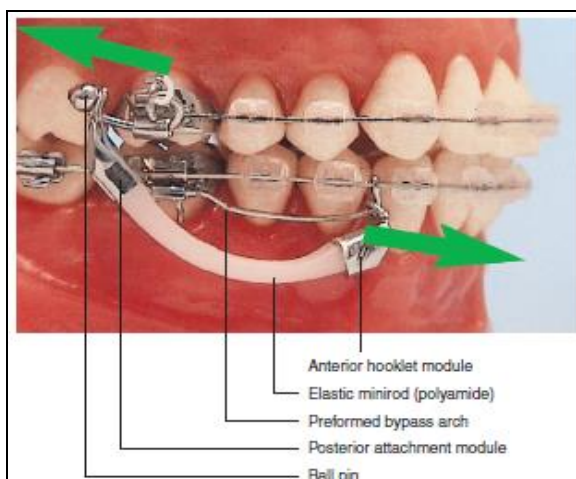
A properly selected functional appliance can achieve optimal results in a Class II patient. A removable functional appliance can advance the mandible, but requires excellent patient compliance. Moreover, it can cause intermittent condylar displacement and consequent glenoid fossa remodeling. In contrast, fixed functional appliances have been shown to produce remarkable changes in the glenoid fossa-condyle complex.

**Keywords:** Fixed functional appliance, flex developer, class II correction

#### Introduction

Class II Malocclusion is the most commonly occurring malocclusion in India. Mainly characterised by mandibular retrusion. Treatment modality aims to stimulate forward mandibular growth. Age of patient and selection of appliance plays an important role in the outcome of the treatment. Growth modification using functional appliances achieves stable result in class II patients. There are wide variety of fixed and removable appliances for treating a Class II malocclusion. Amongst the various available fixed functional appliances the Flex developer is the most powerful and indestructible noncompliance intermaxillary Class II mechanism. The Flex developer is combined with a prebent bypass arch, which allows delivery of forces up to 1000 cN and gives additional stability.

Bypass arch also has antirotational and antitipping effect on the attached molar. The flex developer produce up to 1.0 mm tooth movement per month and can also be used unilaterally. Amongst the various available fixed functional appliances the Flex developer is the most powerful and indestructible noncompliance intermaxillary Class II mechanism. The Flex developer is combined with a prebent bypass arch, which allows delivery of forces up to 1000 cN and gives additional stability. Bypass arch also has antirotational and antitipping effect on the attached molar. The flex developer produce up to 1.0 mm tooth movement per month and can also be used unilaterally.



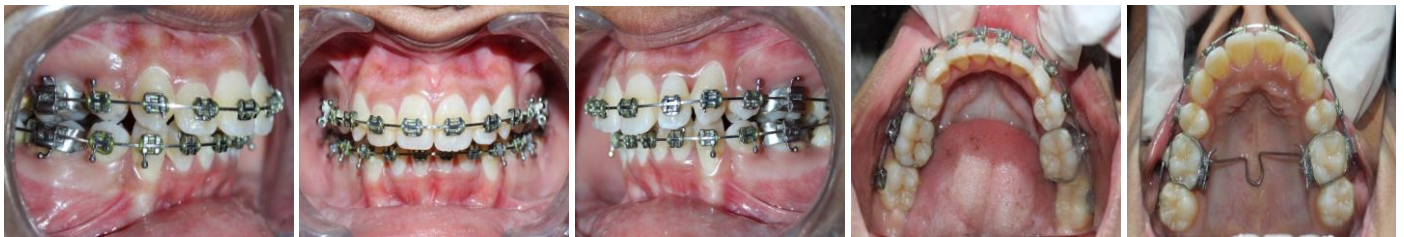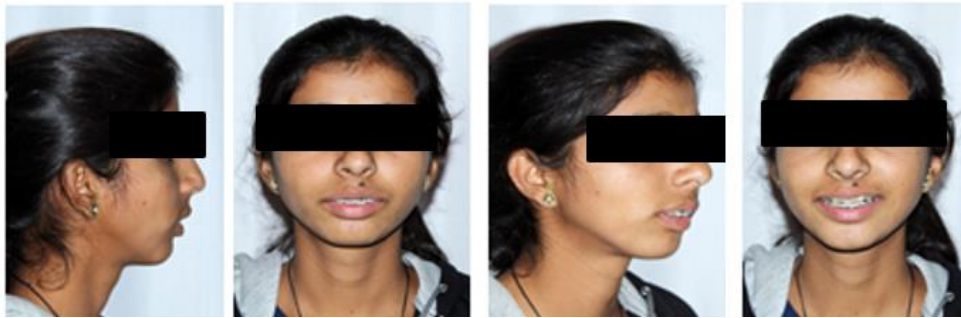**Corresponding Author:**  
**Dr. Pooja Katkade**  
PG. Student Dept of  
Orthodontics, RDC, Loni,  
Uttar Pradesh, India

### Case Report

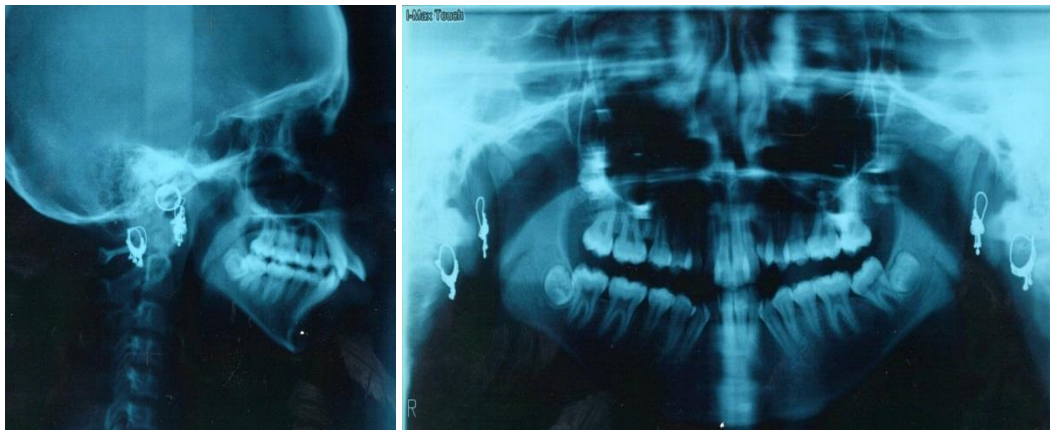
The following case illustrates the use of Flex Developer as a Fixed Functional Appliance in the correction of a Class II malocclusion.

### Diagnosis and treatment plan

A 16-years-old female presented with the chief complaint of proclined upper front teeth. She exhibited a convex profile with incompetent lips at rest. A Class II, division 1 relationship on a mild Class II skeletal base was observed, with slightly deficient vertical proportion complicated by a 7mm overjet and excessive overbite.



**Fig 1:** 16years-year-old female patient with proclined upper incisor and class II divI relationship on mild skeletal class II base after leveling and alignment on 19-25SS



### Cephalometric Findings

#### Patient belongs to skeletal Class 2

- ANB :6°
- Wits Value: AO ahead BO 6mm
- beta- Angle:24°

#### Maxilla Orthognathic

- SNA :75°
- Na Perp Point A:-4mm
- Effective Maxillary Base Length :51MM (42mm)

#### Mandible Retropositioned

- SNB : 69°
- Na Perp Point Pog :- -10mm
- Effective Mandibular Base Length: 54MM (65mm)

#### Growth Pattern Avergae

- Jarabak Ratio:51.28%
- Facial Axis :2°posterior

- FMPA : 45°
- GONIAL ANGLE :49°
- Y-AXIS : 73°

- Upper Incisors
- U.1 TO NA:32°, 9mm
- U.1 TO SN:106°

- Lower Incisors
- IMPA: 97°
- L.1 TO NB: 34°, 7mm
- L.1 TO N-Pog: 4mm

#### Treatment Objectives

- Correction of Crowding
- Correction to incisor inclination
- Achieve class I canine relationship
- To achieve pleasant smile

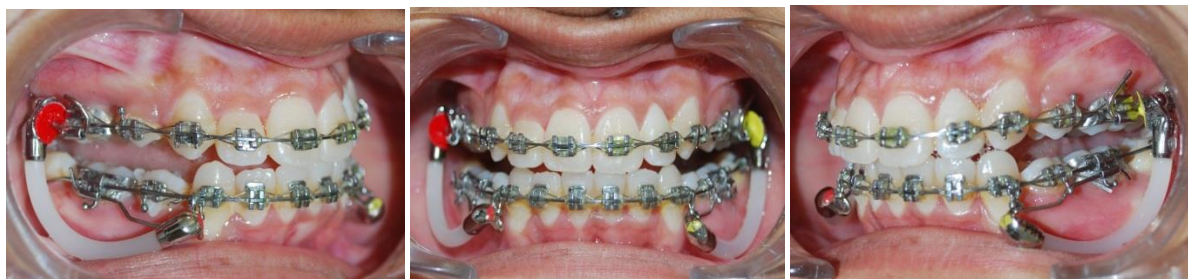

Growth modification was planned using the Flex Developer fixed functional appliance. A transpalatal arch would also be placed to counteract the buccal tipping forces of the fixed functional appliance on the upper first molar.

**Treatment Progress**

Full-arch upper and lower .022 MBT\* preadjusted edgewise appliances were placed, with bands on the first molars and bonded tubes on the second molars. A TPA and a lingual arch fabricated from .036" stainless steel wire were bonded to the

upper and lower first molars, respectively. Leveling and alignment were carried out with sequential archwires, progressing up to full-size 19" x .025" stainless steel. Hooklet of bypass arch situated between the lower canine bracket and lower first premolar bracket. The distance between the anterior surface of the headgear tube and the anterior end of the bypass arch is measured with flex developer ruler. Then, Bilateral 36mm Flex Developer were then attached from the upper first molars to the distal lower canine. (Fig.2)



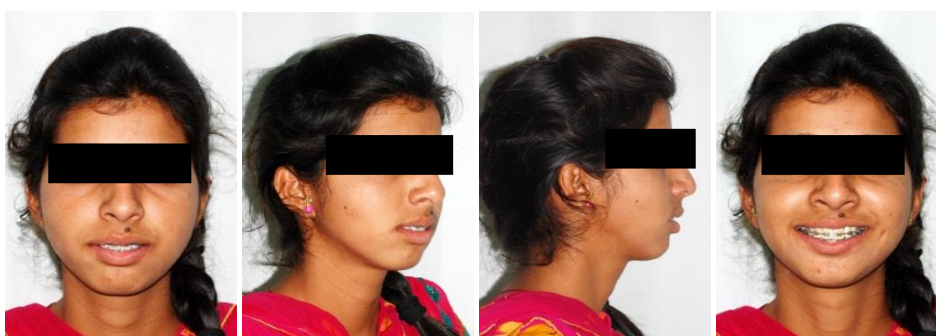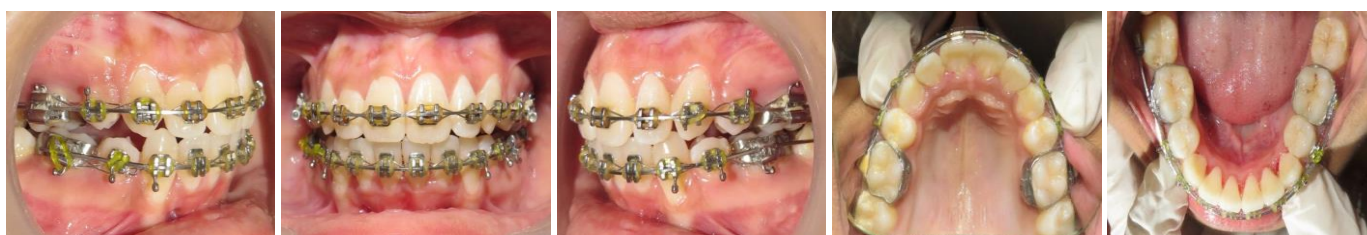**Fig 2:** After insertion of Flex Developer on 19.25ss wire

The patient was recalled every four weeks to monitor progress and check for any appliance damage and activation of appliance. After five months of Fixed functional appliance treatment and 2 months of retention we removed the appliance. There are four different ways to activate the flex developer:

- Shortening of the bypass arch

- Shortening of the pin in the headgear tube
- Placing stop (composite resin) at the anterior part of the bypass arch
- Use of a longer flex developer.

Treatment Results remains stable after 9 months of treatment.



**Fig 3:** After 7 months of removal of appliance

**Discussion**

Fixed functional appliances, in contrast to removable appliances, can produce combination of skeletal and dental changes. When a fixed functional appliance is anchored by the dentition, however most of the dental correction comes from proclination of the mandibular anterior but appliance like flex developer can overcome it. And Anteroposterior skeletal changes included together a reduction in the SNA and ANB with an increase in SNB and effective mandibular length.

**Reference**

1. Case report: Miniscrew-Supported Fixed Functional

Appliance Therapy in skeletal class II patient. JCO, 2019.  
 2. Aslan B: Treatment effects of the Forsus Fatigue Resistant device used with miniscrew anchorage, Angle Orthod, 2014.  
 3. Active Treatment effects of forsus fatigue resistant device during class II correction in growing patient. Kor. J ortho, 2014.