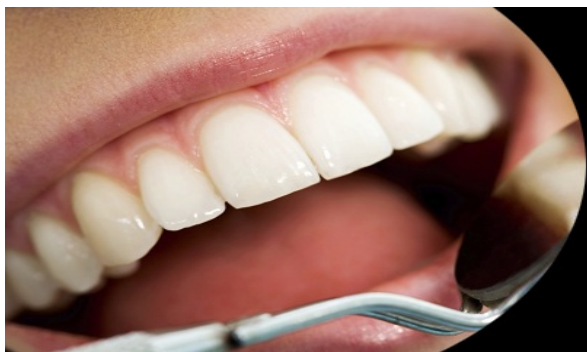



ISSN Print: 2394-7489
ISSN Online: 2394-7497
IJADS 2020; 6(2): 440-445
© 2020 IJADS
www.oraljournal.com
Received: 19-02-2020
Accepted: 23-03-2020

Bassel Alkhoury
Damascus, Mazzeh, Damascus
University, Faculty of Dental,
Syria

Eyad Swed
Damascus, Mazzeh, Damascus
University, Faculty of Dental,
Syria

Clinical and radiographic evaluation of posterior implants supported fixed prosthodontics in faculty of dentistry-Damascus

Bassel Alkhoury and Eyad Swed

Abstract

Statement of problem: Implant-supported prosthodontics is considered the main key and the most important factor regarding the success/failure of dental implants, in order of that, it has to have the majority of focus in this study.

Purpose: It aims to evaluate the clinical and the radial performance of the posterior implant supported fixed prosthodontics that had been made in Damascus University Faculty of Dentistry.

Materials and Methods: the study sample consisted of 100 posterior implant supported fixed metal ceramic prosthodontics which had been made for the reviewer's patients in the fixed prosthodontics session in Damascus University Faculty of Dentistry. Marginal adaptation had been evaluated during the cementation session according to (USPHS) standards, plaque index and gingivitis index had been also evaluated during the cementation session using a plastic periodontal probe that is specially made for dental implants, the values were registered according to Loe index (1967), periodontal probing depth had been evaluated and the values were registered in millimeters, it was done using the periodontal probe in the cementation session. Lastly the prosthesis adaptation and the bone lose were radially evaluated using plastic film holders (Vatic) to make a radiogram using the paralleling technique in the cementation session and all measurements were reevaluated after 6 months of the cementation. Data analysis was done with Wilcoxon test and Rank Biserial test for study correlation at significance level of ($\alpha=0.05$).

Results: all of the prosthodontics that were included in this study have had the evaluation Alfa according to (USPHS) standards. The substantial difference was statistically between the two observation periods included the gingivitis index and the periodontal probing depth index ($p < 0.0005$). Rank Biserial test has shown that there is a statically substantial positive moderate connection between the periodontal probing depth and bone lose.

Conclusions: according to this study we conclude that the continuance rate of the posterior implant supported fixed metal ceramic prosthodontics is 97%, and the gingivitis index, periodontal probing depth and bone lose were at the clinically accepted values during the evaluation session after 6 months of the cementation.

Keywords: Clinical and radiographic, posterior implants, prosthodontics

1. Introduction

Dental implants are considered one of the best solutions to patients' dental problems those whom missed their teeth.

Since the concept of bone osteointegration was discovered by Branemark, the concept of dental implants has entered the context of replacing missing teeth as a new and conservative treatment option 1, whereby at that time the longest implant was used based on the principle that the longer the implant length, the greater the surface of contact with the bone and thus greater retention and stability which make the implant leads to longer survival rates, but at the present time with the development of implant surface treatment techniques a short implant can be developed with very successful results.

There are some anatomical determinants that hinder the position of the implant, such as the dental alveolar nerve in the lower jaw and the maxillary sinus in the upper jaw, which makes implant placement difficult in some cases due to insufficient bone length, and in these cases we resort to advanced surgical procedures to increase bone height such as Lift the maxillary sinus, bone grafts, and the alveolar nerve offset before implantation.

Corresponding Author:
Bassel Alkhoury
Damascus, Mazzeh, Damascus
University, Faculty of Dental,
Syria

The use of fixed prosthodontics supported by multiple implants gave good clinical results in both the short and long term and dental implants with single crowns also recorded high success rates and lower mechanical complications compared to fixed prosthodontics supported with multiple implants.

In 2014, Clark and his colleagues conducted a randomized clinical study of implant-supported porcelain fused to metal prosthesis in the posterior area, registering a clinical survival and success rate of over 95%.

In terms of connection type, mechanical complications were more noticeable in screw-retained prosthesis compared to cement-retained prosthesis especially porcelain material fracture, prop screw dissolution, stability loss.

Both porcelain fused to metal prosthesis and full ceramic prosthesis are used in fixed implant-supported prosthesis for having high cosmetic properties.

The choice of the type of prosthesis supported by implants, whether fixed or removable depends on several factors such as the presence of good soft and hard tissue, in addition to the patient's desire and expectations

The fact that the implant-supported prosthodontic is the primary criterion for the success of the dental implant, as it has a role in the distribution of occlusal efforts, which is the link between the oral cavity and the implant.

Hence, the idea of this research came to evaluate the implant-supported prosthodontics performed by Fixed-prosthodontics specialist (i.e. according to scientific principles) to illuminate the Aspects that may affect this prosthesis.

2. Materials and Methods

The research sample consisted of 100 posterior implant

supported PFM fixed prosthodontics (crowns and bridges) fixed by cement among patients attending the fixed prosthodontics department at the Faculty of Dentistry at the University of Damascus and excluding immediate loading.

After examining the patients, the patients with the following conditions were accepted:

- 1) Plaque index should be 0 when lutting prosthodontics.
- 2) Index of bleeding and gingivitis should be 0 when lutting prosthodontics.
- 3) There is stable occlusion in the posterior region.
- 4) The implants and their prosthodontics are in the posterior area.
- 5) There is no radial bone absorption around implants within the clinically acceptable limits for implant success of 1 mm.

The questionnaire designed for this research was filled in by the researcher in the cementation Session, where the patient's gender, age and number were recorded for follow-up after six months, the case number, the name of the attending dentist, and the patient's poor non-functional habits.

The patient was also asked about the smoking habit. The patient's chief complaint was recorded and the indication for treatment was recorded.

Initially the marginal fit of the prosthesis was examined in the cementation session and re-examined after 6 months, where the edges of the prosthesis were examined by a sharp dental probe to check the marginal fit and the corresponding symbols were given to the case according to the USPHS criteria according to the table (1).

Table 1: USPHS criteria for marginal fit of the prosthesis examination

Indication	Symbol
There is no visible evidence of a gap between the prosthesis and the abutment structure	Alpha
There is visible evidence of a void between the edges of the prosthesis and abutment structures, and the probe is stuck but not executed	Bravo
There is visible evidence of a void between the edges of the prosthesis and abutment structures, and the probe is suspended and executed	Charlie

This is followed by an examination of the bacterial plaque index by using a dental implant proper designed from plastics in the cementation session, and after 6 months of cementation

Figure (1), and recording the values according to the Loe index (1967):

Table 2: Loe Index of gingival plaque

Significant	symbol
There is no plaque	0
1 A thin layer of plaque adheres to the free gingival gingiva	1
There are medium plaque positions inside the gingival pocket and gingival edge	2
There are severe plaques in the gingival pocket and gingival edge	3

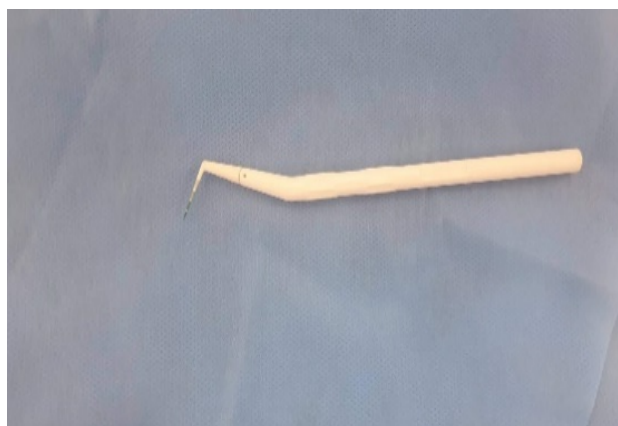

Fig 1: Plastic gingival proper

Then the gingivitis index was examined by the same plastic gingival proper in the cementation session and after 6 months

of cementation according to the gingivitis (LOE (1967).

Table 3: LOE Index of Gingivitis

Significant	symbol
The absence of any noticeable sign of periodontitis and normal gums	0
Mild inflammation: slight color change and slight edema, without sounding bleeding	1
Inflammation is moderate: redness, edema, luster, and susceptibility to bleeding after sounding	2
Severe inflammation: redness, edema, pronounced gloss, spontaneous bleeding	3

This is followed by examining the depth of the pockets using the gingival gland for implantation, from a reference point determined on compensation to the deepest point in the pocket without applying sounding forces where the probe is placed parallel to the longitudinal axis of the implant, where the value of the depth of the sinuses in millimeters was recorded in the sticky compensation session and after 6 months From sticking figure (2).

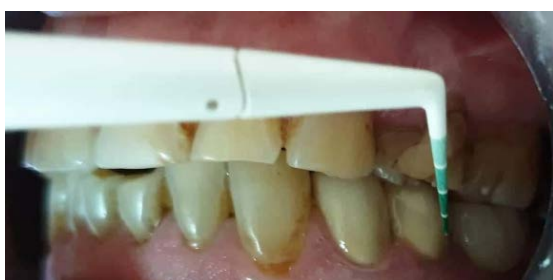

Fig 2: Propping depth of the pockets

This is followed by examining the applicability of radial compensation in the compensation sticking session and after 6 months of adhesion, where a ray image was taken by a digital sensor and a wall ray machine, and the imaging angles for each patient were standardized via a silicone (rubber) bite for each patient that was kept And writing his name on it until the review after 6 months, to ensure that the axes of photography in the two visits do not differ.

Vatech plastic film holders were used to secure a parallel image in order to avoid lengthening or shortening of the image.

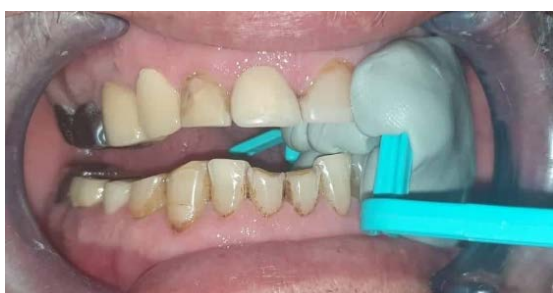

Fig 3: Fixing plastic film holder using silicon bite



Fig 4: Plastic holder with silicon bite

The bone absorption around the implants was examined and investigated after 6 months in the event of its presence or not, compared to the radiograph image taken in the cementation session.

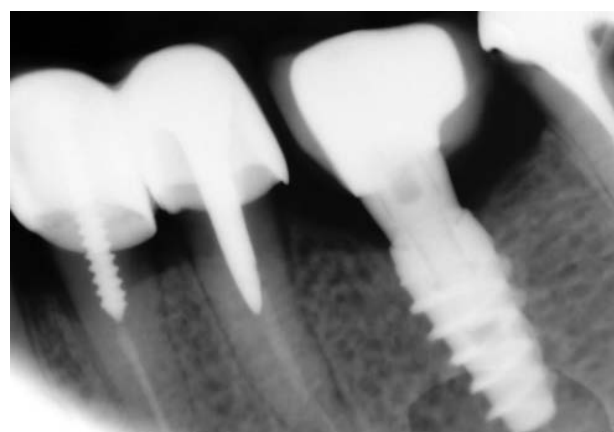


Fig 5: Radiographic image taken in cementation session

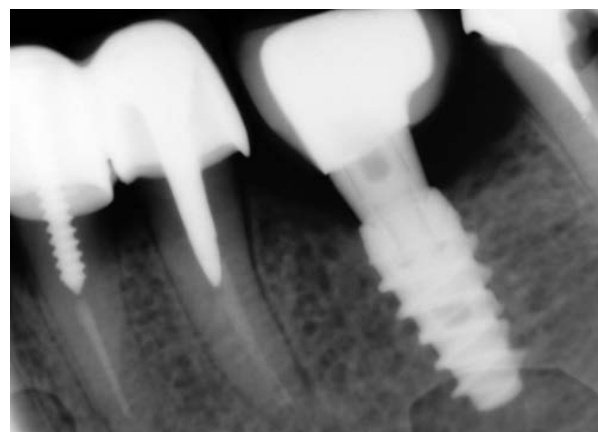

Fig 6: Radiographic image taken after 6 months

This is followed by investigating the disintegration of prosthodontics in the event of his or her absence after 6 months of applying the prosthodontics, and then investigating the pattern of dissolution in the event of its existence according to the following schedule:

Table 4: Detecting dislocation pattern

Significant	Symbol
Screw rotation	*
Cement decay	+

3. Results

The study sample consisted of 34 patients with 100 fixed prosthodontics supported by implants.

The percentage of males reached 67.6% (23 patients) and females 32.4% (11 patients).

The ages of the patients ranged between 24-75 years, with an

average score of 47.79 years.

Where the sample consisted of 26 first premolar (26%), 28 second premolar (28%), 35 first molar (35%) and 11 second molar (11%).

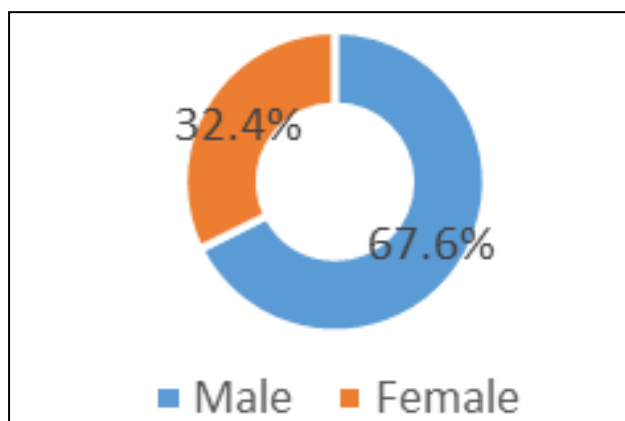


Fig 7: Male and female ratio in study patients

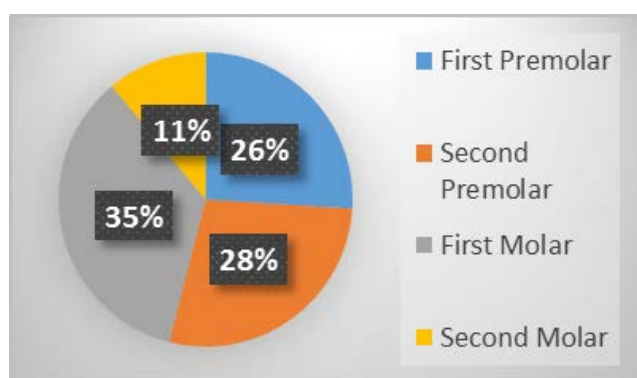


Fig 8: The study sample is distributed according to the implants site

With regard to the applicability of prosthodontics, all study prosthodontics received an alpha evaluation, meaning that there was no visible evidence of a gap between prosthodontics and support.

When applying prosthodontics, all prosthodontics received a 0 rating for plaque index and gingivitis.

After 6 months of observation, 12% of the prosthodontics received a grade of 1 and 1% a grade of 2 in the gingivitis index.

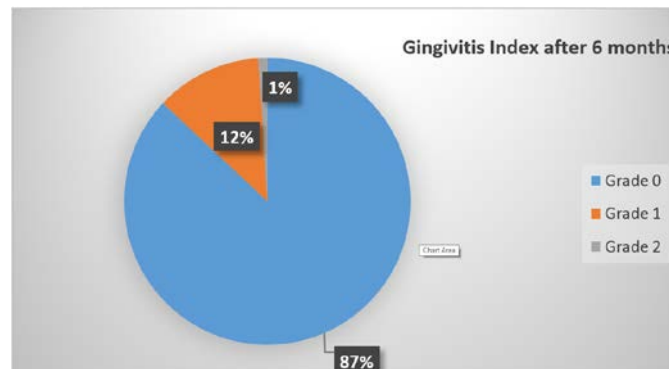


Fig 9: Gingivitis Index after 6 months

As for the depth of propping index, it reached 2 mm in prosthodontics, 6 mm in prosthodontics, 3 mm in 46%, 4 mm in 43%, and 5 mm in 2% of them, and after 6 months It became 2 mm in 5% of prosthodontics, 3 mm in 40%, 4 mm in 46%, 5 mm in 9% of it.

With regard to the disintegration of prosthodontics, 3 cases of disassociation of prosthodontics were recorded as a result of the dissolution of cement, while the disintegration did not occur in the rest of the prosthodontics.

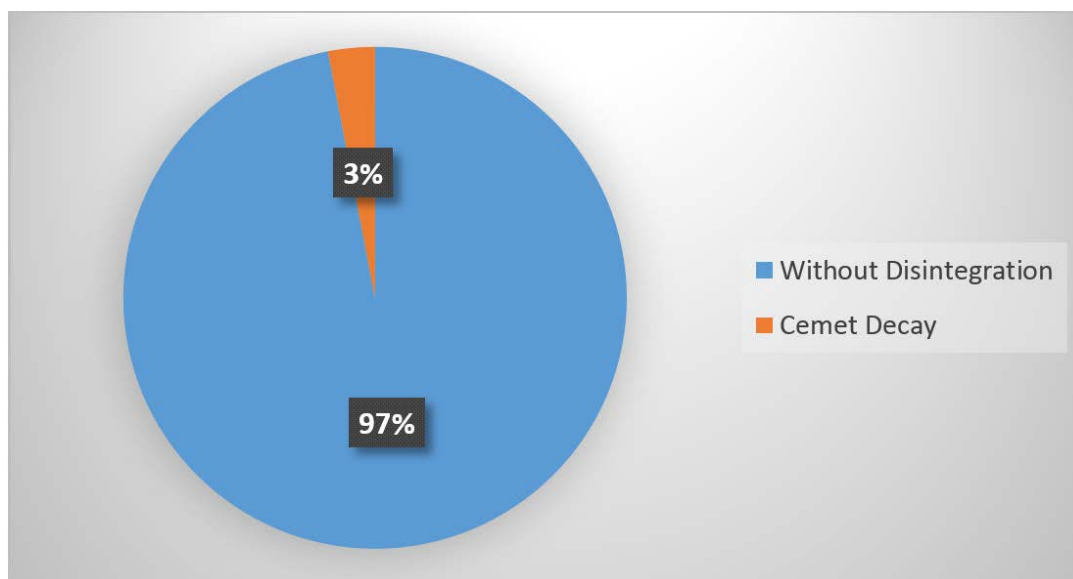


Fig 10: Percentage of prosthodontics dislocation in the study sample

Table 5: Repetition and absorption percentages around implants after 6 months

Total	Horizontal absorption	No absorption	
100	16	84	Repetition
100%	16%	84%	percentage

The correlation between depth of propping after 6 months and bone absorption was studied, where bone absorption was

found in 19.6% of cases in which the depth of propping was 4 mm, and in 77.8% of cases where the depth of propping was 5 mm.

The Rank Biserial test was used to study the association between depth of propping after 6 months and bone absorption and the test showed a statistically significant positive mean correlation between the two variables ($r = 0.496, p < 0.0005$).

Table 6: Repetition and percentages of propping depth index when cementation session and six months after it

Total	Bone Absorption				
	Horizontal	No			
5	0	5	Repetition	2 mm	depth of propping index
100.0%	0.0%	100.0%	%		
40	0	40	Repetition	3 mm	
100.0%	0.0%	100.0%	%		
46	9	37	Repetition	4 mm	
100.0%	19.6%	80.4%	%		
9	7	2	Repetition	5 mm	
100.0%	77.8%	22.2%	%		
16	84	Repetition	Repetition	Total	
16.0%	84.0%	%	%		
r = 0.496, p < 0.0005			Rank Biserial		

4. Discussion

The posterior region of the upper and lower jaw is the most common area of dental implants, especially in cases of edentulous, as it is not possible to make a fixed bridge, in addition to the unwillingness of patients to place a removable prosthesis.

Short implants are usually placed in the posterior region of the upper or lower jaw, where the bone quantity and quality are somewhat weak, so long crowns of the posterior implants are placed to reach the level of the occlusion, so the ratio of the crown to the implant is greater, which increases the applied efforts on The implant and thus absorption in the marginal bone around the implant and the failure of implant hence the idea of this research came to evaluate the clinical and radiological performance of fixed posterior prosthodontics supported by dental implants performed at the Faculty of Dentistry at Damascus University.

The rate of survival of the fixed-prosthodontics supported by the implants accomplished in this study was high despite the occurrence of the disintegration of prosthodontic as a result of the disintegration of cement by 3%, and the reason for this may be that the screws are tightened with the Rochet key well with the implants, and therefore the failure of the link at the expense of the dissolution of cement It is not due to the rotation of the screws, and also that it is in the posterior region. The abutments are in some cases short due to the gingival-occlusal distance between them and thus the contact surface between the abutment and its prosthesis is small, and thus the stability is minimal. We agreed on this point with the study of Jung and his colleagues in 2012, where they found that the rate of survival of the porcelain fused to metal crowns in the posterior area is high, despite the disintegration of prosthodontic due to the dissolution of cement by 4.1% 19.

Lee and colleagues found in 2015 that the percentage of failure to prosthodontics supported by implants in the posterior region due to the degradation of cement was high, as it was 18.1% 11.

With regard to the applicability of prosthodontic, all study prosthodontics obtained an alpha evaluation, that is, there was no visible evidence of a gap between prosthodontic and abutment, and this was in agreement with the study of Oyagüe and colleagues in 2009, where they found that the marginal applicability values of porcelain fused to metal prosthesis supported by implants within the clinically acceptable values. The bacterial plaque index and gingivitis index were among the clinically acceptable values, and this was consistent with the Beuer and colleagues study in 2016, where they found that the gingival indications values for the prosthodontics supported by implants performed in the posterior region within the normal values.

There was a positive correlation between propping depth after 6 months and bone absorption, where bone absorption occurred in 19.6% of cases in which the depth of propping was 4 mm, and in 77.8% of cases where the propping depth was 5 mm, this is normal because there is a relationship Close between propping depth and bone absorption, this was consistent with the study by Jung and colleagues in 2012, where they found a relationship between histopathology around the implant and increased depth of propping and bone absorption around implants.

5. Conclusions

Within the limits of this study, the following was concluded:

- 1) The survival rate of the porcelain fused to metal prosthodontics supported by implants in the posterior region was 97%.
- 2) Index of gingivitis, propping depth and bone absorption after 6 months of adhesion was included in the clinically acceptable values.

6. Recommendations

It is recommended that in the posterior area, the implant-supported prosthodontics is attached, and in the event that the supports are short, use the cement with high fixative strength.

7. References

1. Albrektsson T, Jacobsson M. Bone-metal interface in osteointegration, *Journal of prosthetic dentistry*. 1987; 57(5):597-607.
2. Telleman G, Raghoobar GM, Vissink A, Meijer HJ. Impact of platform switching on peri-implant bone remodeling around short implants in the posterior region, 1-year results from a split-mouth clinical trial, *Clinical implant dentistry and related research*. 2014; 16(1):70-80.
3. Thoma DS, Haas R, Tutak M *et al*. Randomized controlled multicenter study comparing short dental implants (6mm) versus longer dental implants (11–15 mm) in combination with sinus floor elevation procedures, Part 1: demographics and patient-reported outcomes at 1 year of loading, *Journal of clinical periodontology*. 2015; 42(1):72-80.
4. Chiapasco M, Zaniboni M, Boisco M. Augmentation procedures for the rehabilitation of deficient edentulous ridges with oral implants, *Clinical oral implants research*. 2006; 17(S2):136-59.
5. Pjetursson BE, Brägger U, Lang NP, Zwahlen M. Comparison of survival and complication rates of tooth-supported fixed dental prostheses (FDPs) and implant-supported FDPs and single crowns (SCs), *Clinical oral implants research*. 2007; 18:97-113.

6. Sadowsky SJ, Bedrossian E. Evidenced-based criteria for differential treatment planning of implant restorations for the partially edentulous patient, *Journal of Prosthodontics*. 2013; 22(4):319-29.
7. Sailer I, Mühlemann S, Zwahlen M, Hämmerle CH, Schneider D. Cemented and screw-retained implant reconstructions: a systematic review of the survival and complication rates, *Clinical oral implants research*. 2012; 23:163-201.
8. Esquivel-Upshaw JF, Clark AE, Shuster JJ, Anusavice KJ. Randomized Clinical Trial of Implant-Supported Ceramic – Ceramic and Metal – Ceramic Fixed Dental Prostheses: preliminary results, *Journal of prosthodontics*. 2014; 23(2):73-82.
9. Nissan J, Narobai D, Gross O, Ghelfan O, Chaushu G. Long-term outcome of cemented versus screw-retained implant-supported partial restorations, *International Journal of oral and maxillofacial implants*. 2011; 26(5):11.
10. Kreissl ME, Gerds T, Muche R, Heydecke G, Strub JR. Technical complications of implant-supported fixed partial dentures in partially edentulous cases after an average observation period of 5 years, *Clinical oral implants research*. 2007; 18(6):720-26.
11. Lee JH, Lee JB, Park JI, Choi SH, Kim YT. Mechanical complication rates and optimal horizontal distance of the most distally positioned implant-supported single crowns in the posterior region: A study with a mean follow-up of 3 years, *Journal of Prosthodontics*. 2015; 24(7):517-24.
12. Tey VH, Phillips R, Tan K. Five-year retrospective study on success, survival and incidence of complications of single crowns supported by dental implants, *Clinical oral implants research*. 2017; 28(5):620-25.
13. Larsson C, Wennerberg A. The clinical success of zirconia-based crowns: a systematic review, *International Journal of Prosthodontics*. 2014; 27:1.
14. Karayazgan-Saracoglu B, Atay A, Korkmaz C, Gunay Y. Quality of life assessment of implant-retained overdentures and fixed metal-acrylic resin prostheses in patients with marginal mandibulectomy, *The Journal of prosthetic dentistry*. 2017; 118(4):551-60.
15. Albrektsson T, Jansson T, Lekholm U. Osseointegrated dental implants, *Dental clinics of North America*. 1986; 30(1):15-17.
16. Lai HC, Si MS, Zhuang LF *et al*. Long-term outcomes of short dental implants supporting single crowns in posterior region: a clinical retrospective study of 5–10 years, *clinical oral implants research*. 2013; 24(2):230-37.
17. Telleman G, Raghoobar GM, Vissink A *et al*. A systematic review of the prognosis of short (< 10 mm) dental implants placed in the partially edentulous patient, *Journal of clinical periodontology*. 2011; 38(7):667-76.
18. Renouard F, Nisand D. Impact of implant length and diameter on survival rates, *Clinical oral implants research*. 2006; 17(S2):35-51.
19. Jung E R, Zembic A, Pjetursson BE, Zwahlen M, Thoma SD. Systematic review of the survival rate and the incidence of biological, technical, and aesthetic complications of single crowns on implants reported in longitudinal studies with a mean follow-up of 5 years, *Clinical oral implants research*. 2012; 23:2-21.
20. Oyagiü RC, Turrión AS, Toledano M, Monticelli F, Osorio R. In vitro vertical misfit evaluation of cast frameworks for cement-retained implant-supported partial prostheses, *Journal of dentistry*. 2009; 37(1):52-58.
21. Beuer F, Sachs C, Groesser J, Gueth J-F, Stimmelmayer M. Tooth-implant-supported posterior fixed dental prostheses with zirconia frameworks: 3-year clinical result, *Clinical oral investigations*. 2016; 20(5):1079-86.
22. Jung RE, Fenner N, Hämmerle CH, Zitzmann NU. Long-term outcome of implants placed with guided bone regeneration (GBR) using resorbable and non-resorbable membranes after 12–14 years, *Clinical oral implants research*. 2013; 24(10):1065-73.