



ISSN Print: 2394-7489
ISSN Online: 2394-7497
IJADS 2020; 6(3): 578-587
© 2020 IJADS
www.oraljournal.com
Received: 18-06-2020
Accepted: 22-07-2020

Dr. Nikhil N Pawar
Ex Post Graduate Student,
Department of Prosthodontics
and Implantologist, Darshan
Dental College, Udaipur,
Rajasthan, India

Dr. Payal A Karkar
Ex Student, Krishna Institute of
Medical Sciences Karad,
Maharashtra, India

Corresponding Author:
Dr. Nikhil N Pawar
Ex Post Graduate Student,
Department of Prosthodontics
and Implantologist, Darshan
Dental College, Udaipur,
Rajasthan, India

Loading protocol in implant dentistry: A review

Dr. Nikhil N Pawar and Dr. Payal A Karkar

DOI: <https://doi.org/10.22271/oral.2020.v6.i3i.1011>

Abstract

When using modern dental implants, conventional and early loading protocols are both well-documented and predictable. Interdisciplinary teams may choose a longer healing period in sites that are compromised or in patients in which healing is expected to be altered. Immediate loading in partially edentulous patients is possible in select cases, but the evidence for successful outcomes is less extensive. Many patients are eager to have their treatment completed as rapidly as possible. Individual dentists and interdisciplinary teams are reminded that immediate loading has increased risk of implant failure and should be used in esthetically critical areas only after careful consideration of the benefits, risks and alternatives. Present review article discussed about loading protocols in implant dentistry.

Keywords: Dental implants, Conventional loading protocols, Early loading protocols

Introduction

Prosthetic rehabilitation of missing structures in the oral and maxillofacial region in accordance with DeVan's principle of preservation has been the ultimate challenge to the prosthodontist. Over the years, traditional methods of tooth replacement are slowly and steadily being replaced by newer modalities like implants. High success rates of implants and the advantages that go with them have earned them the name of the "third dentition". Implants have come a long way from cast cobalt chromium tubes, pins, subperiosteal vitallium implants, endosseous blade implants, ceramic implants to the modern day root form implants made of titanium and its alloys.

Dental implants were commonly loaded at placement because immediate bone stimulation was considered to avoid crestal bone loss (Linkow & Chercheve 1970). Fibrous tissue interposition was considered the optimal response to implants as it was mimicking the natural periodontal ligament. In contrast to all other experimental studies of that time, Branemark *et al.* (1969) showed that direct bone apposition at the implant surface was possible and lasting under loading at the condition that implants were left to heal in a submerged way.

Terminologies

Conventional Loading: Conventional loading is defined as the prosthetic restoration and functional loading of an osseointegrated implant after a healing period of three to six months. As mentioned, this protocol was originally defined for implants with machined surfaces. Often, but not always, implants following the conventional loading protocol are placed and then the surgical site closed requiring a second-stage surgery to "uncover" the implant. This is sometimes described as delayed loading.

Immediate Loading

At the other end of the spectrum is immediate implant loading. Immediate loading is defined as restoring the implant in occlusal contact within 48 hours of implant placement. Taken to its extreme, the immediately loaded implant could be placed and definitively restored, all within 48 hours. Immediate loading has shortened the transitional period between implant placement and implant restoration considerably. Benefits for the patient include reduced overall treatment time, reduced number of visits to clinicians, comfort during the healing period and improved esthetic and phonetic aspects.

Immediate Restoration

Immediate restoration or immediate provisionalization is similar to immediate loading. The implant is restored within 48 hours but in this case the restoration is left out of any functional occlusion. It is important to clarify that immediate loading and immediate restoration are independent of immediate implant placement. Although often described together and certainly related, implant placement protocols and implant loading protocols should be considered independently when treatment planning partially and full edentulous patients.

Early Loading

Early loading falls temporally between conventional loading and immediate loading. Early loading is defined as the prosthetic loading or utilization of an implant at any time between immediate and conventional loading.

Discussion

Pre-load and after-load

The preloading or stretching the screw places the components under enough tension to create elongation of the material within its elastic limit. Preloading may reduce screw loosening. As a result the components stretch and maintain fixation in spite of vibration and external forces. The elongation of metal is related to the modulus of elasticity, which is dependent on the type of material, its width, design, and the amount of stress applied per area. Thus a gold screw exhibits greater elongation but lower yield strength than a screw made of titanium alloy.

A prosthesis screw may exhibit a torsional ductile fracture at 16.5 N-cm Vs 40 N-cm for an abutment screw of different material and size. The material the screw is made from (eg. Titanium alloy or gold) has a specific modulus of elasticity. The plastic deformation or permanent distortion of the screw is the end point of the elasticity modulus. When the screw is stretched with a force 75% of its elastic length, it is able to better resist vibration and screw loosening. In order to stretch the screw, a torque wrench is necessary, although not completely accurate. Even an experienced clinician is unable to determine the amount of correct torque on the screw by tactile sense only.

Bone physiology and loading

As a result of unique physiological mechanisms, bone serves two antagonistic functions: structural support and calcium metabolism. The strength of a bone (quantity, quality and distribution of osseous tissue) is directly related to loading. As an energy conservation measure, bone that is not adequately loaded is resorbed, and the skeletal system continuously adapts to achieve optimal strength with minimal mass. The delicate structural balance is further challenged by metabolic function. An adequate reserve of osseous tissue must be maintained to provide a continuous stream of ionic calcium without compromising structural integrity.

Osteopenia (inadequate bone mass) is a common clinical problem. It may be due to functional atrophy and/or negative calcium balance. Prospective oral implant patients are likely to present with localized and systemic skeletal problems for three reasons:

1. Bone in edentulous areas is usually atrophic
2. Metabolic bone disease is prevalent in middle-aged and older adults
3. Integrated implants are often indicated for patients with a history of severe bone loss

The clinical success and longevity of endosteal dental implants as load-bearing abutments are controlled largely by the mechanical setting in which they function. The treatment plan is responsible for the design, number, and position of the implant. After achievement of rigid fixation with proper crestal bone contour and gingival health, the mechanical stress or strain beyond the physical limits of hard tissues has been suggested as the primary cause of initial and long-term bone loss around implants. Occlusal overload and its relationship to implant overload and failure is a well-accepted phenomenon. Occlusal overload as a factor related to crestal bone loss has been well established by Misch and others.

Modeling and remodeling

Unique mechanisms of bone adaptation have evolved to maintain structural integrity, repair fatigue damage, and provide a continuous source of metabolic calcium. Modeling involves individual uncoupled sites of bone formation or resorption that change the shape or form of a bone. This is the principal mechanism for adapting osseous structure to functional loading. Remodeling is the mechanism of bone turnover. It involves coupled sequences of cell activation (A), bone resorption (R) and bone formation (F). The duration of the ARF remodeling cycle (σ) is about 4 months in humans.

Cortical bone remodeling (internal turnover) is accomplished by paravascular cutting/filling cones, a functional unit of the osteoclasts and osteoblasts organized around a proliferating, dedicated blood vessel. Trabecular bone (spongiosa) remodels in a similar manner, by means of "hemi-cutting/filling cones" that selectively remove and replace a set volume of bone at specific foci. The main difference in trabecular remodeling is the lack of an internal, dedicated blood supply. The hemi-cutting/filling cone depends on the vascularity of the marrow. Trabecular bone remodels at a rate of 20-30% per year. From a metabolic perspective, spongiosa is the most important calcium reserve in the body. The remodeling rate for cortical bone is usually 3-10 times less than for adjacent trabecular bone (metabolic fraction). At a few localized sites, such as the alveolar process, the temporomandibular joint, and the interface of osseointegrated implants cortical bone turnover is $\geq 30\%$ per year. This elevated remodeling rate is probably related to the high stress and subsequent fatigue damage caused by masticatory function. Thus, the most critical bone in the dental apparatus is highly labile and susceptible to mechanical overload.

In all these studies, the original two-stage surgical protocol using a two-piece implant pillar was applied. The main reasons for this approach have been to

1. Minimize the risk of infection
2. Prevent apical down growth of mucosal epithelium, and
3. Minimize the risk of undue early loading during the initial healing period.

In addition, a stress-free healing period of 3 to 6 months before the mucosa-piercing abutments are placed and the supra-structure is connected to the implants was emphasized to predict a successful treatment outcome. Such a stress-free period was even considered to be an ultimate prerequisite to achieve proper osseointegration. In other words, early stress on the implants was thought to jeopardize the osseointegration process.

Evidence of early crestal bone loss

- Animal studies
- Clinical reports
- Cantilever length
- Progressive loading
- Biomechanical evaluation
- Photoelastic
- Three-dimensional finite element analysis
- Bone physiology and research
- Woven versus lamellar bone
- Compression and tension versus shear loads

Bone loss may lead to anaerobic sulcus depths and periimplant disease states. This occlusal concept refers to an occlusal plane specifically designed for the restoration of endosteal implants, providing an environment for improved clinical longevity of implant and prosthesis. The biomechanical risk factors may be expressed at different levels in the system. The biomechanical rationale for this concept was published after long-term clinical evaluation.

Early functional loading

Randow *et al.* believed it to be of interest to compare the rehabilitation of edentulous mandibles by fixed supraconstructions connected to implants placed according to either an early-loaded one stage surgical procedure or the original two-stage concept, with the working hypothesis that there are no differences between the two methods concerning the treatment outcome. The authors concluded that it is "possible to successfully load titanium dental implants immediately following installation via a permanent fixed rigid cross-arch supraconstruction. However, such a treatment approach has so far to be strictly limited to the inter-foramina area of the edentulous mandible. Furthermore, none of the implants failed during the observation interval, and the stability of the implants increased with time.

Schnitman and coworkers reported on 63 Branemark implants placed in 10 patients. Of these 63 implants, 28 were placed and "immediately loaded to support an interim fixed bridge." The remaining 35 implants were placed according to the 'original two-stage protocol, osseointegrated properly, and are still in function. Of the 28 implants immediately loaded, four failed. In other words, the survival rate for the immediately loaded implants was found to be about 85%.

When applying the one-stage surgical protocol in combination with early functional loading, it is possible to use either the common implant pillar, ie, the two-piece implant pillar, or the conical one. This latter implant is designed with a 3.5-mm conical part coronal to the threads. In other words, when the implant threads are anchored into the bone, the conical part will be mucosa piercing; the implant serves as an one-piece implant pillar. The total treatment time from implant placement to delivery of the permanent fixed partial denture (FPD), using the Procera AII-in-One framework (Nobel Biocare), amounts to 5 to 7 days.

Consequences of biomechanical overload:

- Early implant failure
- Early crestal bone loss
- Intermediate to late implant failure
- Intermediate to late implant bone loss
- Screw loosening (abutment and prosthesis coping)
- Uncemented restoration
- Component fracture
- Porcelain fracture

- Prosthesis fracture
- Periimplant disease (from bone loss)

Evolution of the concept of implant loading

The surgical and prosthetic protocols for the development of a predictable direct bone-to-implant interface with root-form implants were developed and reported by Branemark *et al.*

About 25 years ago, Branemark *et al.* (1977) published the first long-term follow-up on oral implant, providing the scientific foundation of modern dental implantology. The predictability of implant integration according to Branemark and collaborators was obtained by adherence to a strict surgical and prosthodontic protocol. One of the most emphasized requirements was a stress-free healing period of 3-6 months, making implant treatment lengthy. Presently however, early and immediate loading protocols are reported by an enhancing number of clinical (Chiapasco *et al.* 1997, Schnitman *et al.* 1997, Tarnow *et al.* 1997) and experimental publications.

Early loading was identified as a detrimental factor for osseointegration' by Branemark *et al.* During 'the course of their clinical trial (Branemark *et al.* 1977), various delayed loading periods were tried. Consequent to their 10-year clinical experience, they asserted that osseointegration required a long healing period' of at least 3 months in the mandible and at least 5-6 months in the maxilla.

The rationale for such a long delayed loading period was that-

1. Premature loading may lead to fibrous tissue encapsulation instead of direct bone apposition.
2. The necrotic bone at the implant bed border is not capable of load-bearing and must be first replaced by new bone.
3. Rapid remodeling of the dead bone layer compromises the strength of the osseous tissue supporting the bone-implant interface.
4. Integrity of the periosteal margin may be threatened by undermining remodeling of adjacent bone during the late healing period

Once an initial direct bone-to-implant interface has been obtained and confirmed at the posthealing Stage II surgery, the implant is most at risk for failure or crestal bone loss within the first year. Failure results primarily from excessive stress or poor bone strength at the interface during early implant loading. If the treatment plan provides adequate support, the three most common causes of early prosthetic-related implant failure are non-passive superstructures, partially nonretentive restorations, and loading of the implant support system beyond the strength of the bone-to-implant interface.

Protocols of implant loading

1. **Branemark's loading protocol:** Flush with bone level, covered with gingiva. Final prosthesis after 3 to 6 months of initial healing. Soft/ hard diet
2. **Progressive loading:** Flush with bone level, covered with gingiva. Provisional prosthesis brought progressively into occlusion, depending upon bone density. Soft/ hard diet
3. **Non submerged single stage protocol:** Non-submerged implants, flush within 1-2 mm of gingival level. Soft diet
4. **Immediate functional loading:** Temporary restoration fitted on the same day as surgery, in occlusion. Soft diet
5. **Immediate non-functional loading:** Temporary restoration fitted on the same day as surgery, not in

occlusion. Soft diet

6. **Early loading:** Final crowns within 3 weeks from surgery, in occlusion. Soft/ hard diet
7. **Delayed loading:** Implant subjected to loading after more than 6 weeks post surgery. Soft/ hard diet
8. **Anticipated loading:** Provisional prosthesis is fitted after about 2 months after surgery. Soft/ hard diet

Elements of implant loading

Time: The two surgical appointments used for initial implant placement and Stage II uncover are separated by 3 to 8 months depending on the bone density at the initial surgery. In a study by Carr, the increase in bone implant contact occurred in the maxilla and mandible and ranged from a 7% to 9% increase over a 3-months period. Each of the major prosthodontic appointments also is separated by a period to time related to the bone density observed at the initial time of surgery. In addition, the dentist attempts to gradually increase the load to the implant at each prosthetic step.

The macroscopic coarse trabecular bone heals about 50% faster than dense cortical bone. Although it heals more slowly, D1 bone has the greatest strength and greater lamellar bone contact. The healing time between the initial and second-stage surgeries is kept similar for D1 and D2 bone and is 3 to 4 months. A longer time is suggested for the initial healing phase of D3 and D4 bone (5 and 6 months, respectively) because of the lesser bone contact and decreased amount of cortical bone to allow for the maturation of the interface and the development of some lamellar bone. The D4 implant-to-bone interface typically found in posterior regions of the maxilla exhibits minimum initial bone contact, with little to no cortical bone at the crest or apex. An implant surgery initially may trigger and increase in the amount of bone in the region.

Diet: During the initial healing phase, the dentist instructs the patient to avoid chewing in the area. Once uncovered, the implant connected to a high abutment is at greater risk of loading during mastication. The patient is limited a soft diet such as pasta and fish, from the initial transitional prosthesis delivery until the initial delivery of the final prosthesis. The masticatory force for this type of food is about 10 psi. This diet not only minimizes the masticatory force on the implants but also decreases the risk of temporary restoration fracture or partially decemented restoration. After the initial delivery of the final prosthesis, the patient may include meat in the diet, which requires, about 21 psi in bite force. The final restoration can bear the greater force without risk or fracture or decementation. After the final evaluation appointment, the patient may include raw vegetables, which require an average 27 psi of force. A normal diet is permitted only evaluation of the final prosthesis function, occlusion, and proper cementation.

Occlusal material: The occlusal material may be varied to load the bone-to-implant interface gradually. During the initial steps, the implant has no occlusal material over it. At subsequent appointments, the dentist uses acrylic as the occlusal material, with the benefit of a lower implant force than metal or porcelain either metal or porcelain can be used as the final occlusal. Either metal or porcelain can be used as the final occlusal material. If para function or cantilever length cause concern relative to the amount of force on the early implant-bone interface, the dentist may extend the softer diet and acrylic restoration phase several months. In

this way, the bone has a longer time to mineralize and organize to accommodate the higher forces.

Occlusion: The dentist gradually intensifies the occlusal contacts during prosthesis fabrication. No occlusal contacts are permitted during initial healing. The first transitional prosthesis is left out of occlusion in partially edentulous patients. The occlusal contacts then are similar to those of the final restoration for areas supported by implants. However, no occlusal contact are made on cantilevers. The occlusal contacts of the final restoration follow the implant-protective occlusion concepts.

Prosthesis design: During the surgical stage II uncover procedure, the surgeon evaluates clinical mobility, bone loss (horizontal and vertical), proper placement in reference to prosthetic design and angulation to load, zones of attached gingiva, and gingival thickness. The dentist instructs the patient with a posterior implant in a partially edentulous arch not to wear any removable restoration. If anterior teeth are part of the removable prosthesis, a 7 mm diameter hole is placed completely through the partial denture framework around each perimucosal extension. In completely edentulous patients, the tissue surface of the denture is relieved at least 5 mm over and around the implants and replaced by a tissue conditioner. The conditioner also is relieved a few millimeters. The patient returns in 2 weeks for suture removal.

The principles of gradual loading are demonstrated best in the cement-retained prosthesis and are least applicable for the screw-retained bar of a mandibular removable prosthesis type 5 (RP-5) restoration. In addition, gradually loading a removable RP-4 or RP-5 prosthesis with a screw-retained superstructure bar is difficult because the transitional prosthesis often remains removable during the prosthesis fabrication. The procedures for a partially edentulous Kennedy Class I or II patient are presented. The progressive bone-loading appointment sequence for cement-retained prosthesis is as follows:

1. Initial abutment selection and preliminary impression
2. Final impression and transitional prosthesis I
3. Metal superstructure try-in and transitional prosthesis II
4. Initial insertion of final prosthesis
5. Final delivery and evaluation.

Progressive loading protocol

Fixed single tooth restorations

First appointment

Initial abutment selection and preliminary impressions-Goal

- a. To assess implant & soft tissues,
- b. Make sure that all prosthetic components & details of next long prosthetic appointment are addressed beforehand.

This appointment may occur during suture removal appointment after Stage II surgery or during uncover procedure.

Final Impression and Transitional Prosthesis I

Dentist removes the PMEs from implant bodies & selects the appropriate or two-piece abutment for cement retention. Dentist threads the abutment for cement retention into position. Obtain a final impression, records centric occlusal registration or makes a face-bow record along with protrusive

and check bites when required. Then first transitional prosthesis is luted with a non-eugenol ZnO cement. Occlusal contacts are totally absent. Dentist instructs the patient to avoid this region of mouth while eating. Diet should consist of soft food. Patient shouldn't chew sticky foods or gum & should avoid aggressive chewing or oral habits that may cause temporary prosthesis to loosen or break.

Laboratory Phase I

Lab. technician pours final impressions, mounts the models & makes a full-contour wax-up and cutdown of 2 mm in regions of porcelain for prosthesis framework.

Second Prosthetic appointment

Metal try-in

Patient returns in 1-4 weeks (or more) depending on bone density. 1st transitional restoration is removed & its retention evaluated to help select proper luting agent for final restoration. Dentist evaluates and corrects the occlusion on casting as indicated and records a closed-mouth centric occlusal registration using a rigid addition silicone material on top of the casting.

Third Prosthetic Appointment

Initial Prosthesis Delivery

Next appointment follows 1 to 4 weeks later, depending on bone density. If crestal bone loss is observed when compared with the stage II uncovering appointment, the dentist should suspect parafunction and fabricate night guards to control stresses

Fourth Prosthetic Appointment

Final Evaluation & Hygiene

Patient returns in about 4 weeks. Dentist evaluates retention of prosthesis, the soft tissues & home care and performs a final occlusal equilibration. Patient's diet may now include raw vegetables & harder foods. Patient is scheduled for another maintenance appointment in 3-4 months.

Completely edentulous patient protocol

A full-arch restoration often uses an indirect (laboratory) approach to select or prepare (or fabricate) the abutments. Because no natural teeth are present, the implants are loaded when the initial transitional prosthesis is delivered.

First Prosthetic Appointment

Initial Abutment Selection and Preliminary Impression

Before or during surgical phases, dentist may fabricate treatment prosthesis that restores the patient to proper occlusal vertical dimension (OVD) & determines the correct tooth position for final prosthesis. A closed-tray impression is made with the customized impression tray over these implant body transfers. Then, dentist removes the abutments for cement, attaches them to implant body analogs & seats them into impression. Then stage II PMEs are re-inserted into implant bodies & relieves the soft liner over the PMEs. Patient is instructed to limit mastication to very soft foods & to remove the denture at night to prevent nocturnal parafunction.

Lab. Phase I

The impression transfer copings are attached to the implant bodies, poured, and mounted to the opposing arch with the customized impression tray. Customized impression tray is removed from the working cast. The final abutments are selected and prepared for parallelism and tooth position. A

transitional restoration is made over the prepared implant abutments.

Second prosthetic Appointment

Final Impression & Transitional Prosthesis

Final impression & occlusal registration is made when the transitional prosthesis has the correct incisal edge, vertical dimension & necessary prosthetic guidelines.

Lab phase II

Mount master cast on articulator using a face-bow & centric registration, remove it & then mount the cast of provisional restoration with separate bite registration recording or insert modified baseplate & wax rim on master cast. Make an index of incisal edge & facial tooth position of temporary, or wax rim, in proper position & replace the master cast on articulator. Then make a wax-up of final restoration & then cuts back 2 mm for porcelain thickness in appropriate regions. Then fabricate the metal framework.

Third Appointment

Metal Try-in & Transitional prosthesis II

At metal try-in appointment, the framework of prosthesis is evaluated. White wax is used to evaluate the incisal edge position. Acrylic posterior indexes are used to evaluate the occlusal vertical dimension and centric occlusal registration. Then dentist confirms the final crown contour & shade selection for gingiva & teeth. Temporary restoration is cemented with a soft access cement

Fourth Appointment

Initial Delivery

2-4 weeks later. The final restoration is delivered to the patient.

Fifth prosthetic appointment

Final evaluation & Hygiene

Four weeks later. Dentist evaluates final restorative result & improves difficult access areas for hygiene. Occlusion is refined. Use of an acrylic night guard for bruxism or a soft occlusal appliance for clenching is usually prescribed for a full-arch prosthesis. Patient is asked to return every 3-4 months so that the dentist may evaluate bone changes & occlusal patterns.

Immediate occlusal loading

Not every patient or every tooth site is indicated for the teeth in a day approach. Patients must understand the limitations of such treatment and be willing to accept the scientifically based precautionary measures. In order to limit functional forces during osseointegration, patients need to abstain from chewing anything but soft food or otherwise applying force to restoration for approximately 3 months.

Indications

Functional loading can be employed for:

- Single tooth replacement
- Partial edentulism
- Full edentulism.

Contra-indications

- Patients who are bruxers.
- Edentulous patients with a reduced bone quality and quantity.
- With not optimized biomechanically suprastructures.

- d. With short implant lengths.

Advantages

- Immediate full function of the new tooth.
- It gives beautiful, natural cosmetic appearance.
- Very little discomfort is associated with the procedure. In fact some people have reported almost no pain at all.
- Less invasive than some older procedures for crown & bridge placement, where perfectly good neighboring teeth have to be ground down to accommodate the crown.
- Long term edentulism can be eliminated.
- No additional appointments are required.

Disadvantages

- More chances of failure.
- Peri-implant bone reaction is highest after surgical trauma due to immediate loading.
- High chances of post-operative complications.
- More patient co-operation is needed.
- More bone loss compared to delayed loading.

Immediate loading of dental implant not only includes a non-submerged, one-stage surgery but also actually loads the implant with provisional restoration at the same appointment or shortly thereafter. Immediate loading was the initial protocol suggested with dental implants. These implants yielded a wide range of clinical survival. On occasion, a direct bone interface could be developed and maintained for more than 20 years.

Completely Edentulous Patients

Early studies in immediate loading, with a primary goal of a direct bone implant contact, have been proposed and have shown encouraging results. In general, two different protocols have emerged:

First Protocol

Involves placing more implants than the usual treatment plan for a conventional healing period. Selected implants around the arch (three or more) then are loaded immediately with a transitional prosthesis. Enough implants are left submerged for regular healing period to allow delivery of fixed prosthesis, even if all immediately loaded implants fail. If any of the implants survive, they also are used in the final restoration.

Second Protocol

Other protocol for immediate occlusal loading is to initially load all of the implants inserted. Implants are splinted together, which -

- Decreases stresses on all developing interfaces &
- Increases stability, retention & strength of transitional prosthesis during initial healing phase.

Often additional implants also are used with this technique compared with the traditional healing method. Immediate load concept provides all the advantages of the one-stage surgical approach.

Rationale for Implant Immediate Loading

Surgical Trauma

Immediate implant-loading concept challenges the

conventional healing time of 3-6 months of no loading before the restoration of implant. Often the risks of this procedure are perceived to be during the first week after implant insertion surgery. In reality, bone interface is stronger on the day of implant placement compared with 3 months later. Surgical process of implant osteotomy preparation & implant insertion cause a regional accelerator phenomenon of bone repair around the implant interface. As a result of the surgical placement, organized, mineralized lamellar bone in preparation site becomes unorganized, less-mineralized, woven bone of repair next to implant. A protocol for immediate load is to tighten the implant within the bone to 45-60 N-cm.

This concept ensures that the implant has rigid fixation & is in good quality bone, but additional torque used to secure or evaluate fixation of an implant in bone actually may increase the strain at interface & increase the amount of remodeling, which decreases the strength of bone-implant interface. Therefore it is prudent to minimize factors related to thermal injury & surgical trauma when considering immediate load to the implant interface.

Cortical and trabecular bone remodeling, or bone turnover, permits the repair of bone after trauma or allows the bone to respond to its local mechanical environment. The bone most often is lamellar but may become woven bone during the repair or modeling process. Lamellar bone and woven bone are the primary bone tissue types found around a dental implant. Lamellar bone is organized, highly mineralized, is the strongest bone type, has the highest modulus of elasticity, and is called load-bearing bone. By comparison, woven bone is unorganized, less mineralized, weaker & more flexible. Woven bone may form at a rate of 60 μm per day, whereas lamellar bone forms at a rate of 1-5 μm per day.

Classic 2-stage surgical approach to implant dentistry permitted the surgical repair of implant to be separated from early loading response by 3-6 months. Majority of woven bone that formed to repair the initial surgical trauma was replaced with lamellar bone which is stronger & able to respond to mechanical environment of occlusal loading. Therefore a rationale for immediate loading is not only to reduce the risk of fibrous tissue formation but also to minimize woven bone formation & promote lamellar bone maturation to sustain occlusal load. Woven bone of surgical trauma has been called Repair Bone, and the woven bone formed from the mechanical response may be called Reactive Woven Bone.

Remodeling also is called Bone Turnover and not only repairs damaged bone but also allows the implant interface to adapt to its biomechanical situation. Once the bone is loaded by the implant prosthesis, i.e., interface begins to remodel again. However, this time the trigger for this process is strain, rather than the trauma of implant placement. When the surgical trauma is too great or the mechanical situation is too severe, fibrous tissue may form rather than bone. Fibrous tissue at an implant interface may result with clinical mobility rather than rigid fixation.

Factors that decrease risk in immediate loading

A) Bone microstrain

Loaded bone changes its shape. This change may be measured as strain. Frost has developed a microstrain language for bone based on its biological response at microstrain levels.

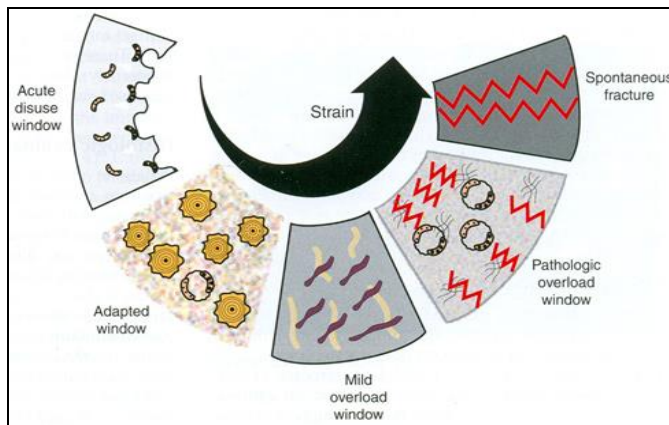


Fig 1: Bone microstrain

Frost has reported on 4 distinct microstrain pattern within the bone

Acute disuse window – results in atrophy.

Adapted window – is the physiologic response of organized bone. At these levels of strain, the bone is allowed to remodel & remain an organized, mineralized lamellar bone. This is called the ideal load-bearing zone for implant interface.

Mild overload window – corresponds to fatigue fracture with reactive woven bone formation & corresponds to an intermediate level of microstrain between the ideal load-bearing zone & pathologic overload.

Pathologic overload window – causes bone resorption. Bone fractures at 10000-20000 microstrain units. At levels of 20-40% of this value, bone already starts to disappear or form fibrous tissue & is called the pathologic overload zone

One goal for an immediately loaded implant-prosthesis system is to decrease the risk of occlusal overload & its resultant increase in the remodeling rate of bone. One method to decrease microstrain & remodeling rate in bone is to provide conditions that increase functional surface area to the implant-bone interface.

B) Increased Surface Area

The surface area of load may be increased in a number of ways:

1. Implant Number: Functional surface area can be increased by increasing implant number. Increased number of implants also increases the retention of restoration & reduces the number of pontics. Increased retention minimizes the occurrence of partially unretained restorations during healing, which can overload the implants still supporting the restoration. Decrease in pontics may decrease the risk of fracture of transitional prosthesis, which also may be a source of overload to remaining implants supporting the prosthesis. More implants typically are used in the maxilla (8 to 12) compared with the mandible (5 to 9).

2. Implant Size: Surface area of implant support can be increased by the size of implant. Length of implant in most systems increases in increments of 2-4 mm. Each 3-mm increase in length can improve surface area support by more than 20%. Benefit of increased length is not found at crestal bone interface but rather in initial stability of bone-implant interface. Most of the stresses to an implant bone interface are concentrated at crestal bone, so increased implant length does little to decrease the stress that occurs at trans-osteal region around the implant. Therefore the length is not an effective method to decrease stress because it does not address the

problem in the functional surface area region of implant interface. Functional surface area of each implant support system is related primarily to the width & design of implant. Wider root form implant provide greater area of bone contact than narrow implants. Crest of the ridge is where the occlusal stresses are greatest. As a result, width is more important than length of implant. Bone augmentation in width may be indicated to increase implant diameter when forces are greater, as in cases of moderate to severe parafunction.

3. Implant body design: Implant body design should be more specific for immediate loading because the bone does not grow into recesses or undercuts in the design or attach to a surface condition before the application of occlusal load. For example, a press-fit implant with a cylinder design does not have bone integration the day of implant placement is thus least indicated for immediate loading. For a threaded implant, bone is present in depth of the threads from the day of insertion. Therefore the functional surface area is greater during the immediate-load format.

4. Implant Surface Conditions: Implant surface conditions may affect

- Rate of bone contact,
- Lamellar bone formation,
- Percentage of bone contact.

Surface condition that allows bone formation in greatest percentage, higher BIC with higher mineralization rate, and fastest lamellar bone formation would be of benefit in immediate loading.

C) Decreased Force Conditions

Forces can be evaluated by magnitude, duration, direction, and type. The dentist should reduce conditions that magnify the noxious effects of these forces.

1. Patient Factors

Parafunctions like bruxism & clenching represents significant force factors because -

- Magnitude of force is increased,
- Duration of the force is increased,
- Direction of the force is more horizontal than axial to implants with a greater shear component.

Parafunctional loads also increase the risk of

- Abutment screw loosening,
- Unretained prostheses,
- Fracture of transitional restoration used for immediate loading.

If any of these complications occur, then the remaining implants that are loaded are more likely to fail.

2. Occlusal Load Direction

Occlusal load direction may affect the remodeling rate. An axial load to an implant body maintains more lamellar bone and has a lower remodeling rate compared with an implant with an offset load.

3. Implant Position

Most important factor. A crossarch splint → very effective design (reduce stress within the entire implant support system). Hence, it appears to be advantageous for the immediate load transitional prosthesis. Mandible may be

divided into three sections around the arch: the canine to canine area and the bilateral posterior sections. Concerns have been raised regarding cross-arch splinting in mandible because of mandibular flexure and possibility of torsion distal to mental foramina. Acrylic being used in transitional prosthesis & length of the span being flexible is enough to minimize these concerns when 3 or more pontics exist between posterior & anterior implants. Final restoration should be fabricated in at least two independent sections when implants are placed in both posterior quadrants & fewer than 3 adjacent pontics exist. Maxilla requires more implant support than the mandible, because -

- a. Bone is less dense and
- b. Direction of force is outside of arch in all excursive movements.
- c. Maxilla is usually divided into 5 sections, depending on the intensity of force conditions & the shape of the arch.

Minimum 5 sections include

- a. Incisor region,
- b. Bilateral canine areas and
- c. Bilateral posterior regions.

At least 1 implant should be inserted into each maxillary section & splinted together during immediate-loading.

D) Mechanical Properties of Bone

Modulus of elasticity of bone is related to bone quality. The less dense the bone, the lower the modulus. Amount of bone-implant contact is also decreased for less dense bone. Strength of bone is also directly related to density of bone. Remodeling rate of cortical bone is slower than that of trabecular bone. So, cortical bone is more likely to remain lamellar in structure during immediate-loading process when compared with trabecular bone. Bone in anterior regions of jaw may be cortical bone at crestal & apical region of root form implant, whenever the implant is long enough to engage both cortices. Anterior root form implants should attempt to engage the opposing cortical plate when immediate load is contemplated.

Immediate loading procedures for fixed prostheses

Two different options are available for immediate occlusal loading for completely edentulous patient desiring a fixed prosthesis

- a. First option- loads the implants the same day as the surgery.
- b. Second option- is to place implants & make an impression at surgery. Then at the suture removal appointment 7 to 12 days later, the dentist delivers the transitional fixed prosthesis.

Option 1

Before surgical appointment the dentist fabricates a surgical template for implant insertion. For delivery of restoration at the day of surgery, two different approaches are-

1. Fabricate a denture on edentulous arch using impressions, baseplate & wax rims and denture teeth try-in procedures similar to fabrication of a new denture.
2. Modify the patient's existing denture.

In either case, in the region of future implants, the dentist hollows the restoration to create a shell. No posterior cantilevers are fabricated for transitional restoration when they are out of esthetic zones during smiling or speech. The

dentist inserts the implants into the pre-established positions. Implants in good-quality bone, with no crestal bone grafts at insertion, are included in the transitional restoration. The more implants loaded at this appointment, the less risk of complications. Implants are placed in at least 3 ideal implant positions in mandible (bilateral premolars & central) and 4 ideal implant positions in maxilla (bilateral molars, bilateral canines) into function. The more additional implants are inserted, the less the risk of overload failure, early crestal bone loss, unretained restoration, restoration fracture, and abutment screw loosening.

Once the implants are inserted, the dentist positions the final abutment and tightens it to a torque of 30 N-cm or more. Abutment screw loosening of any individual implant may increase the risk of other implants in the prosthetic-implant system. Then final abutments are prepared intraorally for parallelism and proper height requirements. Transitional prosthesis is relined with light-cured composite to eliminate toxic monomer contact with the bone. This material also exhibits less dimensional change compared with acrylic (4% versus 175), and no heat generation occurs during setting (which might cause bone injury).

In addition, risk of "locking" the prosthesis into place onto unparallel implant abutments is less, because the restoration may be removed & reinserted several times during initial light-cure process. Adjust the temporary prosthesis to fit the abutment before approximation of the tissues. In this way the dentist may inspect the interproximal and margin region thoroughly before soft tissue closure. Approximate the tissues before cementing the prosthesis. Sutures are placed 5 mm away from incision line margin to facilitate their removal at a later date without removing the transitional restoration.

Evaluate transitional restoration for harmonious occlusal contact in centric occlusion. An implant-protective occlusal philosophies are advantageous in this restoration. Cement the immediate-load relined transitional prosthesis with a definitive cement such as zinc phosphate or glass ionomer. If the restoration becomes uncemented during the early loading process, then the risk of overload and failure or crestal bone loss increases.

Option 2

Second option for immediate occlusal load process is to split the surgical appointment from prosthesis delivery appointment. First step of this option is similar to option 1. Preoperative appointments & implant position during surgery are same. However in option 2 an impression of implant body position with additional silicone is made. In addition, vertical occlusal dimension and centric bite registration are recorded. Bite registration may be made with the shell of transitional restoration on abutment or with a baseplate & wax rim (made before surgery and relined as necessary). After the impression, the abutments are removed from implant bodies & replace them with permucosal extensions. Approximate soft tissues similar to a 1-stage surgical procedure. Lab. technician inserts implant body analogs connected to the abutments into the impression, impression is poured and cast mounted to opposing arch. Lab. technician selects & prepares the abutments for restoration & fabricates a transitional prosthesis. Patient returns 7-14 days after surgery. After removing sutures, the permucosal extensions are replaced with abutments that laboratory selected & prepared. Transitional prosthesis is then cemented with a definitive cement.

Final Prosthesis

After healing for 4-8 months (depending on bone density) the transitional restoration may be cut off & the final prosthesis fabricated.

Guidelines for immediate loading

Treatment plan guidelines for completely edentulous patients reflect methods to reduce stress and reduce micro strain at the developing interface.

1. Surface area factors

Dentist should consider the following surface area factors:

- a. **Implant number:** 8 splinted implants or more are suggested for completely edentulous maxillary arch & 6 splinted implants or more for mandible. More implants if very soft bone is present or if force factors are greater (e.g., crown height or parafunction).
- b. **Implant size:** Larger-diameter implants are required in posterior regions of mouth. If larger diameter is not possible, bone grafting or greater implant number is suggested (e.g., 2 implants for each molar).
- c. **Implant design:** High surface area implants (more threads, deeper threads) Compressive versus shear loads (square or plateau-shaped threads).
- d. **Implant surface condition:** Hydroxyapatite-coated implants in poor bone density types (e.g., D4). Rough versus smooth or machine surface condition implants in good bone density situations (e.g., D2 and D3).

2. Force factors

The dentist should consider the following force factors:

- a. **Patient condition:** Parafunction, crown height & muscular dynamics require more implant surface area. Severe parafunction may be a contraindication for completely edentulous patient.
- b. **Implant position:** In completely edentulous maxilla, anterior implants should be at least in bilateral canine position & posterior implants in 1st to 2nd molar position for largest antero-posterior dimension. When forces are greater, dentist should insert an additional implant between the canines. In mandible the largest antero-posterior dimension possible should be used. At least three implants, one in the anterior and one in each posterior region, are necessary.
- c. **Occlusal load direction:** Narrow occlusal tables & no posterior offset loads on transitional restorations in either arch. The cemented transitional prosthesis. Long-axis loads to the implant bodies whenever possible.

Partially edentulous patients

Immediate-load concept also may be used in partially edentulous patient, including single-tooth applications. Immediate loading of implant, suggest immediate restorations rather than full occlusal loading. Because the patient most often has enough remaining teeth in contact to function, the transitional restoration is primarily for esthetics & implant prosthesis is completely out of occlusion. Therefore a nonfunctional immediate teeth (N-FIT) concept is suggested.

Nonfunctional immediate teeth

Indications: Partially edentulous patients with centric occlusal contacts and excursions on natural teeth (or healed implants). Division D1, D2, and D3 bone in regions of implants. Screw-shaped implant bodies, 4 mm or more in diameter, with increased surface area designs to decrease crestal stresses (e.g., Biohorizons Maestro dental implant).

Contraindication

Patients with parafunctional oral habits (i.e., anterior and lateral tongue thrust or biting on a pipe while smoking).

Advantages of nonfunctional immediate loading

Patient has a fixed esthetic tooth replacement soon after stage I surgery. No stage II surgery is necessary (eliminates discomfort for the patient and decreases overhead for the doctor). Implants are splinted during initial healing for biomechanical advantage. The greatest bite force is only during eating and is less than 30 psi. No parafunctional forces from occlusion are possible. Countersinking the implant below the crestal bone is eliminated, which reduces early crestal bone loss. Soft tissue emergence may be developed with transitional prosthesis & tissue allowed to mature during bone healing process. Soft tissue hemidesmosome attachment on implant body below the micro-gap connection may heal with an improved interface.

Disadvantages of nonfunctional immediate loading

Micromovement of implant the can cause crestal bone loss or implant failure is greater than with two-stage approach. Dentist is less likely to reflect the tissue at Stage II and can evaluate implant crest bone directly. Parafunction from tongue or foreign habits (pen biting) may cause trauma and crestal bone loss or implant failure. Impression material or acrylic may become trapped under tissue or between implant and crestal bone. Too soft bone, small implant diameters, or implant designs with less surface area may cause too great crestal stress contours and cause bone loss or implant failure.

Protocol for stage I nonfunctional immediate teeth

Appointment one

Make impression of opposing arch and take tooth shade and centric bite registration. Perform stage I implant surgery (use wider implants when possible). Remove fixation screw and insert ball impression pin. Make impression with additional silicone material. Make sure no impression material is left under flap or around implants. Remove ball impression pin and abutment for cement. Place 3-to 6-mm wide emergence perimucosal healing cap. Suture (tissue thickness should be less than 4 mm).

Lab procedure

Thread ball impression pin and abutment for cement into implant body analog and reinsert into impression. Pour impressions of both arches and mount on articulator. Prepare abutments, if needed. Fabricate transition prosthesis. Soft tissue emergence similar to final restoration. Narrow occlusal table -Transitional prosthesis 1 to 3 mm out of all occlusal contacts (centric relation and excursions).

10- 14 days after stage I surgery

Remove sutures & perimucosal healing caps. Insert two-piece abutment and abutment screw. Use countertorque (hemostat) and tighten to 20 to 30 N-cm (which is less than final preload). Insert transitional prosthesis and evaluate contour & occlusion (no occlusal contacts). Cement transitional prosthesis with temporary definitive cement. Instruct patient to eat soft foods (e.g., pasta, fish and cooked meat). No raw vegetables or hard bread are allowed until final prosthesis delivery. No oral habits, such as gum chewing, are permitted. When possible, the patient should avoid chewing food on implant regions.

Conclusion

Although the teeth in a day's time protocol requires considerable sophistication in according the questions of the prosthodontic team, it offers patients a number of significant advantages, compared to traditional implant-placement protocols. The number of office visits required is minimal. Patients who have to travel long distances to undergo fixed prosthodontic rehabilitation particularly benefit from the condensed treatment time. Furthermore, this approach virtually eliminates post-surgical discomfort while offering an almost instantaneous improvement in speech and masticatory function, esthetics, and patient self-image.

The overall dental experience becomes a positive one helping to counterbalance the negative histories that so often create the dental phobias that lead to dental deterioration. Appropriate patient selection remains critical candidates for this procedure must have a sufficient quality and quantity of bone in order to ensure initial fixation. They also need to be conscientious about following all post-surgical instructions where these elements are present, however, the teeth in a day, time protocol holds the promise of significantly expanding the number of individuals who are willing and able to reap the rewards of implant dentistry.

References

1. Misch CE. Dental Implant Prosthetics. 2nd Ed. 2015. Mosby Publications.
2. Misch CE. Contemporary Implant Dentistry, 2005. Mosby Publications.
3. Babbush CA. Dental implant- the art & science.
4. Singh A, Gupta A, Chaturvedi TP. Immediate placement of implant in fresh extraction socket with early loading. *Contemp Clin Dent.* 2012; 3(2):219–222.
5. Singh M, Kumar L, Chand P. Immediate dental implant placement with immediate loading following extraction of natural teeth. *Natl J Maxillofac Surg.* 2015; 6(2):252-255.
6. Zhu Y, Zheng X, Zeng G, Qu X. Clinical efficacy of early loading versus conventional loading of dental implants. *Sci Rep.* 2015; 5:15995.
7. Kohen J, Matalon S, Block J, Ormianer Z. Effect of implant insertion and loading protocol on long-term stability and crestal bone loss: A comparative study. *J Prosthet Dent.* 2016; 115(6):697-702.
8. Koirala DP, Singh SV, Chand P. Early loading of delayed versus immediately placed implants in the anterior mandible: A pilot comparative clinical study. *J Prosthet Dent.* 2016; 116(3):340–345.