



ISSN Print: 2394-7489  
ISSN Online: 2394-7497  
IJADS 2020; 6(4): 30-33  
© 2020 IJADS  
[www.oraljournal.com](http://www.oraljournal.com)  
Received: 12-08-2020  
Accepted: 18-09-2020

**Dr. Samer Shukry**  
M.A In Prosthodontics, Hama  
University, Faculty of  
Dentistry, Hama City, Syrian  
Arab Republic, Syria

**Dr. Hussein Al-Essa**  
Professor of Prosthodontics,  
Faculty of Dentistry, Hama  
University, Hama City, Syrian  
Arab Republic, Syria

**Corresponding Author:**  
**Dr. Samer Shukry**  
M.A In Prosthodontics, Hama  
University, Faculty of  
Dentistry, Hama City, Syrian  
Arab Republic, Syria

## **A new method for adding the flexible resin (thermoplastic nylon) to the lingual flanges of mandibular complete denture and its effect on the retention of this denture: A case report**

**Dr. Samer Shukry and Dr. Hussein Al-Essa**

**DOI:** <https://doi.org/10.22271/oral.2020.v6.i4a.1044>

### **Abstract**

A healthy 61-year-old Syrian man he was selected from the patients referred to the Removable Prosthodontics Department, Faculty of Dentistry, Hama University.

The patient received one maxillary complete denture and two mandibular complete dentures. One mandibular complete denture was made of conventional heat-cured acrylic resin (Traditional), and the other had its lingual flanges made of thermoplastic nylon IRIS.

Digital force-meter was used to measure retention of mandibular complete dentures at delivery (T1) and at two weeks (T2) and two months (T3) following denture insertion. The treatment results showed an improvement in denture retention with IRIS denture than Conventional one.

**Keywords:** Complete dentures, thermoplastic nylon, lingual flange, retention

### **Introduction**

Denture retention will be a subject perplexing and perpetual until its troubles find their logical solution in understanding its physics. This understanding now in fact exists but it is obscured by repetition of long-held erroneous beliefs. Although the various issues have been analysed in detail and discussed at length, an up-to-date account based on modern research and understanding of materials science has yet to appear in an accessible form for the benefit of the practitioner<sup>[1]</sup>.

Many authors provided tips and recommendations for dentists to improve the quality of complete denture retention<sup>[2, 3]</sup>. Also, denture adhesives and dental implants were used to enhance denture retention. One possible and simple way of enhancing denture retention is by extension of denture flanges to engage an existing soft-tissue undercut<sup>[4, 5]</sup>. However, extension of conventional denture bases into soft-tissue undercuts should be kept minimal due to rigidity of acrylic resin.

The introduction of resilient denture liners<sup>[6]</sup> and flexible acrylic resin<sup>[7]</sup> increased the chance for denture bases to be extended into deeper soft-tissue undercuts to gain further retention without risking the health of the supporting tissues or creating pain and difficulty during denture removal or insertion. Some authors reported the use of permanent soft liners in the retromylohyoid eminence to aid denture retention<sup>[8, 9]</sup>. Lowe<sup>[10]</sup> used resilient silicone lining material (Molloplast-B) to create flexible denture flanges for patients exhibiting undercut tuberosities.

This technique can also be used to aid retention of mandibular complete dentures by creating flexible lingual flanges that engage the lingual undercuts of the mandible.

### **Case Report**

This case report describes an alternative denture design for mandibular complete denture.

The edentulous patient was a Syrian man who was Sixty one years old. he was selected from the patients referred to the Removable Prosthodontics Department, Faculty of Dentistry, Hama University.

The Patient having had no previous complete denture, his last remaining teeth was extracted from three months before recruitment in the study, with well-developed edentulous ridge that

was covered with healthy firm mucosa, with normal Angle Class 1 maxillomandibular relationship, he was free from systemic diseases that affect the neuromuscular control.

### Construction of the dentures

We copied the mandibular stone master cast to obtain two stone master casts in order to construct two sets of dentures by using silicone duplicating material (ecosil +®, Dentaureum, Germany).

Patient received one maxillary denture and two mandibular dentures. One mandibular denture was made entirely of conventional heat-cured acrylic resin and the other mandibular denture was made of conventional heat-cured acrylic resin with thermoplastic flexible resin “IRIS” (IRIS® International Trade Co., Ltd. Tianjin, China) at the lingual flange area.

### (Construction of the mandibular complete denture with lingual flanges made of thermoplastic nylon)

- We perforated the acrylic teeth before the arrangement teeth of the mesio, distal, and lower surface of each tooth, in order to secure the mechanical fixation of the teeth with the flexible resin so that the flexible resin fills these holes.
- The Borders were sealed between the baseplate and the stone master cast, and we isolated the flask and the cast with Vaseline.
- We did flasking the stone cast into the special flask with the preparation of casting ducts for flexible acrylic injection.
- We put a hard silicone on top of the teeth, then isolated the stone cast and the flask with Vaseline, and the cast was invested with gypsum, then we removed the wax.
- We put a hard silicone over the buccal margin of the stone cast.
- We closed the flask and injected the flexible resin at a temperature of (274°C).
- The flask was left to cool to room temperature, then we opened it and removed the silicon placed over the buccal margin of the stone cast.
- The conventional heat-cured acrylic resin was mixed according to the manufacturer's instructions, then placed in the flask while in the pastry phase.
- The flask was closed tightly and the conventional acrylic resin polymerized as in the traditional method.
- We finished and polished the denture.

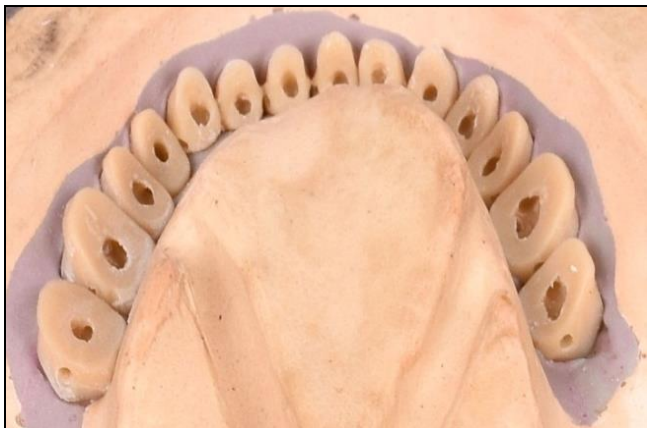


Fig 1: Acrylic teeth perforation.

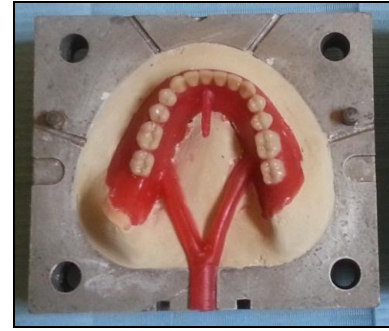


Fig 2: Flasking the cast with preparation of casting ducts.

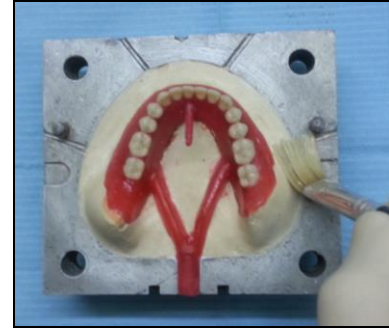


Fig 3: Isolation step.

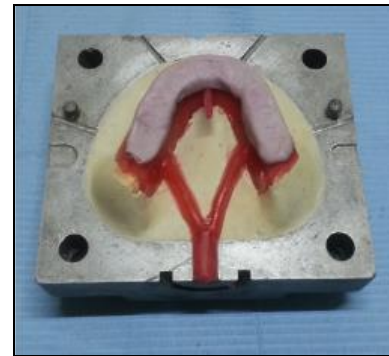


Fig 4: Putting a hard silicone over the teeth.




Fig 5: Removing the wax.

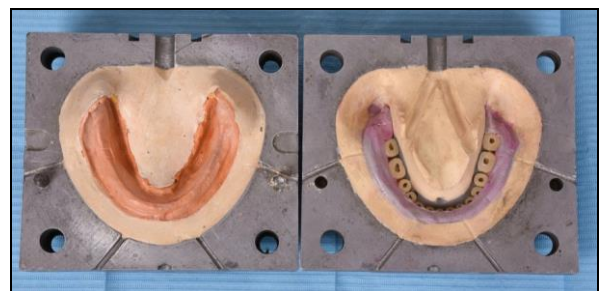


Fig 6: Putting a hard silicone over the buccal margin of the cast.





Fig 6: The flexible resin injection at a temperature of (274°C).

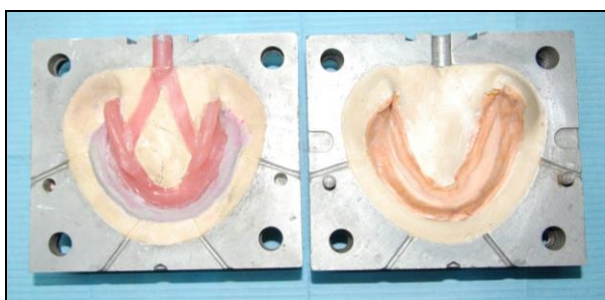


Fig 7: Opening the flask after flexible resin injection.

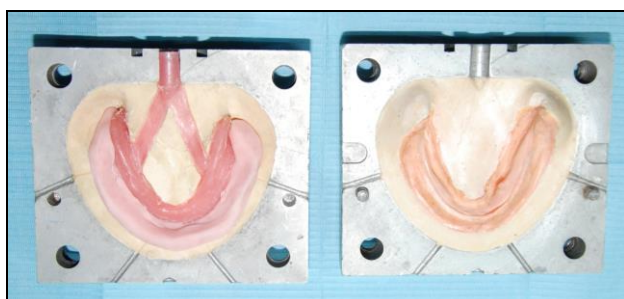


Fig 8: Putting the conventional heat cured acrylic resin in the flask.

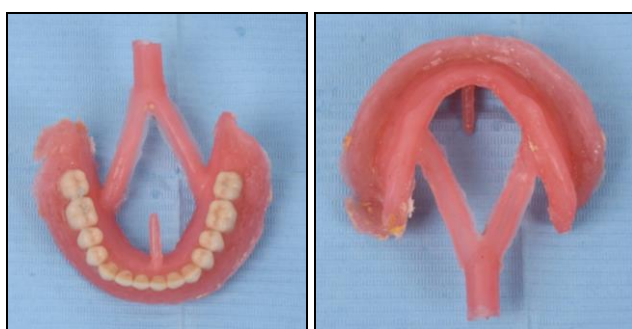


Fig 9: The mandibular complete denture with lingual flanges made of thermoplastic nylon after opening the flask.

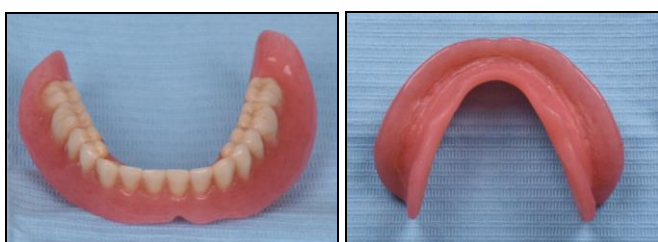


Fig 10: The mandibular complete denture with lingual flanges made of thermoplastic nylon after finishing and polishing.

**Follow-up of patient**

With each type of mandibular dentures, the patient was followed up for two months. At each review appointment, patient’s complaints were noted. The supporting tissues, the denture surfaces and borders, the occlusion and articulation of the dentures, were all examined. Then the dentures were adjusted in the light of clinical examination and patient’s complaints. Retention of dentures was assessed and recorded during the follow-up period.

**Assessment of denture retention**

Retention of mandibular dentures was tested at the time of delivery (T1) and at two weeks (T2) and two months (T3) following denture insertion. A digital force-meter was used to measure denture resistance to vertical displacement (i.e., retention) by applying a pulling force on a metal hook located in the geometric center<sup>[11]</sup> of each mandibular denture.

**Retention of mandibular dentures was assessed as follows:**

We asked the patient to sit comfortably in a dental chair with his head on the headrest and the occlusal plane is parallel to the floor of the room. The mandibular denture was then inserted inside the patient’s mouth. Before insertion of denture with flexible lingual flanges, the denture was immersed in warm water bath (50°C) for five minutes to soften the flexible flange. After denture insertion, tongue freedom and loop position were checked and three minutes seating time was allowed before taking the measurements. The metallic probe of the digital force-meter was then attached to the c-shaped metal hook created at the geometric center of the mandibular dentures and a vertical pulling force was applied to measure denture retention. Retention strength was measured in kilo gram. Three readings were taken and the average value was recorded.

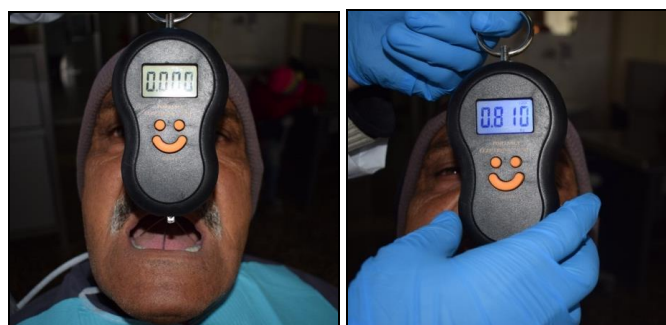

Fig 11: Clinical evaluation of denture retention by a digital force-meter.

**Treatment results**

Digital force-meter was used to measure retention of mandibular complete dentures at delivery (T1) and at two weeks (T2) and two months (T3) following denture insertion.

**Table 1:** Measurements retention of mandibular complete dentures in kilo gram.

	Conventional	IRIS
T1	0.550	0.675
T2	0.695	0.810
T3	1.030	1.217

**Discussion**

Important factors contributing to the success of Prosthodontics Restorations is the skill and expertise of the Prosthodontist and the clinician. At the same time, the equal

important significance is given to the adequate selection of the desired denture base resin<sup>[12]</sup>.

Dr. Walter Wright (1937) introduced Polymethyl methacrylate as a denture base material which became the major polymer to be used. Since ages, polymethyl methacrylate (PMMA) has been used to fabricate the dentures. Some of the problems with acrylic are difficult to address, such as insertion in undercut areas, brittleness of methyl methacrylate which leads to fracture, and allergy to methyl methacrylate monomer<sup>[13]</sup>.

While acrylic resin is the most commonly used denture base material, in this clinical report we used a flexible resin "IRIS" to construct the lingual flanges of mandibular complete dentures.

The flexible resin was introduced first in 1950 as an alternative to conventional acrylic resin denture base material<sup>[14]</sup>.

Despite the relatively old age of the thermoplastic denture base materials, reports to evaluate its impact on denture retention are scarce.

However, this is a short-term clinical report and further studies are recommended to evaluate the long-term quality of retention of mandibular complete dentures with flexible lingual flanges and its impact on patients' satisfaction.

We also recommend that more research be done to evaluate the strength of the bond between flexible resin and acrylic resin.

### Conclusion

The use of flexible resin lingual flanges in the construction of mandibular complete dentures resulted in improved denture retention.

### References

1. Darvell BW, Clark RK. The physical mechanisms of complete denture retention. *Br Dent J.* 2000; 189:248-52.
2. Jacobson TE, Krol AJ. A contemporary review of the factors involved in complete denture retention, stability, and support. Part I: Retention. *J Prosthet Dent.* 1983; 49:5-15.
3. Scott BJ, Hunter RV. Creating complete dentures that are stable in function. *Dent Update.* 2008; 35:259-62, 265-7.
4. Bocage M, Lehrhaupt J. Lingual flange design in complete dentures. *J Prosthet Dent.* 1977; 37:499-506.
5. Von Krammer R. Principles and technique in sublingual flange extension and complete mandibular dentures. *J Prosthet Dent.* 1982; 47:479-82.
6. Soni A. Management of severe undercuts in fabrication of complete dentures. *N Y State Dent J.* 1994; 60:36-9.
7. Rickman LJ, Padipatvuthikul P, Satterthwaite JD. Contemporary denture base resins: Part 2. *Dent Update.* 2012; 39:176 8, 180 2, 184 passim.
8. Whitsitt JA, Battle LW, Jarosz CJ. Enhanced retention for the distal extension base removable partial denture using a heat cured resilient soft liner. *J Prosthet Dent.* 1984; 52:447 8.
9. Mendez M, Lee C. Use of a permanent soft denture liner in the retromylohyoid eminence and knife edge ridge areas of the mandible to aid in retention and stability. *Gen Dent.* 2013; 61:e145.
10. Lowe LG. Flexible denture flanges for patients exhibiting undercut tuberosities and reduced width of the buccal vestibule: A clinical report. *J Prosthet Dent.* 2004; 92:128 31.
11. Weisstein EW. Geometric Centroid. *MathWorld-A*

Wolfram Web Resource. Available from: [http://mathworld.wolfram.com/ GeometricCentroid.html](http://mathworld.wolfram.com/GeometricCentroid.html). [Last accessed on 2020 January4].

12. American Dental Association Specification No.12 dental base resin material. ADA Professional Product Review. 2006; 1(1).
13. Sharma A, Shashidhara HS. A review: Flexible removable partial dentures. *J Dent Med Sci.* 2014; 13:58-62.
14. Rickman LJ, Padipatvuthikul P, Satterthwaite JD. Contemporary denture base resins: Part 2. *Dent Update.* 2012; 39:176-8, 180-2, 184 passim.