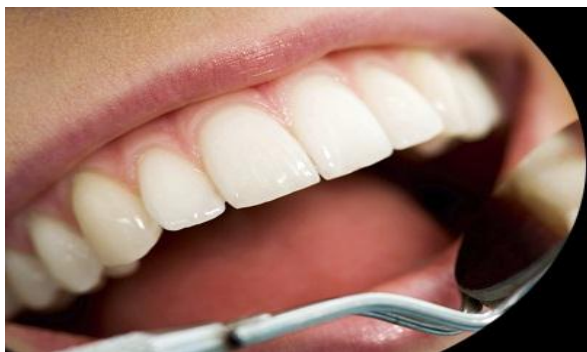



# International Journal of Applied Dental Sciences

ISSN Print: 2394-7489  
ISSN Online: 2394-7497  
IJADS 2020; 6(4): 219-224  
© 2020 IJADS  
[www.oraljournal.com](http://www.oraljournal.com)  
Received: 16-08-2020  
Accepted: 24-09-2020

**Dr. Leo Caroline M**  
Post Graduate Student,  
Chettinad Dental College and  
Research Institute (CDCRI),  
Kelambakkam, Chennai, Tamil  
Nadu, India

**Dr. Serena Francis**  
Senior Lecturer, Chettinad  
Dental College and Research  
Institute (CDCRI),  
Kelambakkam, Chennai, Tamil  
Nadu, India

**Dr. A Beela**  
Post Graduate Student,  
Chettinad Dental College and  
Research Institute (CDCRI),  
Kelambakkam, Chennai, Tamil  
Nadu, India

**Dr. R Sathish Muthukumar**  
Professor and Head of the  
Department, Chettinad Dental  
College and Research Institute  
(CDCRI), Kelambakkam,  
Chennai, Tamil Nadu, India

**Dr. Sreeja C**  
Reader, Chettinad Dental  
College and Research Institute  
(CDCRI), Kelambakkam,  
Chennai, Tamil Nadu, India

**Dr. Nachiammai**  
Reader, Chettinad Dental  
College and Research Institute  
(CDCRI), Kelambakkam,  
Chennai, Tamil Nadu, India

**Corresponding Author:**  
**Dr. Leo Caroline M**  
Post Graduate Student,  
Chettinad Dental College and  
Research Institute (CDCRI),  
Kelambakkam, Chennai, Tamil  
Nadu, India

## Melanin pigment: A review

**Dr. Leo Caroline M, Dr. Serena Francis, Dr. A Beela, Dr. R Sathish Muthukumar, Dr. Sreeja C and Dr. Nachiammai**

DOI: <https://doi.org/10.22271/oral.2020.v6.i4d.1068>

### Abstract

Melanins are group of pigments found in almost all organisms. In humans and animals, it is chiefly responsible for the color of skin, hair, and eyes. It is synthesized by specific cell called as melanocyte, which are heterogeneous in distribution. Apart from imparting color, it also executes various functions. This review explains the basics of melanin pigment, its biosynthesis, functions, and related pathological conditions in oral cavity. This article also explains the histopathological identification of melanin in tissues including the immunohistochemical markers.

**Keywords:** Melanin, melanocytes, pigments, immunohistochemical markers

### 1. Introduction

Melanin refers to a group of ancient pigment found in almost all living organisms. In humans and animals, it is chiefly responsible for the color of skin, hair and eyes. The word “melanin” was derived from a Greek word “*melanos*” meaning dark. Swedish chemist Berzelius used the name to describe a dark pigment extracted from eye. A definition describing all types of melanin is that these are heterogeneous polymers derived from oxidation of phenols and subsequent polymerization of intermediate phenols and their resulting Quinone’s<sup>[1]</sup>.

### 2. Classification

According to their source of origin

- Animal melanin
- Plant melanin
- Fungal melanin
- Bacterial melanin
- Synthetic melanin<sup>[1]</sup>

According to the chemical structure:

- Eumelanin
- Pheomelanin
- Neuromelanin
- Mixed melanin pigment<sup>[1, 2]</sup>

### 3. Melanocytes

#### 3.1 Origin

The cells that perform melanogenesis in humans are called as melanocytes. They originate from the neural crest cells, except for few cells such as retinal pigment epithelium, neurons and adipocytes that produce melanin but belongs to different embryonic origin<sup>[3, 4]</sup>. Around fourth week of embryonic development, the ectoderm overlying the notochord forms neuroectoderm and then neural plate, which eventually folds and forms neural tube. This process is termed as neurulation<sup>[4]</sup>.

During this process the cells from the edges of the neural plate (neural crest), called as neural crest cells, detaches and migrates to various parts in the developing embryo by undergoing epithelial mesenchymal transition. Neural crest cells at first are multipotent but later become

lineage specific according to their location. The cranial and trunk neural crest cells give rise to melanocytes. The precursor cells of melanocytes are called as melanoblasts. The cells that migrate through the dorsolateral path contributes for most of the melanocytes, while those that migrates through the ventral path contributing to the formation of peripheral nerve cells (neurons and glial cells) may also give rise to melanocytes. The precursor for Schwann cells which migrates via ventral path detaches from the nerve and differentiates into melanocytes or if it remains attached to the nerve, it may differentiate into Schwann cells

Melanocytes hence differentiate either directly from neural crest cells or they may arise from the Schwann cell precursor separating from the nerve<sup>[3,4]</sup>.

### 3.2 Distribution

Melanocytes are heterogeneous in distribution and they are present in the basal layer of epidermis of the skin and mucous membranes, hair follicles, cochlea of ear called as stria vascularis, iris of eye, leptomeninges, substantia nigra and locus coeruleus of brain and also in heart and adipose tissue. The retinal pigment epithelial cells originate directly from the optic cup of brain<sup>[3,5]</sup>.

### 3.3 Structure

In oral mucosa, melanocytes are located in the basal layer. It belongs to the group of non – keratinocytes along with other cell types like Langerhans cells, Merkel cells and lymphocytes. Melanocytes are dendritic cells and appear clear in hematoxylin and eosin staining. Melanocytes synthesize melanin and store them within small membrane bound organelles resembling the lysosomes which are called as melanosomes<sup>[6,7]</sup>.

These melanosomes mature and can be divided into four stages according to the level of maturation<sup>[4]</sup>.

Stage 1: Melanosomes appears as spherical vesicles resembling lysosomes

Stage 2: Melanosomes becomes elongated and contains melanogenic enzymes; matrix fibrils formed by glycoproteins are seen.

Stage 3: Melanosomes becomes elliptical or ellipsoidal in shape; melanin synthesis starts and gets deposited over the matrix fibrils imparting brown color to the melanosomes

Stage 4: Melanosomes are packed with melanin and appears darker brown to black in color.

The mature melanosomes migrate from the perinuclear region to the dendritic process of the cell via microtubules. They translocate and finally reach keratinocyte and surround the keratinocyte nuclei forming ‘supranuclear caps’ which exerts a protective effect on the genetic material of the keratinocyte<sup>[8,9]</sup>.

Each melanocyte contacts 36 keratinocytes via their dendritic processes, and forms keratinocyte – melanocyte unit. The ratio of melanocyte to keratinocyte in the basal layer ranges from 1:10 to 1:15. The melanocyte adheres to the keratinocyte by tight junctions where both of them express E cadherins and also by gap junctions. During proliferation and migration, they express N –cadherin. In darker individuals, the melanosomes appear larger, more in number and have longer

degradation time within the keratinocyte<sup>[8,9]</sup>.

## 4. Synthesis of melanin - melanogenesis

Melanogenesis refers to the process of synthesis of melanin. In mammals, melanin is synthesized by a complex reaction involving various signaling molecules which are catalyzed by group of melanogenic enzymes like tyrosinase (TYR), tyrosinase related protein 1 (TRYP1 or gp 75), tyrosinase related protein 2 (TRYP2), gp100 (Pmel17), Melanoma antigen recognizable by T- lymphocytes (MART-1). The gp100 and MART-1 are important enzymes required for structural maturation of melanosomes<sup>[8,9,10]</sup>.

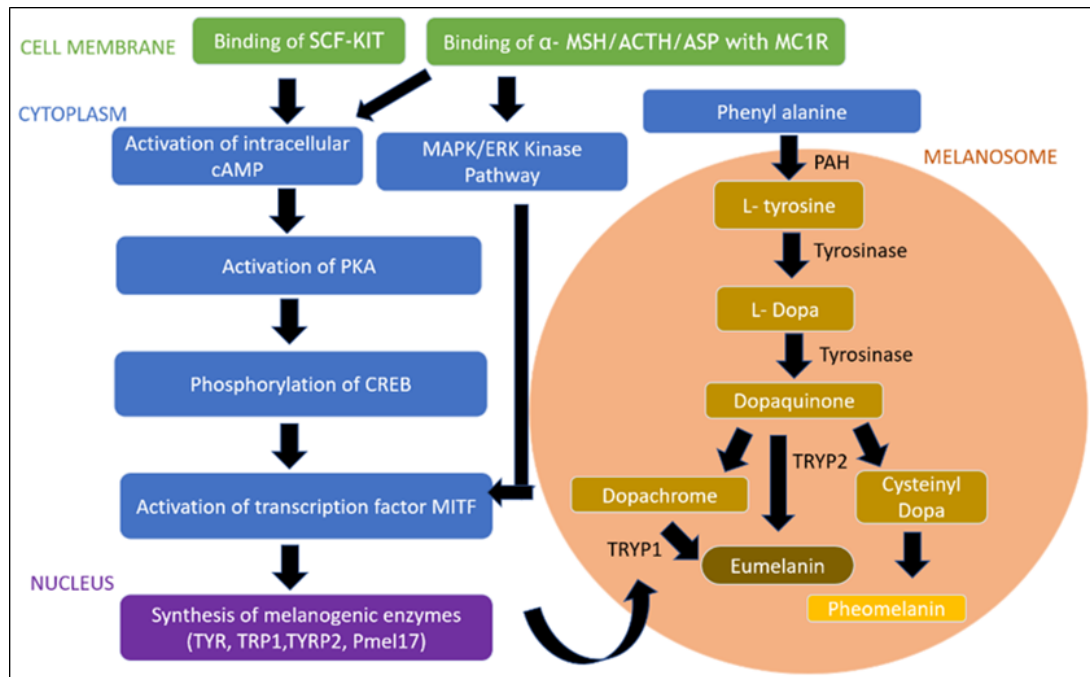
Binding of melanocortin receptor-1 (MC1R), which belongs to class A of G protein coupled receptor, present on cell membrane of melanocytes with  $\alpha$ - Melanocyte Stimulating Hormone ( $\alpha$ - MSH) and Adrenocorticotrophic hormone (ACTH) initiates the process of synthesis of melanogenic enzymes via increasing the second messenger intracellular cAMP which then activates protein kinase A (PKA). The  $\alpha$ -MSH is cleaved from its precursor called as pro-opiomelanocortin (POMC) produced by pituitary gland which exerts a local paracrine regulation. UV radiation stimulates POMC production. This binding of MCR-1 with its agonist  $\alpha$ -MSH, ACTH and ASP (agonist stimulating protein) in turn will lead to phosphorylation of cAMP responsive element binding protein (CREB), which then subsequently activates its downstream target microphthalmia associated transcription factor (MITF). MITF regulates the transcription of melanogenic enzymes like TYR, TYRP1, and TYRP2<sup>[11,8]</sup>. The MITF is also activated via MAPK/ERK kinase pathway, which is activated as result of binding of  $\alpha$ -MSH/ ACTH to MC1R. Binding of stem cell factor (SCF) to KIT receptor also activates the cAMP/ MITF pathway leading to melanogenesis. Apart from these pathways, the Wnt pathway also leads to MITF activation<sup>[8]</sup>.

These enzymes synthesize two major types of melanin:

- Eumelanin (brownish – black) - a large irregular which imparts dark color to the skin
- Pheomelanin (yellowish- red) - a small regular seen in light skin<sup>[9]</sup>.

Eumelanin offers better cytoprotection and possess increased resistance to degradation and neutralizing ability of ROS compared to Pheomelanin. Neuromelanin is another type of dark melanin present in substantia nigra and locus coeruleus of brain<sup>[4,1]</sup>.

The melanin synthesis process within the melanosomes starts with the amino acid precursor L-tyrosine which leads to biochemical pathway termed as Raper-mason pathway. The amino acid L- tyrosine is obtained from the amino acid phenyl alanine present in the cytoplasm. The enzyme phenyl alanine hydroxylase catalyzes this reaction. The formed L-tyrosine is then hydroxylated to L-Dopa by the enzyme tyrosinase. This hydroxylation step is critical and considered to be a rate limiting step in the process of melanogenesis. The L- Dopa is then converted to Dopa quinone which is further converted to eumelanin catalyzed by the enzyme TRYP1 and TRYP2. A condensation product of Dopa quinone and of the amino acid L-cysteine called as cysteinyl Dopa, leads to the formation of Pheomelanin (Fig 1)<sup>[8]</sup>.



- MC1R - Melanocortin receptor-1
- A - MSH -  $\alpha$  - Melanocyte Stimulating Hormone
- ACTH - Adrenocorticotrophic hormone
- ASP - Agonist stimulating protein
- SCF - Stem cell factor
- PKA - Protein kinase A
- CREB - cAMP responsive element binding protein
- MITF - Microphthalmia associated transcription factor
- PAH - Phenyl alanine hydroxylase
- TYR - Tyrosinase
- TRYP1 - tyrosinase related protein 1
- TRYP2 - tyrosinase related protein 2

**Fig 1:** Biosynthetic pathway of melanin

**5. Functions of melanocytes**

- a. Melanocytes perform specific function according to their location such as retinal pigment cells of eye, present behind the retina are responsible for phagocytosis, processing and transport of retinoid and in turnover of outer segment of rods thereby helping in vision<sup>[5]</sup>.
- b. In the brain, melanocytes are responsible for neuroendocrine functions. Reports suggest they have a role in regulation of sleep and respiratory rhythm. It is also suggested that neuromelanin plays a role in neurodegenerative disorders like Parkinson’s disease<sup>[1, 8]</sup>.
- c. Melanin imparts color to the skin, hair and eyes and. The color is determined according to the number and size of melanosomes and also by the type of melanin synthesized. Eumelanin imparts dark brown – black color, whereas pheomelanin imparts yellowish red color
- d. Melanin protects the cellular DNA from the harmful environmental factors such as UV rays, ROS and free radicals
- e. Melanocytes are component of innate immunity. It presents antigen to the T-cells leading to activation and proliferation of T- cells
- f. Lysosomal enzymes such as  $\alpha$ -mannosidase, acid phosphatase,  $\beta$ -N acetyl glycosaminidase,  $\beta$ -galactosidase, and acid lipase are present inside the melanosomes that has antimicrobial property
- g. The melanin produced in gingival sulcular epithelium neutralizes the ROS generated by the gingival plaque
- h. ‘Melanin dust’ is produced as result of degradation of melanosomes as the keratinocytes mature and desquamates. This protects skin and mucous membrane from harmful chemicals and bacterial toxins by rendering them inactive. Hence, Melanocytes and its components prevents proliferation of bacterial and fungal microorganisms<sup>[9]</sup>.

**Table 1.**

Oral physiological pigmentation	Oral pathological pigmentation
Dark skinned individuals (Solitary or multiple light brown to black macule with common site - attached gingiva).	Melanotic macule Oral Melanoacanthoma Smokers Melanosis Melanocytic nevus Malignant melanoma Endocrine disorders – Addison’s disease, Cushing’s disease. Genetic disorders- Peutz- Jeghers syndrome, neurofibromatosis type-1. Idiopathic-Laugier-Hunziker pigmentation

## 6. Physiological oral pigmentation

Physiological mucocutaneous pigmentation is uncommonly seen in routine oral biopsy unless the patient is of a race or ethnic origin [12]. It is commonly seen among dark skinned individuals and is attributed to the increased activity of melanocytes resulting in increased deposition of melanin pigment [9, 13]. A Study from South Africa that oral pigmentation occurs in 98% of black persons. Also 95% of healthy black persons in United States are affected by oral pigmentation. In Australian Aborigines, 80 - 100% of population have physiological oral pigmentation with equal gender distribution. It presents as asymptomatic, light brown to black macules which may be solitary or multiple. The color increases with age and also modified by habits and hormones. Although, physiological pigmentation are not site specific but most seen in attached gingiva, occasionally in alveolar mucosa (Table 1). Histologically, increased melanin pigmentation in the basal layer along with melanin incontinence in the lamina propria of connective tissue is seen without increase in the number of melanocytes [9, 13].

## 7. Pathological oral pigmentation

Pathologic melanin pigmentation can be attributed to various etiologies and can range from reactive lesions, benign and malignant neoplasm and as result of systemic disorders (Table 1) [12]. The pathological entities associated with melanin pigmentation are:

### 7.1 Melanotic macule

It is caused due to increased activity of melanocytes resulting in increased melanin production. The cause may be due to actinic exposure

**C/F:** Most common pigmented oral mucosal lesion characterized by small, solitary, well circumscribed lesion which is brownish black in color. Lower lip, gingiva and palate are common sites affected. The lesion appears asymptomatic and shows a female predilection

**H/P:** Increased melanin deposition in the basal layer with melanin incontinence in superficial submucosal layer. Melanocytic hyperplasia and change in the morphology are generally not seen [12-14].

### 7.2 Oral melanoacanthoma

It is an uncommon entity seems to occur following trauma or chronic irritation with buccal mucosa being common affected.

**C/F:** Buccal mucosa is commonly affected and presents as asymptomatic, rapidly enlarging, ill – defined, solitary pigmented macule involving large mucosal surface. The lesion is also found in lip, palate and gingiva.

**H/P:** Acanthotic and epithelium with pigmented melanocytes seen throughout the epithelium. The epithelium may be spongiotic. Mild inflammatory infiltration is not uncommon. The number of melanocytes may be increased in the basal layer [12, 15].

### 7.3 Smoker's melanosis

Smokers' Melanosis is a condition seen associated with cigarette smoking. Increased melanin production is seen as a protective response of oral mucosa to heat and smoke

**C/F:** Lateral tongue, buccal mucosa and palate are commonly

affected site.

**H/P:** Increased melanin content in the basal layer along with melanin incontinence [12, 14].

### 7.4 Melanocytic nevus

Nevus is a benign condition characterized by proliferation of nevus cells. Nevus cells are pigmented cells that originate from neural crest. They are considered to be a type of melanocytes and they differ from melanocytes in morphology. Nevus cells appear round, ovoid or spindle shaped lacking the dendritic processes and are seen in the basal layer as clusters while melanocytes appear as single cell in the basal layer

**C/F:** Oral melanocytic nevi are rare compared to cutaneous nevi. It appears as well – defined, flat or slightly raised plaque and may range from brown, blue, bluish grey to black in color. The commonly affected sites are hard palate, buccal mucosa and gingiva

**H/P:** Three types according to the location of the lesional cells intradermal/intramucosal nevi, junctional nevi and compound nevi. Intramucosal type is commonly seen in the oral cavity [12]. Another distinct type of nevi called as 'blue nevi' is also rarely seen in oral cavity. The blue color of the lesion is due to Tyndall effect and deeper location of the nevus cells [12-14, 16, 17].

### 7.5 Malignant melanoma

Malignant melanoma is a malignant neoplasm of melanocytes. Melanoma is considered to be more fatal among all skin neoplasms. It is considered to be third most common malignant tumor of skin. Oral malignant melanoma is rare and accounts for less than 1% of all malignant melanomas. Oral melanoma has worse prognosis compared to its cutaneous counterpart.

**C/F:** The common intraoral site of malignant melanoma is hard palate and anterior maxillary gingiva. It may present as flat macule, plaque or mass with well -defined or irregular margins. The color of the lesion appears brown to black and may also lack pigmentation which is termed as Amelanotic melanoma

**H/P:** Malignant melanocytes are seen within the connective tissue. The various types of melanoma include, Superficial spreading, Nodular melanoma, Lentigo maligna melanoma, Acral lentiginous melanoma, mucosal lentiginous melanoma [12, 14, 18, 19].

### 7.6 Other disorders with melanin pigmentation

Melanin pigmentation is seen in various endocrine disorders like Addison disease, Cushing disease. Melanin pigmentation in the above condition is due to increased ACTH/ MSH secretion.

Peutz-Jeghers syndrome, a genetic condition which is characterized by high risk of developing cancer along with labial, perioral and acral pigmentation

Laugier-Hunziker pigmentation is a hyperpigmentation condition of idiopathic origin. It is characterized by multifocal macular pigmentation of oral mucosa, lips and perioral skin Neurofibromatosis type 1 also known as Von Recklinghausen's disease is characterized by cutaneous brown pigmentation called as café-au-lait spots with smooth borders which resembles coast of California [12, 19].



## 8. Bleaching of melanin in tissues

### The need for bleaching

Histopathological examination of melanin containing tissues requires a procedure called as bleaching. This can be attributed to the following reasons:

- Excessive melanin in the tissues tends to mask the cell morphology.
- It hinders with the immunohistochemical (IHC) examination as it hides the antigen- antibody reaction, particularly when 3, 3'-diaminobenzidine (DAB), which is a standard chromogen used in IHC procedure. It produces a brown by product which resembles melanin.
- Melanin has the tendency to absorb UV radiation, which interferes with analysis of nucleic acids (RNA/ DNA).
- Melanin pigment also prevents the PCR by binding to the enzyme DNA polymerase and hence hindering the amplification of nucleic acids.

Therefore, the melanin from the melanocytic lesional tissue has to be removed. This is accomplished by use of strong oxidants which will bleach the melanin [20].

### The two commonly used methods of bleaching

- a. Treatment with 0.25% Potassium permanganate followed by 2% oxalic acid.
- b. Treatment with 10% dilute hydrogen peroxide in phosphate buffer saline (PH 7.5) followed by incubation in water bath or oven at 60°C [20, 21].

## 9. Melanin stains

- a. **Masson -Fontana method:** Melanin has argentaffin property (reduction of ammoniacal silver solution to form metallic silver without an extrinsic reducing agent) and argyrophilic property. It appears black in this method with nuclei appearing red.
- b. **Schmorl's reaction:** This reaction is dependent on the capacity of melanin to reduce ferricyanide to ferrocyanide and produce Prussian blue in the presence of ferric salts. Melanin appears dark blue with nuclei appearing red.
- c. **Enzyme method (DOPA reaction):** This is based on the ability of melanin producing cells to oxidize DOPA to insoluble black- brown pigment by the enzyme tyrosinase which is present inside the cells.
- d. **Fluorescence:** Dopamine and various other aromatic amines like 5- Hydroxy tryptamine, epinephrine, nor – epinephrine and histamine tend to produce yellow fluorescence when treated with formaldehyde. This method is beneficial in case of amelanotic melanoma where there is lack of pigment production [21].

## 10. Immunohistochemical markers for melanocytic tumors

The diagnosis of melanomas and other melanocytic lesions can be done using the following immunohistochemical markers.

- a. **S-100:** It is a maker for cells of neural crest origin (melanocytes). It is a nuclear and cytoplasmic stain. Has high sensitivity for spindle cell and desmoplastic melanoma. Its sensitivity is around 97-100% but has specificity of 75-87% which is low
- b. **Vimentin:** It is a marker for mesenchymal origin and melanoma can be ruled out if negative
- c. **HMB-45:** Developed by Gowen and Vogel in 1980. It identifies gp100/pm117 antigen present in pre-melanosomes. It is expressed in fetal melanocytes and melanoma and negative in adult melanocytes. This is a

cytoplasmic stain which is organelle specific rather than lineage specific. It helps to differentiate benign nevi from melanoma and has sensitivity of 77-100% in primary melanomas and 56-83% in metastatic melanoma

- d. **MART-1:** It is also called as Melan A is expressed in adult melanocytes and in melanomas. This marker has sensitivity of 75-92% and specificity of 95-100% for melanoma
- e. **MITF:** Microphthalmia transcription factor is a nuclear transcription factor for melanocytes and is important for its embryogenesis and postnatal viability. It is a nuclear stain which has highest sensitivity (81–100%) compared with all melanoma markers except S100 and specificity of 88–100%. But may cross react with other cells like macrophages and fibroblasts
- f. **Tyrosinase:** This enzyme is considered as a key enzyme in melanin synthesis that helps in hydroxylation of tyrosine. This marker also has sensitivity of 84-94% and specificity of 97-100%. It has been found to have reduced sensitivity in advanced stage melanomas and also in metastatic lesions
- g. **NK1/C3:** It defines the inner membrane protein of cytoplasmic organelle of melanocyte. It has sensitivity of 86-100% but has poor specificity
- h. Some of the proliferative marker used to distinguish benign nevi from malignant melanoma is ki67, PCNA, Cyclin A, Cyclin B, Cyclin D1, Cyclin D3, P21, P53 which are rarely positive in benign nevi but expressed in melanomas. The marker P16 is positive in benign nevi but negative in 50-98% of melanomas
- i. Newer markers under investigation for melanocytic differentiation are MUM-1, Melanocortin -1, SM5-1, PNL2, TRP-1, TRP-2. Newer signaling molecules Akt, PTEN, Ezrin are also under investigation [22, 23].

## 11. Management of melanin pigmentation

Management of melanin pigmentation includes depigmentation techniques like free gingival grafts, gingivectomy, de-epithelialization using burs, scalpels, lasers (Nd:Yag laser, semiconductor diode laser and CO2 laser) and cryosurgery. Cryosurgery is done using liquid nitrogen where it causes rapid freezing of cell leading to denaturation of proteins and ultimately cell death. Cryosurgery is considered to be cost effective than laser while also eliminating the disadvantage of bleeding associated with scalpel or bur abrasion [24].

## 12. Conclusion

Melanin indeed forms an important endogenous pigment performing wide variety of functions in the body. This review summarized the biosynthesis, functions and the pathology associated with the pigment. Advancements in diagnostic techniques and treatment modalities will further aid in providing successful treatment for those diseases.

## 13. Acknowledgement

The authors are thankful to Chettinad Dental College and Research Institute, for providing the support and guidance to complete this part of work.

## 14. Disclosure of interest

The authors report no conflict of interest.

## 15. References

1. Solano Melanins F. Skin pigments and much more— types, structural models, biological functions, and

- formation routes. *New Journal of Science*, 2014.
2. Kaur H, Jain S, Mahajan G, Saxena D. Oral pigmentation. *International Dental & Medical Journal of Advanced Research* 2015;1(1):1-7.
  3. Yamaguchi Y, Hearing VJ. Melanocytes and their diseases. *Cold Spring Harbor perspectives in medicine* 2014;4(5):a017046.
  4. Cichorek M, Wachulska M, Stasiewicz A, Tyminińska A. Skin melanocytes: Biology and development. *Advances in Dermatology and Allergology/Postępy Dermatologii i Alergologii* 2013;30(1):30.
  5. Plonka PM, Passeron T, Brenner M, Tobin DJ, Shibahara S, Thomas A *et al.* What are melanocytes really doing all day long? *Experimental dermatology* 2009;8(9):799-819.
  6. Kumar GS. *Orban's Oral Histology and Embryology* 2011; 253.
  7. Nanci A. *Ten Cate's Oral Histology Development. Structure and Function*, 2008, 333-4.
  8. D'Mello SA, Finlay GJ, Baguley BC, Askarian-Amiri ME. Signaling pathways in melanogenesis. *International journal of molecular sciences* 2016;17(7):1144.
  9. Feller L, Masilana A, Khammissa RA, Altini M, Jadwat Y, Lemmer J. Melanin: The biophysiology of oral melanocytes and physiological oral pigmentation. *Head & face medicine* 2014;10(1):8.
  10. Yamaguchi Y, Brenner M, Hearing VJ. The regulation of skin pigmentation. *Journal of biological chemistry* 2007;282(38):27557-61.
  11. Schiaffino MV. Signaling pathways in melanosome biogenesis and pathology. *The international journal of biochemistry & cell biology* 2010;42(7):1094-104.
  12. Alawi F. Pigmented lesions of the oral cavity: An update. *Dental Clinics* 2013;57(4):699-710.
  13. Gondak RO, Da Silva-Jorge R, Jorge J, Lopes MA, Vargas PA. Oral pigmented lesions: Clinicopathologic features and review of the literature. *Medicina oral, patologia oral y cirugia bucal* 2012;17(6):e919.
  14. Kaur H, Jain S, Mahajan G, Saxena D. Oral pigmentation. *International Dental & Medical Journal of Advanced Research* 2015;1(1):1-7.
  15. Gupta AA, Nainani P, Upadhyay B, Kavle P. Oral melanoacanthoma: A rare case of diffuse oral pigmentation. *Journal of oral and maxillofacial pathology: JOMFP* 2012;16(3):441.
  16. Dutta D, Kamath VV, Rajkumar K. Oral melanocytic nevi: Report of two cases with immunohistochemical elaboration of their probable origin and maturation. *Indian Journal of Dermatopathology and Diagnostic Dermatology* 2015;2(2):29.
  17. Kauzman A, Rei N, Avon SL. The blue nevus: A rare lesion of the oral cavity. *General dentistry* 2014;62(5):e22-6.
  18. Padhye A, D'souza J. Oral malignant melanoma: A silent killer? *Journal of Indian Society of Periodontology* 2011;15(4):425.
  19. Sreeja C, Ramakrishnan K, Vijayalakshmi D, Devi M, Aesha I, Vijayabanu B. Oral pigmentation: A review. *Journal of pharmacy & bioallied sciences* 2015;7(S2):S403.
  20. Chung JY, Choi J, Sears JD, Ylaya K, Perry C, Choi CH *et al.* A melanin-bleaching methodology for molecular and histopathological analysis of formalin-fixed paraffin-embedded tissue. *Laboratory Investigation* 2016;96(10):1116-27.
  21. Bancroft JD, Layton C, Suvarna K. *Theory and Practice of Histological Technique*. China, Churchill Livingstone 2013, P247-55.
  22. Yaziji H, Gown AM. Immunohistochemical markers of melanocytic tumors. *International journal of surgical pathology* 2003;11(1):11-5.
  23. Ohsie SJ, Sarantopoulos GP, Cochran AJ, Binder SW. Immunohistochemical characteristics of melanoma. *Journal of cutaneous pathology* 2008;35(5):433-44.
  24. Talebi M, Farmanbar N, Abolfazli S, Shirazi AS. Management of physiological hyperpigmentation of oral mucosa by cryosurgical treatment: A case report. *Journal of Dental Research, Dental Clinics, Dental Prospects* 2012;6(4):148.