



ISSN Print: 2394-7489
ISSN Online: 2394-7497
IJADS 2021; 7(1): 425-428
© 2021 IJADS
www.oraljournal.com
Received: 27-11-2020
Accepted: 02-01-2021

Marcia Rejane Brücker
Professor, Discipline of
Radiology, Dentistry Course,
School of Health and Life
Science, Pontifical Catholic
University of Rio Grande do Sul,
Porto Alegre, Brazil

Diego Pohren
Graduate Student, Dentistry
Course, School of Health and
Life Science, Pontifical Catholic
University of Rio Grande do Sul,
Porto Alegre, Brazil

Aline Rose Cantarelli Morosolli
Professor, discipline of Radiology
- Dentistry Course - School of
Health and Life Science,
Pontifical Catholic University of
Rio Grande do Sul, Porto Alegre,
Brazil

Corresponding Author:
Aline Rose Cantarelli Morosolli
Professor, Discipline of
Radiology, Dentistry Course,
School of Health and Life
Science, Pontifical Catholic
University of Rio Grande do Sul,
Porto Alegre, Brazil

Analysis of *Canalis sinuosus* prevalence by cone beam computed tomographs (CBCT)

Marcia Rejane Brücker, Diego Pohren and Aline Rose Cantarelli Morosolli

DOI: <https://doi.org/10.22271/oral.2021.v7.i1f.1166>

Abstract

The aims of this study were to map the main locations of *Canalis sinuosus* (CS), to (i) identify accessory foramina in the hard palate region, (ii) indicate the prevalence, and (iii) view them when using CBCT images. A sample of 230 cone-beam computed tomography (CBCT) examinations was obtained. The CBCT images that were generated by a multiplanar reconstruction of the axial and/or coronal planes were evaluated by On Demand 3D™ Dental software. The prevalence of *Canalis sinuosus* was 224 (97.4%). The examinations had at least one accessory foramen in the maxilla, with corticalization present in 189 (82.1%) for all of those evaluated. The presence of the one accessory foramen was in the anterior palate in 174 (75.65%), on both sides. The highest number was present in 149 examinations (64.8%) on the right side. The bilateral presence of this structure occurred in almost half of the examinations. The most common CS was Classification 3, near to the upper lateral incisor region, for both sides. It was clear that when planning for surgical interventions in the anterior maxilla, the study, and the identification of CS, as well as its ramifications and morphological variations, should be carefully studied and evaluated individually for each patient.

Keywords: *Canalis sinuosus*, anterior maxilla, anatomy, cone-beam computed tomography

1. Introduction

The anterior maxillary region is an area where many surgical procedures are performed in dentistry, such as implant placement, bone grafting, lesion removal, and trauma treatments, requiring the dental surgeon to need a thorough knowledge of the anatomical structures present [1-3].

In the anterior region of the hard palate, besides the incisive foramen, other foramina such as *Canalis sinuosus* (CS) can also be found. This canal is responsible for the passage of the anterior superior alveolar nerve bundle (ASA) which is the branch from the Infraorbital canal (IOC) and is laterally directed to the nasal cavity to the region of the anterior teeth [4] may have ramifications [1, 5, 6]. These foramina may present unilateral or bilateral presentations, originating from branches of the *Canalis sinuosus* (CS) and are associated with accessory foramina (AFs) [1, 3, 7-9]. More than half of these AFs communicate with the CS on the same side, causing direct extension of the neurovascular content of the CS in the anterior portion of the maxilla. [8] These ramifications can interfere with surgical processes and even cause misdiagnostic [10], mimicking apical lesions [2, 6, 9].

The *Canalis sinuosus* (CS) is a structure that is difficult to visualize in radiographic images⁵ and can be disregarded by the dentist [3, 11]. Thus, the use of computed tomography is necessary to analyze these anatomical structures, which may be affected, since they may be present in the anterior region of the maxilla [1, 3, 7-9, 11, 12].

Several studies emphasize the importance and necessity of using CBCT for the planning of invasive procedures with the preservation of noble anatomical structures located in the anterior maxilla, as well as in the canine pillar region, since it is the common site for oral rehabilitation using implants, where there is a higher incidence of CS emergency [1,3, 7-13].

This study had a triple aim: to map the main locations of the CS (i), the accessory foramina in the hard palate region (ii), to indicate the prevalence (iii) using CBCT images.

2. Material and Methods

This observational study was designed as a retrospective analysis of CBCT images obtained from database of the Radiology Service of the Dentistry Course of the School of Health and Life Sciences of the Pontifical Catholic University of Rio Grande do Sul (PUCRS), Brazil. This study was approved by the Committee of Ethics in Research of the PUCRS.

Maxillary CBCT images of patients of all sexes and ages were selected. The following exclusion criteria apply to this research: patients with implant pins in the anterior region, surgical metal plates and screws in the region of interest, presence of included dental elements, midline lesions and facial defects.

For the location of CS and CAs was used the method suggested by Oliveira-Santos *et al.* [1] When the presence of the CS was observed, thus classified according to the following parameters: unilateral or bilateral location and disposition. Coronal, axial, and sagittal sections were evaluated for the complete location of the anatomical structures. To assess the classification of palate location, a figure suggested by Oliveira-Santos *et al.* [1] was used, considered a numbering from one to eight, being the number eight for cases where the CS is not located in any of the previous seven situations (Figure 1). The eight situations according to their location relative to the teeth/incisive foramen can be:

1. central incisor region
2. region between the central and lateral incisors
3. lateral incisor region
4. canine region
5. first premolar region
6. lateral to incisive foramen
7. posterior to incisive foramen
8. anywhere previous location

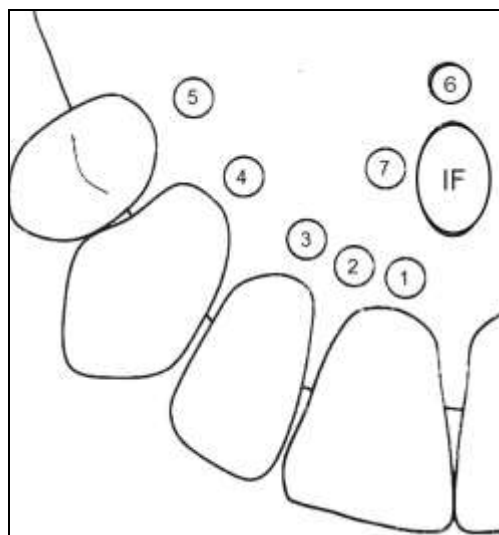


Fig 1: Schematic representation of distribution of CS observed in the palate described by Oliveira-Santos *et al.* [1]

Using the tomography, I-Cat™ device, (Imaging Sciences International, Hatfield, USA), a sample of 230 cone beam computed tomography (CBCT) examinations was obtained, with number of serie ICU082130. Operating parameters were set at 125kVp and 3-7mA and 10mm aluminum filter protection. For all CBCT images, a standardized voxel of 0.2-0.4mm was selected, with different fields of view (FOVs). All CBTC images were evaluated in the On Demand 3D™ Dental

software (Cybermed, Seoul, South Korea). For evaluations, the specific tools of the CBCT software analyzed all CBCT images generated by the multiplanar reconstruction in the axial and/or coronal planes.

The tomographic sections were evaluated by an experienced graduate student and analyzed by an intra-examiner error examiner, the error test was performed from the random selection of 10 previously observed exams. The data collected were tabulated to perform the statistical analysis. The statistical analyses used were Kappa and Qhi-Square tests.

3. Results

In this study 230 CBCT exams were evaluated, 165 (71.7%) female subjects and 65 (28.3%) male subjects (Table 1). Patients' ages ranged from seven to 81 years, with a mean value of 48 years, standard deviation of 15 years. The intra-examiner error test obtained a strong and significant kappa value of 0.74 ($P < 0.05$).

Table 1: CBCT exams into two groups classified by gender.

| Gender | n | % |
|-----------------|-----|------|
| Female subjects | 165 | 71.7 |
| Male subjects | 65 | 28.3 |
| Total | 230 | 100 |

The *Canalis sinuosus* was present in 224 (97.4%) of the exams analyzed and only 06 exams (2.6%) it was not possible to analyze this anatomical structure. Regarding the presence of accessory foramen (AF), at least one accessory foramen was localization externally by the anterior palate in 174 of the evaluated exams (75.65%), both on the right and left sides (Table 2).

Table 2: Presence of CS in CBTC exams.

| Absent/Presence | n | % | Cumulative (%) |
|-----------------|-----|-------|----------------|
| Absent | 6 | 2.6 | 3.0 |
| Doubt | 2 | 0.9 | 3.5 |
| Presence | 221 | 96.1 | 99.6 |
| Doubt | 1 | 0.4 | 100.0 |
| Total | 230 | 100.0 | |

The right side presented the highest number of exams with the presence of AF from the CS, 149 exams (64.8%) when compared to the left side the presence of 133 exams (56.8%) for all exams evaluated. Regarding the bilateral presence of AF, 105 exams (45.65%) with bilateral AF were found. Thus, the bilateral presence of this structure occurred in almost half of the exams (Table 3).

Table 3: Evaluating of the presence of AF from the CS on both the right and left sides of the maxilla.

| AF | Right n | % | Left | |
|---------------|------------|------|------|------|
| | | | n | % |
| Absent | 79 | 34.3 | 97 | 42.2 |
| Doubt visible | 2 | 0.8 | - | - |
| Presence | 149 | 64.8 | 133 | 57.8 |
| Total | 230 | | 230 | |

Based on the classification proposed by Oliveira-Santos *et al.* [1] regarding the presence of a total of 312 AFs used by CS. It was found 167 (53.52%) on the right side and 145 (46.47%) on the left side. Among the discount cases, 28 there were two or more AFs registered on the same side of the maxilla (Table 3).

The location of the most common CS was the classification 3, near to the upper lateral incisor region for both sides obtaining values to frequency 4 (Figure 2). In all cases in which AF was present, this anatomical structure branched from the CS just below the floor of the nasal fossa and was directed to the palate region near the alveolar cortical. In all cases, that AF

was present, this anatomical structure branched from the CS just below the floor of the nasal fossa and was directing to the palate region near the alveolar cortical. There were 312 AFs observed, however 12 were not classified into the seven categories used for this research, and then they received numbering eight (Table 4).

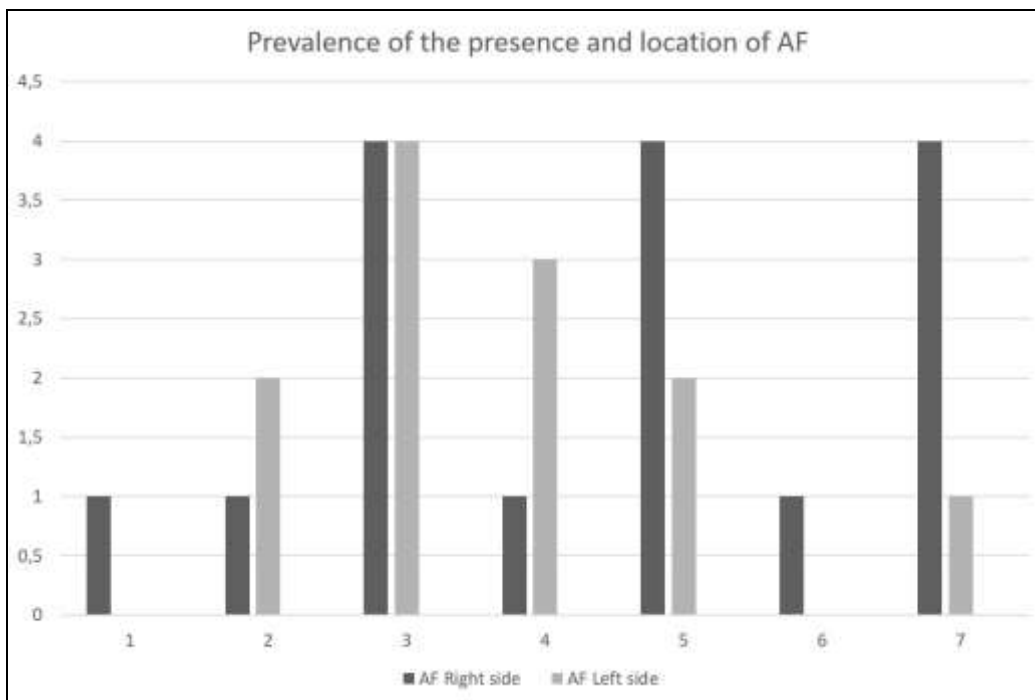


Fig 2: Prevalence and location classification according with Oliveira-Santos *et al.* [1]

Table 4: Classification as location of the AF from the CS.

| Classification | Right n | % | Left | |
|----------------|---------|------|------|------|
| | | | n | % |
| 1 | 21 | 13.9 | 14 | 6.1 |
| 2 | 15 | 9.9 | 25 | 10.9 |
| 3 | 39 | 25.8 | 32 | 13.9 |
| 4 | 21 | 13.9 | 12 | 5.2 |
| 5 | 31 | 20.5 | 33 | 14.3 |
| 6 | 1 | 0.7 | - | - |
| 7 | 14 | 9.3 | 14 | 6.1 |
| 8 | 9 | 6.0 | 3 | 1.2 |
| Doubt | 79 | 34.3 | 97 | 42.2 |
| Total | 230 | | 230 | |

According to exams that had at least one AF in the maxilla, the corticalization of the AF was present in 189 (82.1%) CBCT scans and 37 (16.1%) were not viewed (Table 5).

Table 5: Prevalence of the corticalization of the CS.

| Corticalization | n | % |
|-----------------|-----|------|
| Presence | 189 | 82.1 |
| Doubt | 4 | 1.7 |
| Absent | 37 | 16.1 |
| Total | 230 | |

4. Discussion

Among the main anatomical structures considered during surgical planning in the anterior region of the maxilla are the incisor canal and the incisive foramen, which contain the nasopalatine vascular-nerve bundle inside [14]. However, the existence of another anatomical structure should also be taken into account during a surgical stage in this region, the CS, responsible for the ASA vascular bundle, [4, 15] which presents

itself as a bilateral structure, rarely unilateral. [7] Carelessness in identification this structure can determine the surgical failure of the procedure, since damage to vascular and nervous structures may pose risks of hemorrhage, hyperesthesia, paraesthesia and pain, causing a decrease in the quality of life of the patient [5, 8, 15]. Due to the relatively high prevalence of CS, the identification of this structure has clinical relevance, mainly to avoid iatrogenesis in the anterior maxilla [3].

The CS has the insertion point anterior to the incisive canal and at this location, this structure commonly presents anatomic variations in the anterior to the palate, called AFs. [1, 3, 7, 8] According to Von Arx *et al.* [8] more than half of these AFs communicate with the CS on the same side, and this probably represents a direct extension of the neurovascular content of the CS in the anterior region of the anterior maxilla.

In the present study of 230 CBTC scans evaluated, most of the exams were female, totaling 165 CBCT imaging (71.7%) and only 65 males (28.3%). This variation can be considered mainly by cultural factors, since in the southern region of the country the male gender may have less care and concern for their own health when compared with the opposite gender. According to Ghandourah *et al.* [16] there was no significant difference between gender for occurrence of CS. For Von Arx *et al.* [8] there was a tendency of seeing more AFs in older than in younger subjects, but the presence of AFs was correlated neither with age nor with gender. Also, for Oliveira Santos *et al.* [1] not statistically significant difference regarding the frequency of AFs and the gender or age was similarly reported.

Considering the AFs located in this research, 12 could not be classified according to the Oliveira Santos *et al.* [1]

classification; however, it is important to note that this structure has a great anatomical variation what its classification difficult. Differences in the definition of the exact position of the AF for a specific classification may occur, since the method used has dental and anatomical structures as reference, varying greatly among patients. Many variations can be expected from the origin, course, and distribution of the maxillary nerves and vessels to teeth [1].

According to the data obtained in this research, the region with the largest number of AF on the palate was near to the lateral incisors and upper premolars being considered a large risk area where on-site procedures may cause damage to anatomical structures.

Among the AFs analyzed approximately, 80% of them have corticalization, which classifies the CS and its branches as a noble structure in the anterior region of the maxilla. And that its presence should not be underestimated but considered during procedures in the region, since the presence of bone corticalization in a vascular-nerve bundle indicates that such a structure is not only a nutritive channel.

It was possible to observe great differences from the results obtained in this study. According to research conducted by Oliveira-Santos *et al.* and Von Arx *et al.* [8], a prevalence of 15.7% (n = 178) and 27.8% (n = 176) of AF was observed in the anterior palate region, respectively. Ghandourah *et al.* [16] obtained a prevalence value of 67.6% (n = 219) for this structure which it was the approximate value that was found in the present study, 75.6% (n=230). A total of 312 AFs from the CS was obtained and distributed in 174 exams (75.6%).

The sample used was similar to several previously cited studies, thus the prevalence difference found can be suggested as anatomical variations present among diverse groups and populations, considering ethnicity, descent, and other genetic factors. A research showed that frequency of anatomical variations may be related to the ethno-geographic context [17]. Although for other authors it was not possible to infer additional comparisons related to ethnicity, they suggested that the need for further studies in different geographic regions to obtain different results to confirm these variations [1].

5. Conclusions

Thus, the visualization and analysis of the anatomy of the CS in most of the CBCT scans contained in the sample of this study showed the prevalence of 97.4%, in addition to the presence of corticalized AFs in 58.3% of cases. Based on these findings, it was clear that when planning for surgical interventions in the anterior maxilla, the study and identification of CS, as well as its ramifications and morphological variations should be carefully studied and evaluated individually to avoid possible complications during and after surgery.

6. References

1. de Oliveira-Santos C, Rubira-Bullen IR, Monteiro SA, León JE, Jacobs R. Neurovascular anatomical variations in the anterior palate observed on CBCT images. *Clin Oral Implants Res* 2013;24(9):1044-8. doi: 10.1111/j.1600-0501.2012.02497.x.
2. Neves FS, Crusoé-Souza M, Franco LCS, Caria PHF, Bonfim-Almeida P, Crusoé- Rebello I. Canalis sinuosus: a rare anatomical variation. *Surg Radiol Anat* 2012;34:536-
3. Arruda JA, Silva P, Silva L, Álvares P, Silva L, Zavanelli R *et al.* Dental implant in the Canalis sinuosus: A case

report and review of the literature. *Case Rep Dent* 2017; 2017:4810123. doi: 10.1155/2017/4810123.

4. Jones FW. The anterior superior alveolar nerve and vessels. *J Anat* 1939;73:583-591.
5. Kohavi D. Demonstration of unusually wide artery in the maxillary alveolar bone using a reformatting program of computed tomography: a case report. *Int J Oral Maxillofac Implants* 1994;9:444-448.
6. Shelley AM, Rushton VE, Horner K. *Canalis sinuosus* mimicking a periapical inflammatory lesion 1999;186:378-379.
7. Wanzeler AMV, Marinho CG, Alves Júnior SM, Manzi FR, Tuji FM. Anatomical study of the *Canalis sinuosus* in 100 cone beam computed tomography examinations. *Oral Maxillofac Surg* 2015;19:49-53.
8. Von Arx T, Lozanoff S, Sendi P, Bornstein MM. Assessment of bone channels other than the nasopalatine canal in the anterior maxilla using limited cone beam tomography. *Surg Radiol Anat* 2013;35:783-790.
9. Torres MGG, Valverde LF, Vidal MTA, Crusoé-Rebello IM. Branch of the *Canalis sinuosus*: a rare anatomical variation – a case report. *Surg Radiol Anat* 2015;37(7):879-881. doi:10.1007/s00276-015-1432-9.
10. Manhães Júnior LR, Villaça-Carvalho MF, Moraes ME, Lopes SL, Silva MB, Junqueira JL. Location and classification of *Canalis sinuosus* for cone beam computed tomography: avoiding misdiagnosis. *Braz Oral Res* 2016;30(1):e49. DOI: 10.1590/1807-3107BOR-2016.vol30.0049.
11. McCrea SJJ. Aberrations causing neurovascular damage in the anterior maxilla during dental implant placement. *Case Rep Dent* 2017, 5969643. doi: 10.1155/2017/5969643.
12. Ganz SD. Cone beam computed tomography-assisted treatment planning concepts. *Dent Clin North Am* 2011;55(3):515-36, viii. doi: 10.1016/j.cden.2011.02.019.
13. Ferlin R, Pagin BSC, Yaedú RYF. *Canalis sinuosus*: A systematic review of literature. *Oral Surg Oral Med Oral Pathol Oral Radiol* 2019;127(6):545-55.
14. Bornstein M, Balsiger R, Sendi P, Von Arx T. Morphology of the nasopalatine canal and dental implant surgery: a radiographic analysis of 100 consecutive patients using limited cone-beam computed tomography. *Clinical Oral Implants Res* 2011;22:295-301.
15. Heasman PA. Clinical anatomy of the superior alveolar nerves. *Br J Oral Maxillofac Surg* 1984;22(6):439-47. DOI: 10.1016/0266-4356(84)90051-2.
16. Ghandourah AO, Rashad A, Heiland M, Hamzi BM, Friedrich RE. Cone-beam tomographic analysis of Canalis sinuosus accessory intraosseous canals in the maxilla. *Ger Med Sci* 2017;15:20. doi: 10.3205/000261.
17. Liang X, Jacobs R, Corpas LS, Semal P, Lambrechts I. Chronologic and geographic variability of neurovascular structures in human mandible. *Forensic Sci Int* 2009;190:24-32.