



ISSN Print: 2394-7489
ISSN Online: 2394-7497
IJADS 2021; 7(2): 102-105
© 2021 IJADS
www.oraljournal.com
Received: 19-01-2021
Accepted: 21-02-2021

Dr. Mounika Ayinala
Postgraduate Student,
Department of Prosthodontics,
Rajarajeswari Dental College
and Hospital, Bangalore,
Karnataka, India

Dr. Shwetha Poovani
Professor, Department of
Prosthodontics, Rajarajeswari
Dental College and Hospital,
Bangalore, Karnataka, India

Dr. Gautam Shetty
Head of the Department,
Department of Prosthodontics,
Rajarajeswari Dental College
and Hospital, Bangalore,
Karnataka, India

Dr. Shreya Bukkapatnam
Senior Lecturer, Department of
Prosthodontics, Rajarajeswari
Dental College and Hospital,
Bangalore, Karnataka, India

Corresponding Author:
Dr. Mounika Ayinala
Postgraduate Student,
Department of Prosthodontics,
Rajarajeswari Dental College
and Hospital, Bangalore,
Karnataka, India

Enhancing patient's esthetics through complete denture: An amalgamation of techniques

Dr. Mounika Ayinala, Dr. Shwetha Poovani, Dr. Gautam Shetty and Dr. Shreya Bukkapatnam

DOI: <https://doi.org/10.22271/oral.2021.v7.i2b.1196>

Abstract

Every human being aspires to look beautiful and will continue to do so even when the odds are against them as they get older. Nowadays almost every edentulous patient demands a lot on the esthetics front, at least with hope for having to overcome their sunken/hollow cheek, for that slight bit of joy having to reminisce their past, when they were young and beautiful. By the use of the maxillary cheek plumpers, some support can be provided to the cheek and thereby the esthetics as well, but having to do so will be at the cost of the discomfort which the patient endures due to its added weight. This article describes the combination of Hollow Denture along with Cheek Plumper techniques, to provide more comfort to the patients, while it being non-invasive & cost-effective for the benefit of all kinds of people, as it is within every person's rights to look wrinkleless & attractive.

Clinical Implication: This technique enables the elderly and those with poor manual dexterity by completely removing any effort which needs to be put in as there is no need for attachments & enhancing the facial esthetics while remaining cost-effective. It is a quick non-invasive procedure to provide better esthetics to the discouraged/discomforted patients, without causing much difficulty in usage on a day to day life.

Keywords: hollow denture, cheek plumper, complete denture, facial esthetics

Introduction

One of the main objectives of a removable complete denture is to benefit the patients with the process of deglutition/ improve their masticatory efficiency. Fabrication of this complete denture is unique for every patient and it cannot be limited to any specific procedure. Often, patients are concerned about their facial esthetics to maintain their professional and social relationships and retain their self-confidence [1]. Due to the loss of dentition, alveolar ridge resorption, and soft tissue changes; concavities are noticed below the malar prominence producing sunken/ hollow cheek appearance. In the past, various surgical treatments were carried out for providing adequate facelifts using implants, but those procedures are invasive and time-consuming [2]. To overcome those disadvantages, simpler approaches had been described such as the use of cheek plumpers [3, 4].

Typically, cheek plumper comes as a single-unit prosthesis which extends anteroposterior and mediolaterally from premolar to molar region to provide support to the cheeks. They provide a feeling of fullness to the mouth while it contours the patient's mouth by being an integral part of the maxillary/mandibular prosthesis. However, it tends to add more weight to the denture and thereby on the residual alveolar ridges, leading to poor retention of the prosthesis [5, 6]. Hollow denture technique on the other hand is known for its light-weighted dentures and is usually given to the patients where the load on the residual alveolar ridges is significantly lighter, thereby making the patients feel more comfortable.

This article describes the combination of Hollow Denture along with Cheek Plumper techniques, to provide more comfort to the patients, while remaining non-invasive & cost-effective, to benefit the most on contributing towards patient's esthetics.

Clinical Report

A 78-year-old female College and Hospital with a chief complaint of missing teeth and requested for the replacement sought care at the Dental of the same.

On extraoral examination, there was wrinkling of the skin, loss of resiliency of facial muscles, and hollowing of cheeks as shown in figure 1. Intraoral examination revealed completely edentulous upper and lower arches. The patient gave a history of mobile teeth that were extracted in the past 1 year and was completely edentulous for 3 months. Upon revealing the above-made observations to the patient, the patient desired a prosthesis which would improve the masticatory function and ultimately provide a healthier look. Diagnostic/primary impressions of maxillary and mandibular arches were made using impression compound (pinnacle impression compound, dental products of India) which were poured in dental plaster. Custom trays were fabricated using auto-polymerizing resin for carrying out border molding and secondary impression procedures using low fusing impression compound & light body addition silicone impression material respectively. Maxillo mandibular relationship was established following the facebow transfer to orient the maxilla to the cranium as shown in figure 2. During the try-in appointment, waxed up denture was first tried on the patient to verify the centric occlusion. To provide a fuller appearance of face for the patient, additional modeling wax strips were added on the maxillary denture on the right and left side from the distal end of canine to the molar region which was further evaluated to check for symmetry as shown in figure 3.

Steps for the fabrication of Hollow Denture with Cheek Plumper (After try-in):

1. Measure the thickness for the modeling wax from the base plate, by using an endodontic file with a rubber stop as shown in figure 4a.
2. The thickness of the adapted wax is about 10mm as shown in figure 4b.
3. Duplicate the maxillary master cast using irreversible impression material. Adapt a sheet of 2mm thickness modeling wax and invest it into the flask by conventional compression molding technique as shown in figure 5. After dewaxing, apply a tin foil substitute and pack the heat polymerizing acrylic resin into the mold space.
4. Retrieve the final heat cure denture base from the flask, trim and polish it.
5. Meanwhile, invest the trial dentures and post dewaxing, place the polished denture base plate on the cast and check for the proper closure of both the components as shown in figure 6. Look for any gap, trim, and adjust the denture base to ensure proper closure of the flask.
6. Following this, mix silicone putty and roll it along its length maintaining a thickness of 8mm. Attach it to the polished denture base from the distal end of canine to the molar region on the right and left side and secure it using a cyanoacrylate as shown in figure 7a.
7. Adapt heat polymerizing acrylic resin to the plaster mold containing prosthetic teeth. Thereafter, carry out the conventional process of bench curing and cooling.
8. Retrieve the maxillary and mandibular dentures from the flasks as shown in figure 7b and remount it on the semi-adjustable articulator to adjust the occlusion. Drill a hole of 5 mm in diameter distobuccal to the most posterior teeth in the maxillary denture as shown in figure 8.
9. Use a tweezer to pull out the silicone putty roll on both

sides and finish & polish the dentures in the usual manner to seal the openings using auto-polymerizing acrylic resin as shown in figure 9.

10. Check the denture for adequate seal and then deliver it to the patient as shown in figure 10.

Discussion

Various methods of hollowing maxillary/mandibular dentures were proposed in the past by several authors by using gelatin mix, polystyrene (thermocool pieces) and silicone putty [7-10]. Every technique has its pros and cons. This innovative technique does not make use of the procedures indicated for hollow denture techniques like clear, pressure formed matrix during the trial stage to minimize the laboratory procedures, and the use of endodontic file aided in evaluating the thickness of silicone putty to be added to the base plate. Usually, upon sealing the openings made in the denture for retrieval of silicone putty with auto-polymerizing resin, it tends to have a seepage. However, there was no seepage observed at the closure of the hole (openings made for silicone putty retrieval) despite it being too small in dimension.

Typically, facial esthetics enhanced using the cheek plumpers are fabricated with numerous attachments such as magnets, press stud fasteners, double die pins, friction lock, customized castable attachments.¹¹⁻¹⁵ There could be a possibility for swallowing the attachment while aspirating or during the consumption of food as they are too small and thereby putting the patients at risk. Patients with poor manual dexterity would find it difficult to use these detachable prostheses due to the tedious procedures involved and might have to endure the discomfort caused by the added weight on the prosthesis.

The procedure described in this article overcomes the cons faced by the use of generic cheek plumper, while being inexpensive with no further lab equipment needed in the fabrication of the complete denture and eliminates the breakage of any attachments or corrosion of any magnets, without the need for any additional maintenance.

This particular patient suffered from poor neuromuscular control and had remained edentulous for a long time. In such situations, where there are sunken cheeks and broad denture bearing area, the technique described in this article can be utilized for fabrication of complete denture with cheek plumpers, as conventional dentures along with typical cheek plumper would add weight to the prosthesis.

The planning of complete denture was slightly altered for the benefit of the patient to provide better ease, by delivering a weightless prosthesis with the buccal bulge to compensate for the sunken cheeks. The concept of cheek plumper with hollow denture was combined in this contemporary design, thereby achieving this technique in a straight forward, non-invasive, and cost-effective way.

From the time of delivery of the prosthesis, the patient was recalled thrice within 6 months to re-evaluate the dentures. The patient did not complain of any discomfort with the prosthesis either during speech or mastication and her bystanders were pleased to notice the esthetic outcome of the treatment.

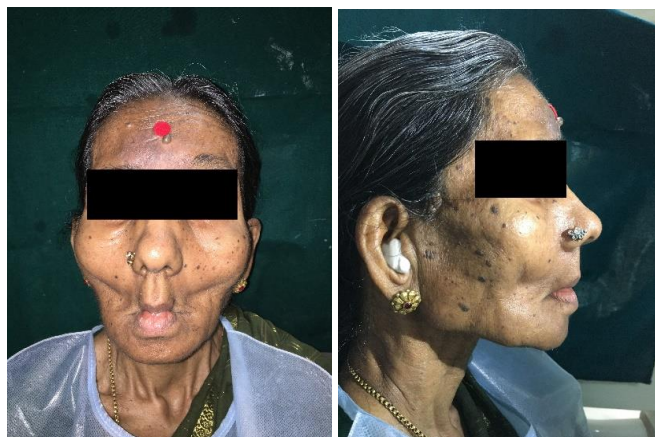

Fig 1: Extraoral view- frontal and lateral



Fig 4b: Thickness of adapted wax was 10mm

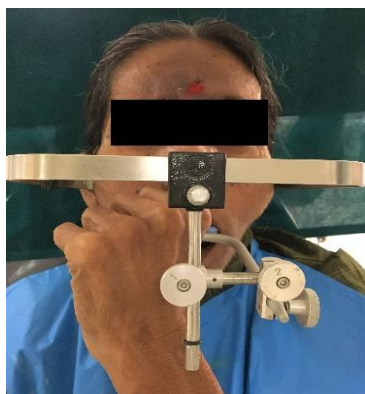

Fig 2: Facebow transfer

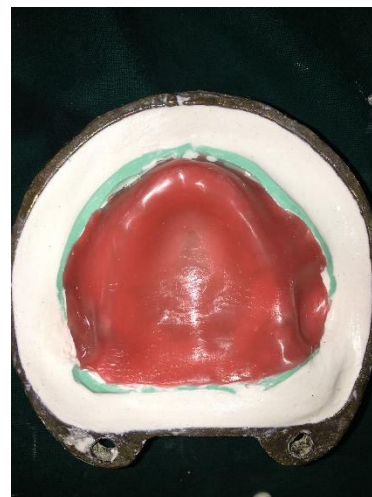

Fig 5: 2mm thickness modelling wax adapted



Fig 3: Waxed up dentures

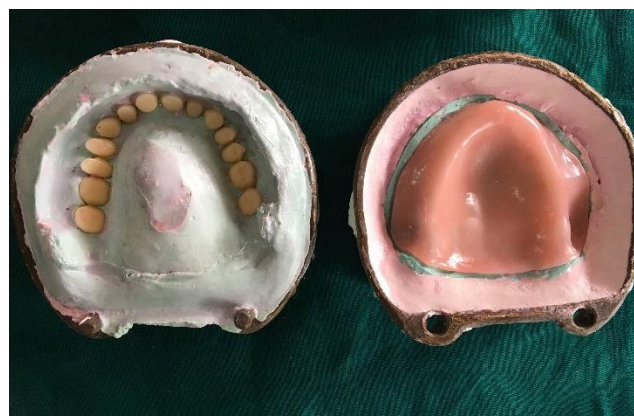

Fig 6: Post dewaxing, adaptation of denture base

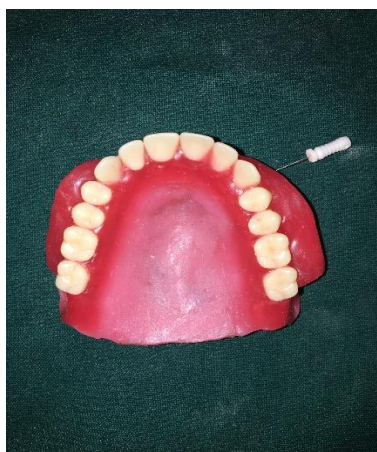


Fig 4a: Endodontic file used to measure thickness

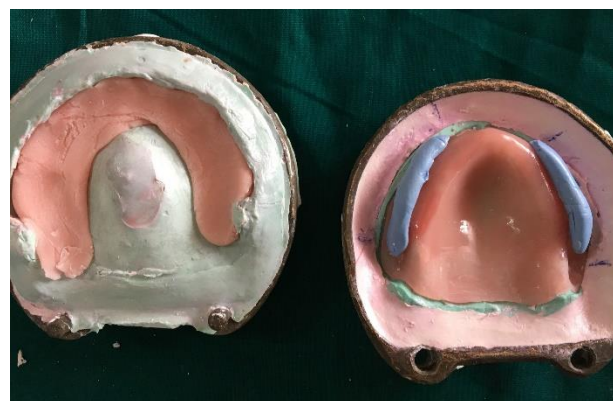

Fig 7a: Attachment of silicone putty to denture base and packing

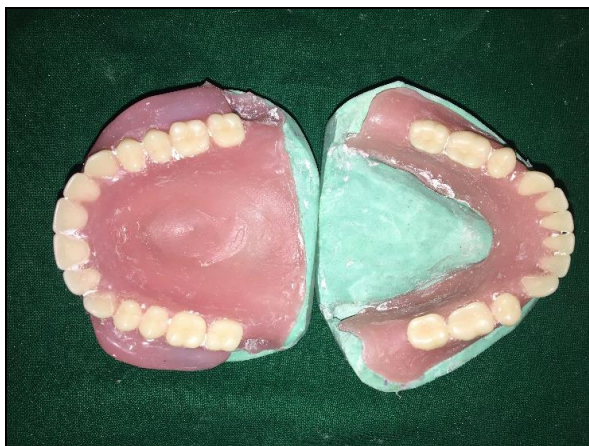

Fig 7b: Retrieval of dentures after acrylization

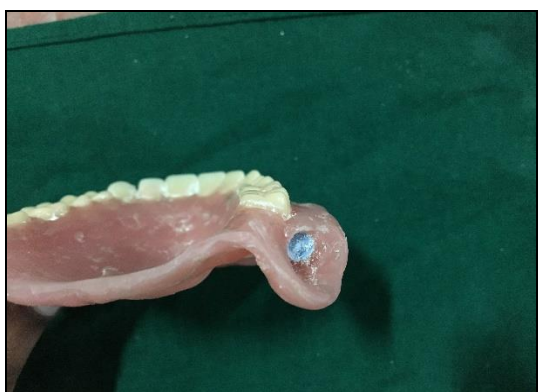

Fig 8: Opening of 5mm diameter

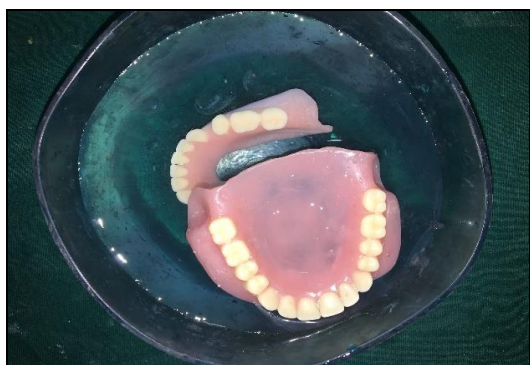

Fig 9: Finished and polished dentures

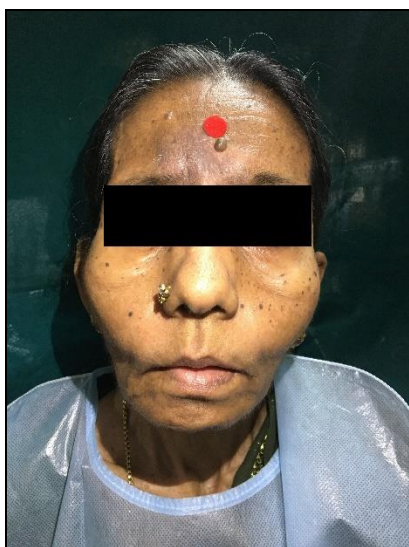

Fig 10: Extraoral frontal view

Conclusion

Adequate support to the cheeks has been provided to improve the overall appearance of the patient's face. The technique described in this article for the fabrication of complete dentures by incorporating a bugle can bring down the weight of the prosthesis, thereby redefining the esthetic of the patients. Usually, patients get psychologically affected because of sunken cheeks but restoring the contour of the face through this technique helps such patients in regaining their confidence and also enables the elderly without any difficulty in usage on a day to day life.

References

1. Krajcicek DD. Achieving realism with complete dentures. *J Prosthet Dent* 1963;13:229-35.
2. Bains JW, Elia JP. The role of facial skeletal augmentation and dental restoration in facial rejuvenation. *Aesthetic Plast Surg* 1994;18:243-6.
3. Lazzari JB. Intraoral splint for support of the lip in Bell's palsy. *J Prosthet Dent* 1955;5:579-81.
4. Larsen SJ, Carter JF, Abrahamian HA. Prosthetic support for unilateral facial paralysis. *J Prosthet Dent* 1976;35:192-201.
5. Keni NN, Aras MA, Chitre V. Customised attachments retained cheek plumper prosthesis: A case report. *J Indian Prosthodont Soc* 2012;12:198-200.
6. Virdiya NM, Palaskar JN, Wankhade J, Joshi N. Detachable cheek plumpers with different attachments for improving esthetics in a conventional complete denture: A clinical report. *J Prosthet Dent* 2017;117:592-6.
7. Deogade SC, Patel A, Mantri SS. An alternative technique for hollowing maxillary complete denture. *J Indian Prosthodont Soc* 2016;16:412.
8. Shetty V, Gali S, Ravindran S. Light weight maxillary complete denture: A case report using a simplified technique with thermocol. *J Interdiscip Dent* 2011;1:45.
9. O'Sullivan M, Hansen N, Cronin RJ, Cagna DR. The hollow maxillary complete denture: A modified technique. *J Prosthet Dent* 2004;91:591-4.
10. Radke U, Mundhe D. Hollow maxillary complete denture. *J Indian Prosthodont Soc* 2011;11:246-9.
11. Punia V, Mishra R, Khandelwal M, Verma N, Handa M. Magnet retained detachable cheek plumper: innovation personified-a case report. *Int J Prosthet Dent* 2013;4:16-20.
12. Kamakshi V, Anehosur GV, Nadiger RK. Magnet retained cheek plumper to enhance denture esthetics: case reports. *J Indian Prosthodont Soc* 2013;13:378-81.
13. Deogade SC. Magnet retained cheek plumper in complete denture esthetics: a case report. *J Dent (Tehran)* 2014;11:100-5.
14. Bhushan P, Aras MA, Coutinho I, Rajagopal P, Mysore AR, Kumar S. Customized cheek plumper with friction lock attachment for a completely edentulous patient to enhance esthetics: a clinical report. *J Prosthodont* 2019;28:e1-5.
15. Pudi S, Kota S, Ch KK, Kaladi SR, Gade RR. An Innovative Technique Using a Stainless Steel Double Die Pin Retained Cheek Plumper in Complete Denture Esthetics: A Case Report. *Cureus* 2019;11:1-8.