



International Journal of Applied Dental Sciences

ISSN Print: 2394-7489
ISSN Online: 2394-7497
IJADS 2021; 7(2): 114-119
© 2021 IJADS
www.oraljournal.com
Received: 20-01-2021
Accepted: 25-02-2021

Dr. Kotaiah Theruru
MDS, Professor and Head of the
Department, Department of
Pedodontics and Preventive
Dentistry, Government Dental
College and Hospitals,
Vijayawada, Andhra Pradesh
India

Dr. BhavyaReddy ChethiReddy
BDS, MPH,
Content editor for WHO Project
Centre for cancer epidemiology,
Tata Memorial Center, Mumbai,
Maharashtra, India

Ellis-Van Creveld syndrome - A Systematic Review and Case Report

Dr. Kotaiah Theruru and Dr. BhavyaReddy ChethiReddy

DOI: <https://doi.org/10.22271/oral.2021.v7.i2b.1199>

Abstract

Ellis-Van Creveld syndrome is a rare autosomal recessive disorder which can be diagnosed at an early stage based on various clinical features and oral manifestations. The aim and objective of this article is to conduct a brief literature review on oral manifestations, diagnostic criteria and treatment protocol of Ellis-Van Creveld Syndrome and also a case study of 7-year-old boy is reported. Two databases were used and totally 261 articles are retrieved, out of which only 16 articles were selected after applying inclusion & exclusion criteria. Results concluded that Dentists should be aware of the features of this syndrome for making early diagnosis and facilitate multidisciplinary treatment.

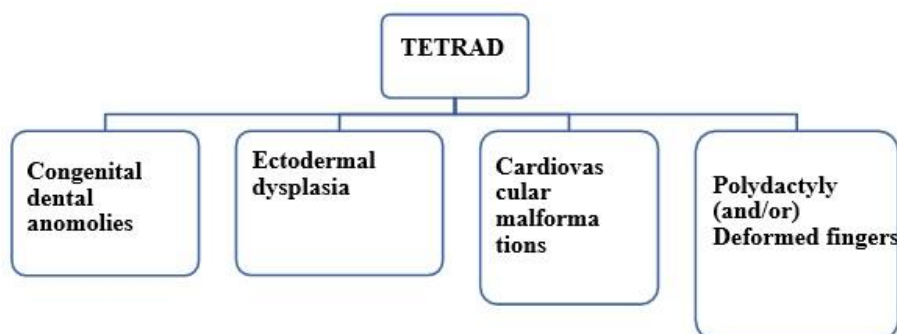
Keywords: Ellis-Vann Creveld syndrome, Oral manifestations, Dental anomalies, clinical features, Multidisciplinary approach

1. Introduction

Ellis-van Creveld syndrome (EVCS) also known as chondro-ectodermal dysplasia was coined and described in the year 1940 by Simon Van Creveld and Richard Ellis. The first case report was published in 1933 by Rustin McIntosh and few years later collaborated with Richard Ellis and Simon Van Creveld in paper writing [1]. EVCS is a rare autosomal recessive disorder with the estimated birth prevalence of 7/1,000,000 in general population (Non-Amish) and 1/5000 in Amish population of Pennsylvania in USA and native population of western Australia [2]. Today, the syndrome is known to affect almost all the races [3-5].

In about 66% of population EVCS is associated with mutations in EVC1 and EVC2 genes located on the chromosome 4p16 [5-7]. Sequencing analysis is used to identify these genes [6]. However, some affected individuals don't have the mutation which shows that there are other genes which are also responsible for EVCS [1]. Consanguinity in parents is reported for 30% of the cases [3], [5].

Diagnosis of EVCS is made in prenatal period from 18th week of pregnancy and post-natal period by clinical examination [5] which presents tetrad of symptoms as shown in the flowchart. Genetic analysis is not mandatory for the diagnosis of this syndrome [9].



Corresponding Author:
Dr. Kotaiah Theruru
MDS, Professor and Head of the
Department, Department of
Pedodontics and Preventive
Dentistry, Government Dental
College and Hospitals,
Vijayawada, Andhra Pradesh
India

EVCS is typically characterized by Short ribs with narrow chest, Congenital heart defects (Nearly half of the patient’s death is reported in the childhood due to these cardiovascular malformations [5], [10]. Disproportionate dwarfism, postaxial polydactyly of hands and feet, Genu vulgam in very few cases, Ectodermal dysplasia (Dystrophic nails, malformed teeth and hypodontia). Multidisciplinary approach is recommended for management [5], [11].

Oral manifestations of Ellis-Van Creveld syndrome are very diverse which include both soft and hard tissues [12]. The most common clinical manifestation is labiolingual adhesions and multiple frenula. Other manifestations include enamel hypoplasia and rarely presence of only few small peg shaped teeth or absence of teeth [13].

Objective

The objective of this Literature review is to explain diagnostic criteria, various oral manifestations and treatment protocol in Ellis-Van Creveld syndrome based on the Case reports and reviews from 2005 to 2020 along with our own Case report which revealed a lot of rare features.

This paper provides all the possible physical, extra and intra-oral manifestations for the dentist to diagnose EVCS early and provide the desirable treatment.

Case Report

A 7-year-old boy reported to the department of pedodontics and preventive dentistry at government dental college and hospital, Vijayawada with the chief complaint of difficulty in eating and speaking due to the presence of only 4 teeth

Medical history:

Patient had congenital cardiac malformations like Atrial septal defect (ASD) with patent ductus arteriosus, perforated Inter atrial septum, Dilated right Atrium and right ventricle. The ASD was treated at the age of 1 year 4 months through mid-line sternotomy. Patient had Cleft lip and cleft palate for which Tennison cleft lip repair and anterior cleft palate repair (Palatoplasty) were done respectively at the age of 2 years 6 months. He also had an occipital dermoid cyst which was removed by surgery.

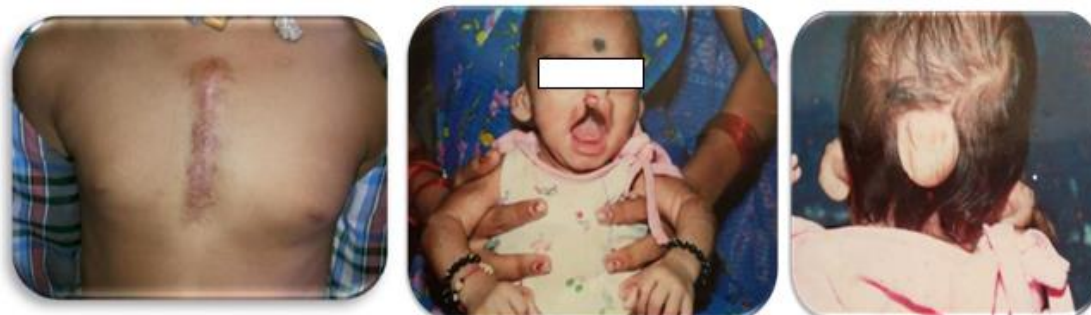

Fig 1: Cleft lip and palate

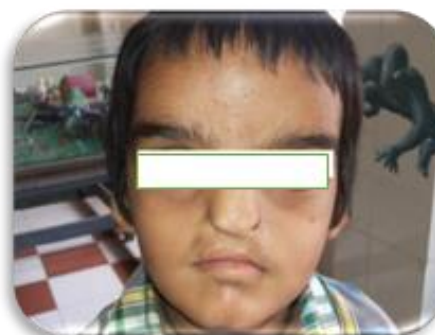Occipital Dermoid Cyst

Family history

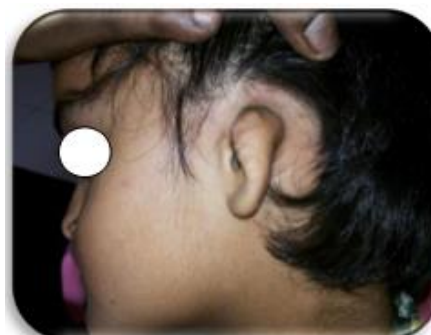Patient is the only child of a consanguineous marriage. The parents are second cousins and they are normally developed. There is no evidence of similar manifestations earlier in the family which makes the patient to be the first person to have the syndrome.

Physical Examination

Comprehensive clinical examination showed that the patient is moderately built and nourished with relatively short height for his age. Bilaterally the hands and feet demonstrated ectodermal dysplastic features like hypoplasia of the distal phalanges, Hallux varus (wide gap between big toe and other toes), flexion of interphalangeal joints and dysplastic finger nails. The hair is not sparse but fine and straight. Cranio-facial examination revealed that patient has orbital hypertelorism, widened nasal dorsum and malformed ears where the helix of the ear is bent inwards.



Orbital Hypertelorism



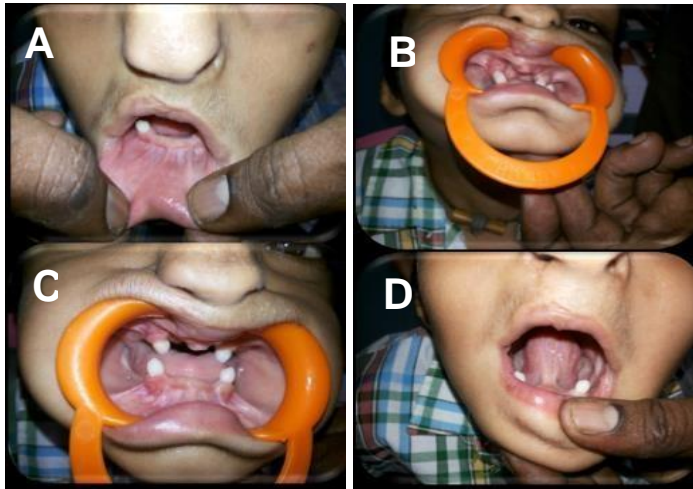
Malformed ears

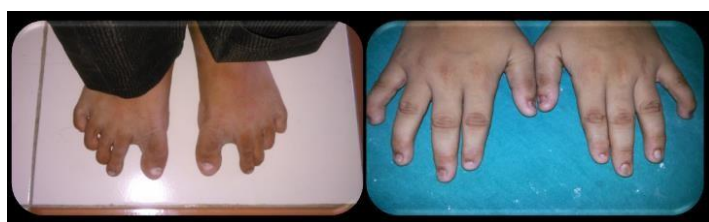

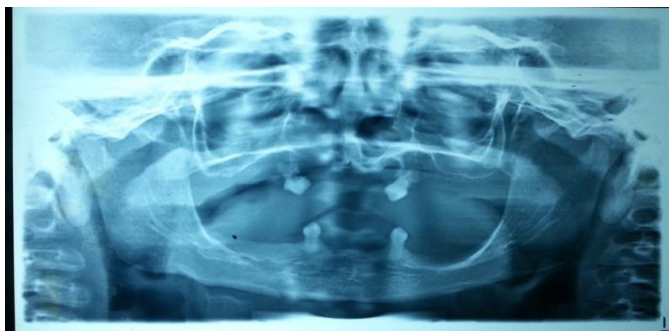
Fig 2: Hallux varus and Dysplastic nails

Intra-oral examination:

Considering the chief complaint which is difficulty in mastication and phonation, intra-oral hard tissue examination revealed the presence of only four peg/conical shaped teeth (C) which are hypoplastic. Soft tissue examination showed multiple labio-gingival frenula (A) associated with labio-gingival adherence (B) and absence of muco-buccal fold in both maxillary and mandibular anterior region and ankyloglossia (D).



An OPG (Orthopantomogram) showed that there is complete absence of permanent dentition.



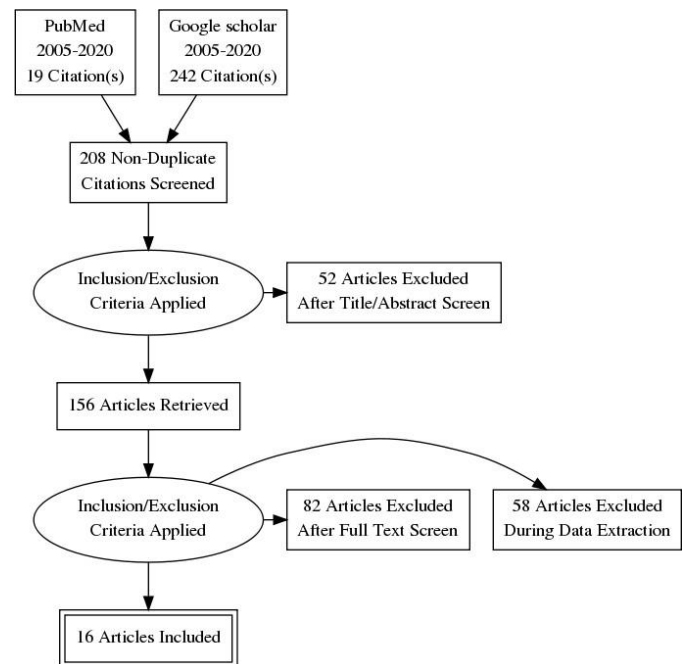
Based on the clinical and radiographic findings of the physical and dental examination, the patient was diagnosed with the Ellis-Van Creveld Syndrome.

Patient cooperation especially in opening the mouth for oral examination is extremely low as he suffered from medical phobia due to lot of procedures since childhood. Nevertheless, we performed intraoral soft tissue and hard tissue examination and recommended prosthodontic treatment for improvement of phonation, mastication and aesthetics. Even after scheduling several behavioural management appointments, parents and patients were not ready for treatment so they never came back to start the treatment.

Methods

An advanced literature search was performed on PubMed and Google scholar using Key words "Ellis-Van Creveld Syndrome", "Chondro-ectodermal dysplasia", "Oral manifestations", "Dental", "Clinical findings" and "Ellis-van Creveld syndrome", "Oral manifestations" respectively. Considering the facts that the syndrome is rare and availability of limited resources, we included all the studies ranging from Clinical trials, systematic reviews, randomized controlled trials to case reports. We retrieved 242 articles

from google scholar and 19 articles from PubMed. We have used Prisma method to finalize the desired articles and used the software ZOTERO to eliminate the duplicates. A total of 16 articles are used after considering inclusion and exclusion criteria, to write this literature review. Refer to the following Prisma diagram for detailed description.

**Inclusion criteria**

- Date of publication: Articles from 2005 to 2020
- Articles that include clinical trials, cross sectional studies, literature and systematic reviews and case studies published in Academic and various dental journals
- Studies that focus on Oral and other clinical manifestations and Treatment protocol in Ellis- Van Creveld syndrome
- Free full text articles

Exclusion Criteria

- Articles that are published before 2005
- Articles and information on the general websites which are not based on extensive research
- Articles that included other syndromes, molecular biology, genetic sequencing

Results

A total of 16 case series and reports were selected and analyzed to find out most common oral manifestations of Ellis-Van Creveld syndrome.

The sample sizes in all the selected case reports is mostly (n=1) except for Gokulraj *et al.*, 2016 (n=2) and Kurian *et al.*, 2007 (n=3) so the results shows totally 19 cases. The age range is between 36 weeks and 27 years. The year of publication is between 2005 to 2020, as discussed earlier in the methods. The summary of the table includes descriptive data (name of the author), year of publication, number and age of the patients included in the case reports, Oral manifestations and treatment considerations for each patient with/without involvement of cardiac anomalies.

Name of the Author	Year of publication	Age of the Patient	Oral Findings	Treatment protocol
Veena KM <i>et al.</i> , [2]	2011	12 years	Absence of mucobuccal fold, conical shaped teeth, missing permanent teeth and retained deciduous teeth, hypoplastic enamel	Multidisciplinary approach was selected. Conical teeth are built by composite, acrylic partial denture was made by prosthodontist, frenectomy for high labial frenum was performed as its obstructing the prosthesis
Alves-Pereira D <i>et al.</i> , [4]	2009	21 years	Multiple frenula, Midline Deviation, Malocclusion, hypodontia,	The patient doesn't wear any prosthesis, Bone graft for the laser implant surgery done as there are no heart anomalies in the patient
Guiguimde WPL <i>et al.</i> , [5]	2018	3 years	Conical shaped teeth Labiokingival adhesion, Enamel hypoplasia, incomplete dentition, conical teeth, diastemas, multiple frenulae, Radiographic examination showed oligodontia.	Education on Oral hygiene was provided to the parents. Fissure sealants were done to prevent tooth decay.
Nazemisalman B <i>et al.</i> , [9]	2017	7 years	Maxillary and mandibular incisors are absent, Multiple frenula, grossly decayed teeth	Antibiotic prophylaxis was prescribed before the dental extraction as the patient had valvular heart disease. Extraction of grossly decayed deciduous teeth are done followed by restoration. Removable acrylic prosthesis was fabricated for the missing teeth to facilitate chewing and phonation.
Shetty P <i>et al.</i> , [12]	2015	17 years	Multiple frenulae with absence of mucobuccal fold, ankyloglossia, missing lower incisors, conical shaped teeth,	Patient was referred to orthodontist, maxillofacial surgeon and prosthodontist for the treatment.
			mucobuccal fold, gingival inflammation, Enamel hypoplasia.	
Kurian K <i>et al</i> [18]	2007	10years 8 years 1 year 7 months	1. Gingiva mucosal adhesion, no mucobuccal sulcus, Oligodontia, Conical anterior Teeth 2. Maxillary mucogingival adhesions, no mucobuccal fold, premature loss of deciduous teeth 3. Mucogingival adhesions, notching of maxillary and Mandibular alveolar ridges, upper lip atrophy	Multidisciplinary approach was suggested
Meriç, <i>et al</i> [19]		7 years	Hypodontia, abnormal frenal attachments, decayed teeth, delayed 1 st permanent molar eruption, neonatal teeth, conical teeth	Restoration of decayed teeth with compomer filling, extraction of neonatal tooth, prosthesis implantation was recommended to the parents but they rejected the extraction and prosthesis
Shah B <i>et al.</i> , [20]	2008	12 years	Presence of neonatal teeth, absence of mucobuccal fold, fusion of labio- alveolar mucosa, enamel hypoplasia, agenesis, grade 3 mobility of lower anterior teeth.	As the patient doesn't have any cardiac abnormality the lower anterior teeth were extracted and prosthetic rehabilitation is done. Orthodontic treatment is suggested.
Shaik S <i>et al.</i> , [21]	2016	13 years	Multiple frenulae, absence of mucobuccal fold, labiokingival adherences, impacted lower anterior, grossly decayed 36, conical teeth	Surgical extraction of impacted lower anterior teeth, grossly decayed 36 and full mouth rehabilitation is advised
Thapa R <i>et al.</i> , [22]	2008	36 weeks	Multiple frenulae, neonatal teeth	As the patient is only 36 weeks old parents didn't prefer any treatment.
Aminabadi NA <i>et al.</i> , [23]	2010	5 years	Dental caries of multiple teeth, conical teeth, oligodontia, taurodontism, absence of mucobuccal fold, multiple frenulae	Multidisciplinary dental therapeutic approach was selected for all the oral manifestations
Naqash TA <i>et al.</i> , [24]	2018	15 years	Congenitally missing maxillary lateral incisors and mandibular incisors, Microdontia, midline diastema, multiple labial frenula, unilateral crossbite on left side.	As the patient have atrial septal defect all the dental procedures were done as per guidelines from American heart association to prevent endocarditis. Scaling, labial frenectomy, patient was put on Quad Helix and after 12 weeks of treatment crossbite is corrected and retention appliance was given, Denta implants are planned for missing teeth.

Discussion

Ellis-Van Creveld syndrome is an autosomal recessive disorder mostly found in Amish people due to consanguineous marriage [15] [3] the signs range from involvement of ectodermal to endodermal which is common to rare respectively. The ectodermal dysplastic features include hypoplastic nails and teeth which is very common, mesodermal involvement include heart and kidney and most rarely endodermal involvement in lungs and kidneys [15] [10].

Clinical and oral manifestations include congenital heart anomalies, ectodermal dysplastic features like hypoplastic nails, teeth, hypodontia, hypoplasia of distal phalanges, short stature [25] which are all present in our case [5] [26].

Congenital heart defects occur in almost 50% of the cases and most common kind of problem is atrial septal defect and rarely ventricular septal defect. Our case here has atrial septal defect which was operated [16] [28] [29]. Most of the reported EVC patients have normal intelligence though CNS abnormalities are reported in few cases [22]. Our patient was having medical phobia due to number of appointments for various procedures since childhood. But his IQ levels and behavior are reported to be normal by the parents. About 30% of the cases are reported to have parental consanguinity and even in our case parents had consanguineous marriage [3], [5], [30]. The common oral manifestations of Ellis-Van Creveld syndrome are summarized from 16 case reports and they include Absence of the gingival sulcus, Multiple frenula, mucogingival adhesions, dystrophic philtrum, hypodontia, conical shaped teeth and neonatal are the remarkable intra-oral features in EVCS [18], [25], [32], [33]. Also, hair lip, cleft lip, cleft palate, ankyloglossia, oligodontia, Malocclusion, supernumerary teeth, taurodontism, microdontia, and delayed eruption can be seen [15], [21], [14], [34]. If all the teeth are present malocclusions are very common. Because of the presence of deep pits and fissures it is common to develop carious lesions [23], [19], [12], [9]. Our case has almost most of the intra oral findings and one of the rare features include presence of only 4 conical teeth in the whole upper and lower arch without any succeeding permanent tooth buds. Presence of rare oral manifestations helps us distinguish Ellis-Van Creveld syndrome from other syndromes [25].

Differential diagnosis includes orofacial digital syndrome, Weyer's acrofacial dysostosis and asphyxiating thoracic dystrophy. Orofacial digital syndrome is excluded in our case as this syndrome typically has moderate mental retardation, fissured tongue, hypoplastic nasal cartilage which are not present in our case, though multiple gingivolabial frenula and ankyloglossia are similar to both Ellis-Van Creveld syndrome and Orofacial digital syndrome [4], [10]. Most of the features of Weyer's acrofacial dysostosis and Ellis-Van Creveld syndrome overlaps such as, tooth and nail deformities, short stature and mutation of same genes, except for the heart defects which is absent in Weyer's acrofacial dysostosis [4], [28]. It is really hard to distinguish between Asphyxiating thoracic dystrophy and Ellis-Van Creveld syndrome by looking at the radiographs of long bones and hands and pelvis as they both look same. But it can be differentiated by presence of renal failure associated with hypertension, which is the classic feature of Asphyxiating thoracic dystrophy [19], [24].

Before proceeding to the treatment protocol, a proper clinical and radiographic examination is mandatory for best clinical decision. Almost all the analyzed case-reports in this paper have proposed a multidisciplinary approach for the management of Ellis-Van Creveld syndrome. The

multidisciplinary approach involves cardiologist, pulmonologist, radiologist, orthopedician, pediatricians, Prosthodontist, Pedodontist, Orthodontist [36-37]. Dentists plays a vital role in treating patient with EVCS. Early detection of oral manifestations helps to plan an effective treatment plan. The approach differs in every case due to various oral manifestations but a multidisciplinary approach leads to success [1], [38], [39].

50-60% of patients have cardiac deformities [5] [29]. Therefore, dental management including frenectomies, extractions, root canal, scaling and draining the abscess has to be done under antibiotic prophylaxis to prevent infective endocarditis and use of antiseptic mouth wash reduces the bacteremia [1], [9]. Before any major surgeries Echo-cardiogram has to be performed to access the Heart function [40]. Preventive treatment includes educating parents about oral hygiene, fissure sealants and topical fluoride application [34], [36]. Removable or fixed dental prosthesis are recommended to maintain the space, improve function, speech and mastication to avoid malnutrition. Restoration is required for decayed teeth. Surgical correction is advised for multiple frenula, labiogingival adhesions, ankyloglossia and other soft tissue abnormalities [36]. Regular counselling for parents and children is mandatory to treat psychological trauma caused by multiple dental visits and compromised aesthetics [24].

Conclusion

Many articles (Literature reviews, systematic reviews and case reports) covered cases explaining the clinical/oral manifestation of Ellis-Van Creveld syndrome.

Conflict of Interest

No

References

1. Lauritano D, Attuati S, Besana M, Rodilosso G, Quinzi V, Marzo G *et al.* Oral and craniofacial manifestations of Ellis-Van Creveld syndrome: a systematic review. *Eur J Paediatr Dent* 2019;20(4):306–10.
2. Veena KM, Jagadishchandra H, Rao PK, Chatra L. Ellis-van Creveld syndrome in an Indian child: a case report. *Imaging science in dentistry* 2011;41(4):167-70.
3. Kalaskar R, Kalaskar AR. Oral manifestations of Ellis-van Creveld syndrome. *Contemporary clinical dentistry* 2012;3(Suppl1):S55.
4. Alves Pereira D, Berini Aytés L, Gay Escoda C. Ellis-van Creveld syndrome. Case report and literature review. *Medicina Oral, Patología Oral y Cirugía Bucal* 2009;14(7):340-343.
5. Ali BR, Akawi NA, Chedid F, Bakir M, Ur Rehman M, Rahmani A *et al.* Molecular and clinical analysis of Ellis-van Creveld syndrome in the United Arab Emirates. *BMC Med Genet* 2010;25:11:33.
6. Ohashi I, Enomoto Y, Naruto T, Tsurusaki Y, Kuroda Y, Ishikawa H *et al.* A severe form of Ellis-van Creveld syndrome caused by novel mutations in EVC2. *Hum Genome Var* 2019;6:40.
7. Umair M, Seidel H, Ahmed I, Ullah A, Haack TB, Alhaddad B *et al.* Ellis-van Creveld syndrome and profound deafness resulted by sequence variants in the EVC/EVC2 and TMC1 genes. *Journal of genetics* 2017;96(6):1005–1014.
8. Guiguimé WPL, Agoda P, Bationo R, Kaboré WAD, Ouattara S, Konsem T. Oral manifestations in Ellis-van Creveld syndrome: a case report. *Journal of Oral*

- Medicine and Oral Surgery 2018;24(2):76–80.
9. Nazemismalman B, Salah S, Vahabi S, Nabtieh A. Oral Ellis-van Creveld Syndrome: A Brief Review of Literature and A Case Report. *Journal of Dentistry and Oral Implants* 2017;6;1(4):1.
 10. Kar A, Pradhan D, Pahi J, Patra M, Mohanty P, Rath G *et al.* Autopsy Findings in a Case of Ellis Van Creveld Syndrome with Review of Literature. *International Journal of Clinical Medicine* 2014;2014.
 11. Tahririan D, Eshghi A, Givchchian P, Tahririan MA. Chondroectodermal dysplasia: a rare syndrome. *Frontiers in Dentistry* 2014, 361-4.
 12. Shetty P, Shetty D, Priyadarshana PS, Bhat S. A rare case report of Ellis Van Creveld syndrome in an Indian patient and literature review. *Journal of oral biology and craniofacial research.* 2015;;5(2):98-101.
 13. Hegde K, Puthran RM, Nair G, Nair PP. Ellis van Creveld syndrome—a report of two siblings. *Case Reports.* 2011, 14.
 14. Baby TK, Pillai RK, Bindhu PR, Thomas P. Ellis-van Creveld Syndrome: A Case Report of Two Brothers. *Oral Maxillofac Pathol J* 2016;7(1):698–701.
 15. Gokulraj S, Mohan N, Raj JB, Ahamed SY, Arokiaaraj CS, Subbulakshmi AC. Ellis–Van Creveld syndrome in siblings: A rare case report. *Journal of pharmacy & bioallied sciences* 2016;8(Suppl 1):S179.
 16. Jenkins S, DS M. Ellis-van Creveld syndrome: case report and review of the literature. *Cutis.* 2009;83(6):303–5.
 17. Katti S, Oswal P, Vas A. Ellis–van creveld syndrome: A rare case report. *Journal of Interdisciplinary Dentistry.* 2019;9(1):35.
 18. Kurian K, Shanmugam S, Harshvardhan T, Gupta S. Chondroectodermal dysplasia (Ellis van Creveld syndrome): a report of three cases with review of literature. *Indian Journal of Dental Research.* 2007;18(1):31.
 19. MERİÇ E. Oral Manifestations in Ellis-van Creveld Syndrome–A Rare Case Report and a Literature Review. *Academic Studies in Health Sciences-II.* :217.
 20. Shah B, Ashok L, Sujatha GP. Ellis-van Creveld syndrome: A case report. *Journal of Indian Society of Pedodontics and Preventive Dentistry* 2008;26(5):19.
 21. Shaik S, Raviraj J, Dirasantchu S, Venkata SS. Ellis–van Creveld syndrome with unusual oral and dental findings: A rare clinical entity. *Dental research journal.* 2016;13(2):193.
 22. Thapa R, Mukhopadhyay M, Bhattacharya A. Discordance for Ellis-van Creveld syndrome in twins. *Singapore Med J* 2008;49(12):e369-371.
 23. Aminabadi NA, Ebrahimi A, Oskouei SG. Chondroectodermal dysplasia (Ellis-van Creveld syndrome): a case report. *Journal of oral science* 2010;52(2):333-6.
 24. Naqash TA, Alshahrani I, Simasetha S. Ellis-van Creveld Syndrome: a rare clinical report of oral rehabilitation by interdisciplinary approach. *Case reports in dentistry.* 2018, 23.
 25. Weiner DS, Jonah D, Leighley B, Dicintio MS, Holmes Morton D, Kopits S. Orthopaedic manifestations of chondroectodermal dysplasia: the Ellis–van Creveld syndrome. *Journal of children’s orthopaedics* 2013;7(6):465–476.
 26. Gupta R, Khanna S, Luthra M, Mehta Y. Ellis–van creveld syndrome and its anesthetic implications. In: *The Indian Anaesthetists Forum.* Medknow Publications 2018, 85.
 27. Shilpy S, Nikhil M, Samir D. Ellis van Creveld syndrome. *Journal of Indian Society of Pedodontics and Preventive Dentistry* 2007;25(5):5.
 28. Bhat YJ, Baba AN, Manzoor S, Qayoom S, Javed S, Ajaz H. Ellis-van Creveld syndrome with facial hemiatrophy. *Indian Journal of Dermatology, Venereology, and Leprology* 2010;76(3):266.
 29. Picci-Sparascio F, Palencia-Campos A, Soto-Bielicka P, Danzi A, Guida V, Rosati J *et al.* Common atrium/atrioventricular canal defect and postaxial polydactyly: a mild clinical subtype of Ellis-van Creveld syndrome caused by hypomorphic mutations in the EVC gene. *Human Mutation.* 2020.
 30. Rajendra K, Ramamurthy TK, Gopikrishna K, Reddy GR, Srinivas K, Patil S. Ellis-van Creveld syndrome. *Journal of Indian Academy of Oral Medicine and Radiology* 2010;22(1):70.
 31. Cesur Y, Yuca SA, Uner A, Yuca K, Arslan D. Ellis-Van Creveldsyndrome. *Eur J Gen Med* 2008;5(3):187-90.
 32. Paranaíba LMR, Fernandes CM, de Aquino SN, dos Santos LAN, Martelli-Júnior H. Ellis- van Creveld syndrome: systemic and oral findings. *Scientia Medica* 2012.
 33. Scurlock D, Ostler D, Nguyen A, Wahed A. Ellis-van Creveld syndrome and dyserythropoiesis. *Arch Pathol Lab Med* 2005;129(5):680–2.
 34. Babaji P. Oral abnormalities in the Ellis-van Creveld syndrome. *Indian Journal of Dental Research* 2010;21(1):143.
 35. Kamal R, Dahiya P, Kaur S, Bhardwaj R, Chaudhary K. Ellis-van Creveld syndrome: A rare clinical entity. *Journal of oral and maxillofacial pathology: JOMFP* 2013;17(1):132.
 36. Nammalwar RB, Ahmed S, Aparna MV, Ravi VC. Oral Rehabilitation of a child with Chondroectodermal dysplasia (Ellis-van Creveld Syndrome)-A case report. *International Journal of Contemporary Dentistry* 2010;1(3).
 37. SANEEIFARD H, AMIR HG. Ellis van Creveld syndrome: report of a case and brief literature review. 2008;75-78.
 38. Aim A. Oral and craniofacial manifestations of Ellis-Van creveld syndrome: a systematic. *European journal of paediatric dentistry* 2019;20:306.
 39. Pinna R, Cocco F, Campus G, Conti G, Milia E, Sardella A *et al.* Genetic and developmental disorders of the oral mucosa: Epidemiology; molecular mechanisms; diagnostic criteria; management. *Periodontol* 2019;80(1):12–27.
 40. Fernández-Meré LA, Alvarez-Blanco M, Jorge-García J, Martínez-Suárez MA. [Anesthesia in a patient with Ellis-van Creveld syndrome]. *Rev Esp Anestesiología Reanim* 2010;57(8):528–31.
 41. Defendi GL. Ellis-van Creveld Syndrome: Practice Essentials, Pathophysiology, Epidemiology 2019.
 42. Ellis-van Creveld Syndrome: Practice Essentials, Pathophysiology, Epidemiology 2019.
 43. Vona B, Maroofian R, Mendiratta G, Croken M, Peng S, Ye X *et al.* Dual Diagnosis of Ellis-van Creveld Syndrome and Hearing Loss in a Consanguineous Family. *Mol Syndromol* 2017;9(1):5–14.