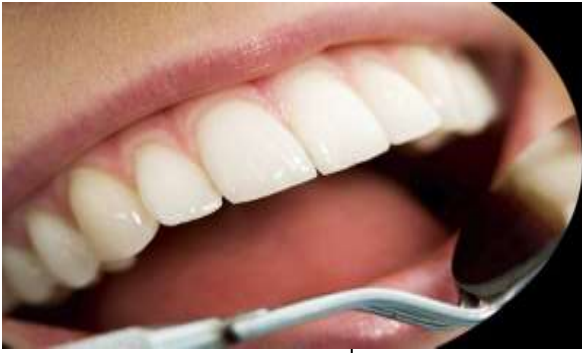



ISSN Print: 2394-7489
ISSN Online: 2394-7497
IJADS 2021; 7(2): 306-309
© 2021 IJADS
www.oraljournal.com
Received: 25-01-2021
Accepted: 16-03-2021

Dr. Ritika Gupta
Senior Lecturer, Department of
Prosthodontics Crown and
Bridge, Indraprastha Dental
College and Hospital, Sahibabad,
Ghaziabad, Uttar Pradesh, India

Dr. Trupti Dahane
Associate Professor, Department
of Prosthodontics Crown and
Bridge, Sharad Pawar Dental
College, Sawangi (M), Wardha
Maharashtra, India

Dr. Rasika Jhibkate
Consultant Prosthodontics,
Department of Prosthodontics
Crown and Bridge, Sharad
Pawar Dental College, Sawangi
(M), Wardha Maharashtra, India

Corresponding Author
Dr. Ritika Gupta
Senior Lecturer, Department of
Dental, Sharad Pawar Dental
College, Sawangi (M), Wardha
Maharashtra, India

Functional and esthetic ocular prosthesis: A case report

Dr. Ritika Gupta, Dr. Trupti Dahane and Dr. Rasika Jhibkate

DOI: <https://doi.org/10.22271/oral.2021.v7.i2e.1224>

Abstract

An ocular prosthesis is an artificial eye that replaces the natural eye following an enucleation, evisceration, or orbital exenteration. This maxillofacial prosthesis also boosts the lost social and mental well being of a patient. But, the success of any prosthesis depends upon various factors mainly on the functional recording of the tissue bed the anophthalmus eye. In this case report, a combination of impression technique and procedure is followed to achieve a stable and retentive ocular prosthesis.

Keywords: Ocular prosthesis, tissue conditioner, custom-made prosthesis

Introduction

“Love of life is next to the love of our face thus the mutilated cry out for help” - Sushruta^[1].

In this aesthetic oriented world, facial beauty is very important, where face being the physical basis of a person for personal recognition. Thus, any disfigurement in the face can cause a deep psychological and social impact on one's^[2, 3]. Loss of tissue, whether congenital, traumatic, or resulting from malignancy or radical surgery, this loss is even more pronounced when the affected parts are facial structures like ears, nose, eyes, and their orbital contents which results in gross mutilation. A maxillofacial prosthesis should be given for the well-being of the patient^[3, 4].

Eyes are the most precious gift given to humans. A person communicates to the outer world with vision, consciousness, way of expression, and dignity by eyes. Loss of eye is a misfortune to a person because, as it is one of the most important sensory organs. This sensory loss not only alters facial appearance but also results in emotional and psychological trauma to a sufferer^[2, 4]. “Maxillofacial prosthesis is defined as the art and science of anatomic, functional or cosmetic reconstructions carried out by means of non-living substitutes of those regions in the maxilla, mandible, face and even other body parts that are missing or defective because of surgical interventions, trauma, pathology or developmental or congenital malformations”^[5]. Ocular prosthesis rehabilitation means prosthesis that artificially replaces an eye missing as a result of trauma, surgery, or congenital absence^[5]. The goal of an ophthalmic socket is to restore facial esthetics, prevent eyelid collapse and deformity, protect the socket against injuries, re-establish the correct route of the lacrimal secretion^[6].

Prosthetic rehabilitation can be done either with stock eye prosthesis (prefabricated) or custom-made ocular prosthesis. Stock ocular prosthesis available in standard sizes, shapes, and colors. They can be used for interim or postoperative purposes. Custom eyes have several advantages compared to stock ocular prosthesis like the better movement of eyelids, distribution of pressure enhanced fit, comfortable, and adaptation improved facial contours, and enhanced esthetics gained from the control over the size of the iris, pupil, and color of the iris and sclera^[7, 8].

This article describes a newer technique of fabrication of ocular prosthesis by the use and combination of the stock eye and its further customization.

‘Rehabilitate: To restore to good condition or to restore to former privilege’

Case report

A 22-year-old female patient (Fig. 1) was referred to the department of prosthodontic crown and bridge, Sharad Pawar Dental College, Sawangi (M), Wardha; from the department of ophthalmology, Datta Meghe Institute of Medical science, Wardha; with an ocular defect caused by the enucleation of the eye; involves the removal of the eye, including the globe, but leaving the rest of the orbital contents in place. In the right eye [10]. The case history revealed that the patient had reported to the ophthalmology department of DMIMS, Wardha with a complaint of pain and continuous watering from the right eye and a history of trauma 4 years back. On further examination of the symptoms by the ophthalmologist, it was decided to enucleate the eyeball, the patient was given a stock eye for later so that the muscles and tissues of the socket heal accordingly and do not collapse.

After 6 months from the surgery, the patient was sent to our department to rehabilitate the ocular defect as she was not satisfied with the appearance. On examination (Fig. 1), the tissue bed in the ocular cavity was completely healed with good mobility of the posterior wall. The upper and lower eyelids were also examined in both open and closed positions for any abnormality, but there was no damage. Since we had a very short period as the patient had to leave the next day we planned to give her an ocular prosthesis with the same day by customizing the stock eye after proper shade matching of the iris with the contralateral eye.

Petroleum jelly was applied to the eyebrows and surrounding skin to prevent impression material from sticking to eyelashes. The primary impression was recorded with a fluid viscosity irreversible hydrocolloid impression material (Alginate, Zelgan: DPI) loaded in a syringe (Fig. 2). Care was taken so that no air was incorporated in the impression material during the impression procedure. While inserting the material in the patient's defect, the patient is asked to look straight to the front. Once the material has been introduced, the patient is asked to perform eye movements so that the impression is recorded in a functional form (Fig. 3)

- Up and down movements
- Circular movements of the eye [7, 8].

The material had set, the impression was retrieved and ensured that all the surfaces were recorded. The cast was poured in dental stone type IV with the "Two Pour Technique", the two halves of the casts were separated after the complete set of the dental stone and the impression was retrieved, creating a mold space. Indexing was done on all the four sides of the cast for proper reorientation of the cast and separating media was applied to the mold space. With the help of this mold, an acrylic custom tray was prepared for a more accurate functional impression of the defect using elastomeric impression material. Impression was again recorded in a functional form (Fig. 4). The impression so obtained was poured in type IV dental stone and once set was stabilized by a putty index (Fig. 5).

Next, the wax pattern was fabricated by pouring the molten wax into the impression. The wax was properly contoured and carved to give it a simulation of the lost eye. The wax pattern was tried in the patient's socket and checked for size, comfort, support, fullness, and retention by performing the functional eye movements which included the closure of the eyelid and moving in upward and downward direction as well as right and left movement.

The size and shade for the iris portion were done matching it to the contralateral iris, after the complete match the iris

portion was trimmed from the selected stock eye.

The iris positioning was done by a transparent grid method the patient to sit straight with his head erect. The patient was asked to gaze straight at an object kept 4 feet away. The operator then marked the vertical lines coinciding with the medial and distal extremities of the iris of the natural eye. Similarly, horizontal lines referring to the center, the inferior and superior limits of the iris were marked. The facial markings were transferred to the grid template by placing it on the patient's face. These markings were transported to the side of the defect. These markings were transferred to the sculptured wax pattern and the iris button attached to it (Fig. 6).

Now the wax pattern was gently removed and cleaned, tissue relining is done with tissue conditioner, the objective was to obtain complete peripheral contact and proper curvature of the tissue bed. After the relining, the wax pattern was sealed and the whole was processed. An acrylic handle was attached to the iris to prevent the displacement of the iris during dewaxing (Fig. 7).

Packing of the selected clear acrylic resin material (Trevelon: Dentsply) is done in the mold. The first layer is packed in clear acrylic resin (Trevelon: Dentsply) in which the Rayon or silk thread fibrils are incorporated to replicate the blood vessels. Then the selected scleral colored acrylic resin is packed over the clear acrylic. Then final prosthesis is finished and polished to provide maximum adaptation and overall success of the prosthesis (Fig. 8, 9).

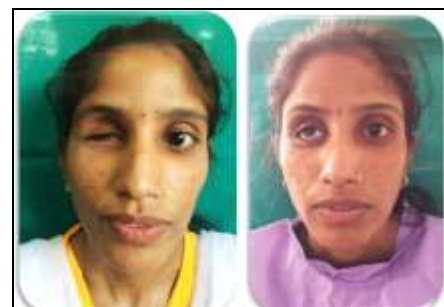

Fig 1: Pre-Operative with and without stock eye.

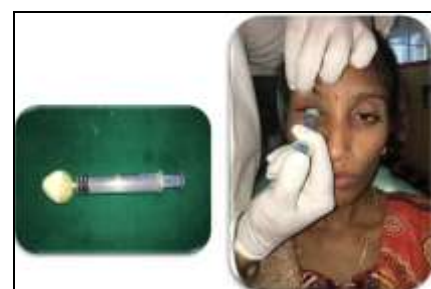

Fig 2, 3: Primary impression of the socket bed Hydrocolloid Impression. Recording in Functional Form.

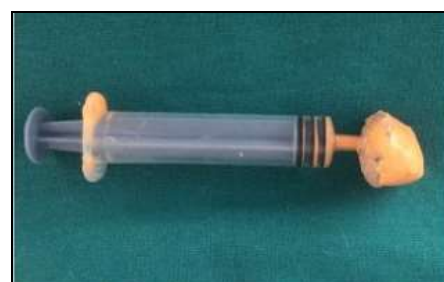

Fig 4: Final impression recorded using custom made shellac.

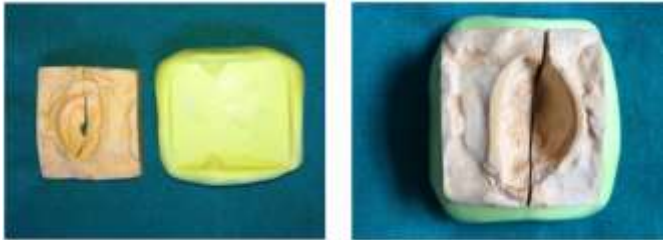


Fig 5: Final Cast using Type IV dental stone stabilized by putty index.



Fig 6: Wax Blank trial and Iris Positioning using Grid Method.



Fig 7: Wax pattern ready for flasking, stabilized by acrylic hold.

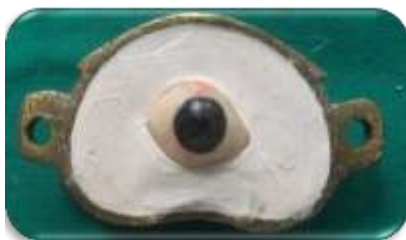

Fig 8: Final Eye Prosthesis after processing and characterization.

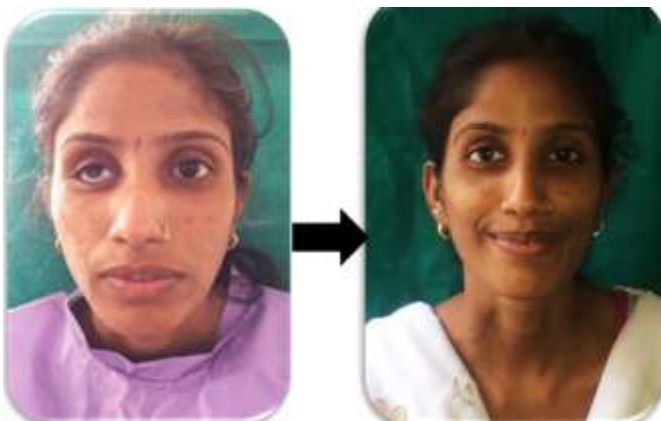

Fig 9: Pre-Operative Picture and Post-Operative Picture of the patient.

Post-Operative Instructions ^[11]

- The patient was taught about how to insert and remove the prosthesis.
- The prosthesis should be removed at least once a day and washed properly.
- The prosthesis should be stored in the water when not in use.
- To clean your prosthesis, use antibacterial soap. Wash the eye between your fingertips.
- If you wish to or need to rinse out the socket, use sterile saline with a bulb syringe.
- And to keep regular follow ups every 6 months.
- Keep a habit to clean your eye socket as well, with cold water, and use artificial tear drops to keep the eyes moist.

Discussion

Ocular defects can be either acquired defects like irreparable trauma, painful blind eye, tumors, etc. or congenital defects like microphthalmia or anophthalmia. A prosthetic rehabilitation fulfills the esthetic as well as the psychological requirement of the patient ^[4-6].

An aesthetically and functionally well-made ocular prosthesis should maintain its orientation when the patient performs various movements; looking straight ahead and it should restore the normal opening of the eye, support an eyelid and restore a degree of movement. And for this a custom-made eye prosthesis is best to full fill the requisites of the lost eye. The advantages of the custom-made eye are; Improved adaptation to underlying tissues, increase mobility of the prosthesis, Enhance esthetics ^[9-10]. The stability, success, and effectiveness of the eye prosthesis depend upon various factors like impression material and technique, space for prosthesis, equipment, operator experience, and mainly patient physiology, in which the type of material and technique used are the most important ones ^[9-12].

The impression material used in this case was using elastomeric impression material and future using tissue conditioner over the wax pattern fabricated for better adaptation, proven to be very good & satisfactory in the rehabilitation of the ophthalmic patients. This technique also helps in correct and closely adaptation of ocular prosthesis to the remaining substructure, globe, and muscle tissue, which ultimately help in less risk of microorganism and secretion to be accumulated in the defect ^[13-15].

Summary

Defects of the eye may follow the removal of a part of or the entire orbit. This results in the patient becoming visually, esthetically, and psychologically handicapped. Restoring the defect with a custom-made prosthesis not only restores esthetics but also gives back the lost confidence to the patient.

References

1. Padmaja S. An insight into the future beckons of maxillofacial prosthodontics: Anaplastology. *Journal of Dental Research and Review* 2.2, 2015, 91-96.
2. Nikhil Srivastava, Preetika Goyal. Palatal Obturator: An Update. *EC Dental Science* 9.3, 2017, 124-127.
3. Taylor T. *Clinical Maxillofacial Prosthetics*, Quintessence, Chicago, Ill, USA, 2000.
4. Bali N, Dhall RS, Singh N. Various Steps Involved in Fabrication of an Ocular Prosthesis: A Case Report. *Int J Dent Med Res* 2015;1(5):93-96.
5. Glossary of Prosthodontic terms-9.
6. Modified ocular prosthesis impression technique. Robert

- L. Schneider, Beume, JPD, 1986.
7. Hooper SM, Westcott T, Evans PLL, *et al.* Implant-supported facial prosthesis provided by a maxillofacial unit in a UK regional hospital: longevity and patient opinions. *J Prosthodont*, 2005;14:32-38.
 8. Beumer J, Zlotolow I. Restoration of facial defects, in *Maxillofacial Rehabilitation - Prosthodontic and Surgical Considerations*, Beumer, Ed. Mosby, St. Louis, Mo, USA, 1996, 350-364.
 9. Artopoulou II, Montgomery PC, Wesley PJ, Lemon JC. Digital imaging in the fabrication of ocular prostheses, *Journal of Prosthetic Dentistry* 2006; 95(4):327-330.
 10. A simplified approach to rehabilitate an ocular defect: Ocular prosthesis, *JIPS*, 2016.
 11. Naeem ahmad, Aruna bhandari, Umesh pai. Prosthodontic management of a patient with an ocular defect, case reports, 2009.
 12. Sykes LM, Essop ARM, Veres EM. Use of custom-made conformers in the treatment of ocular defects. *J Prosthet Dent* 1999;82:362-365.
 13. Shenoy, *et al.* Ocular impressions: An overview. *The Journal of Indian Prosthodontic Society* 2007;7(1).
 14. Ow RK, Amrith S. Ocular Prosthetics: Use of tissue conditioner material to modify a stock eye prosthesis. *J Prosthet Dent* 1997;78:218-22.
 15. Skyes LM. Custom-made ocular prosthesis: A clinical report. *J Prosthet Dent* 1996;75:1-3.