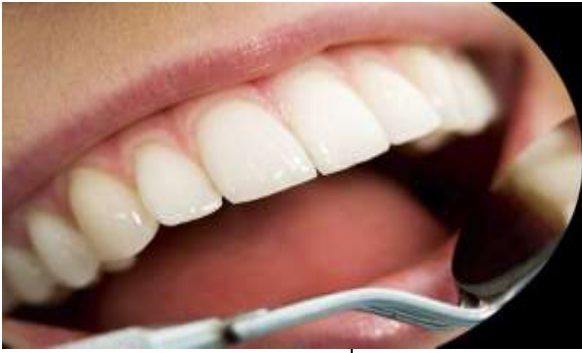



ISSN Print: 2394-7489
ISSN Online: 2394-7497
IJADS 2021; 7(2): 310-313
© 2021 IJADS
www.oraljournal.com
Received: 28-01-2021
Accepted: 18-03-2021

Dr. Kulkarni Shreeya P
PG Student, Department of
Prosthodontics and Crown and
Bridge, Tatyasaheb Kore Dental
College and Research Centre,
Maharashtra, India

Dr. Deshpande Abhijit S
Professor, Department of
Prosthodontics and Crown and
Bridge, Tatyasaheb Kore Dental
College and Research Centre,
Maharashtra, India

Dr. Angadi Gangadhar S
Professor and Head, Department
of Prosthodontics and Crown and
Bridge, Tatyasaheb Kore Dental
College and Research Centre,
Maharashtra, India

Corresponding Author:
Dr. Kulkarni Shreeya P
PG Student, Department of
Prosthodontics and Crown and
Bridge, Tatyasaheb Kore Dental
College and Research Centre,
Maharashtra, India

Andrew's bridge system: A suitable option for rehabilitation of compromised anterior dentition using preci-horix attachment

**Dr. Kulkarni Shreeya P, Dr. Deshpande Abhijit S and Dr. Angadi
Gangadhar S**

DOI: <https://doi.org/10.22271/oral.2021.v7.i2e.1225>

Abstract

Rehabilitation of a compromised anterior dentition when particularly there is a loss of a variable amount of residual ridge and adjacent soft tissue is difficult and unpredictable. In such cases to achieve a predictable treatment outcome, a fixed-removable partial denture system can be used wherein a removable prosthesis is retained by a bar and sleeve attachment to fixed retainers on the either side of the edentulous space. This system can also be used when the alignment of the opposing arches and/or esthetic arch position of the replacement teeth create difficulties for placement of a conventional fixed partial denture. This case report shows the fabrication of a fixed-removable partial denture using the Andrews Bridge philosophy to meet the requirements for esthetics, comfort, phonetics, hygiene, and favorable stress distribution to the abutments and soft tissue.

Keywords: Anterior ridge defect, fixed-removable system, preci- horix attachment

Introduction

A patient with several missing teeth in the anterior aesthetic region along with a ridge defect poses a greater challenge for prosthodontic rehabilitation. A removable partial denture is usually the treatment option for a long span edentulous space. But most of the patients demand a fixed prosthesis because of better aesthetics, better function and a psychological impact on their mind.

There are certain limitations for a fixed prosthesis especially when several teeth are missing, the remaining teeth in the dentition are periodontally compromised and some defects are present in the edentulous region. In such clinical scenarios, it can be better to select a combination of fixed partial prosthesis and removable partial prosthesis, which can combine the benefits of both the prosthesis ultimately restoring the patient's functions and esthetics.

The fixed partial denture-removable partial denture system was introduced by Dr James Andrews of Amite, Louisiana, USA in 1965, when fixed or removable partial dentures were not successful in treating ridge defects^[1, 2]. It consists of a fixed component (Porcelain fused to metal Ceramic Retainers on the abutment teeth joined by a bar) and a removable pontic component (removable partial denture having attachments or sleeves to fit on the bar). This technique has the advantage of flexibility in arranging the removable partial denture teeth with minimum extension along with better retention and stability^[3].

The case reports describes a case having multiple missing anterior teeth along with ridge defect, which was restored successfully by using fixed-removable Andrews's bridge system using Preci-Horix Attachment.

Case Report

A 51-year-old female patient reported to the department of Prosthodontics and Crown & Bridge at Tatyasaheb Kore Dental College. Her chief complaint was of missing anterior teeth and unesthetic appearance. Past Dental History revealed that she had a previously fabricated foxed dental prosthesis with teeth 11, 12, 13, and 21.

But there was a failure of the prosthesis due to caries and mobility of the abutment teeth and hence the abutment teeth 13 and 21 were extracted 5 months back. She had a previous PFM Crown on 14 which had porcelain chipped off exposing the metal which had to be replaced. Seibert's class 2 defect was seen with the edentulous ridge. Andrews bridge system was selected as the best fixed-removable prosthesis for this case to achieve optimum function and esthetics and to avoid coverage of the palate by a completely removable prosthesis.

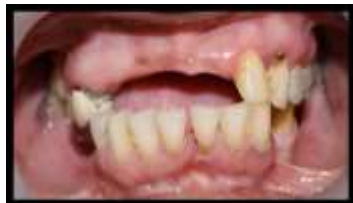

Fig 1: Pre-operative View

2.1 Treatment Procedure

1. Radiographs of the abutment teeth (14, 22 and 23) were evaluated first. Treatment started with the removal of the old PFM crown on 14 to be replaced by a new crown since it was endodontically treated and the endodontic treatment was satisfactory. There was evidence of a carious lesion with 23 which was restored with composite restoration.
2. The selected abutment teeth were prepared for receiving metal ceramic crowns. Tooth preparation and Gingival Retraction was done. (Fig. 2)

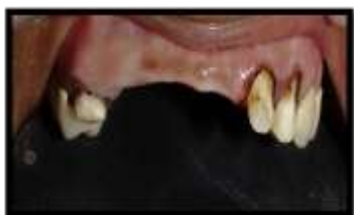

Fig 2: Tooth Preparation with 14, 22, 23

3. Impressions were made using the putty wash impression technique using poly-vinyl siloxane impression material and master casts were poured in Type IV Gypsum Product.
4. Wax Patterns were fabricated on the prepared abutment teeth and were connected using prefabricated castable plastic bar attachment (Ceka Preci Horix). (Fig.3). The bar was bent into two sections to follow the edentulous residual ridge curvature and was positioned on the palatal aspect of the retainers. The bar was placed such that 2-3 mm of space was left between the bar and the crest of the alveolar ridge to facilitate maintenance of oral hygiene by the patient. (Fig. 4).



Fig 3: Ceka Preci-Horix Attachment

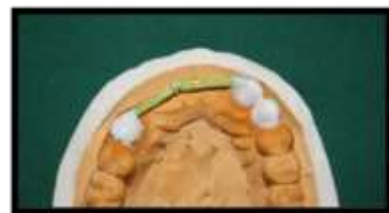

Fig 4: Wax Pattern for casting

5. This entire assembly was then cast in chrome cobalt alloy. The finished and polished metal framework was tried in the patient's mouth for proper fit and clearance between the bar and underlying soft tissues. (Fig. 5).

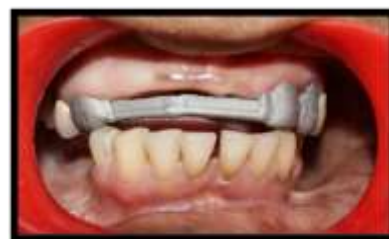

Fig 5: Metal Trial

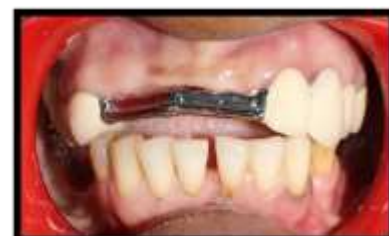

Fig 6: Fixed Retainers with the Bar

6. Shade selection was done for the ceramic and acrylic teeth. Ceramic layering was done on the retainers 14,22 and 23. The final fixed part of the prosthetic assembly (retainers joint by the bar) was polished and then cemented in the patients mouth with Type I GIC luting agent. (Fig. 6)
7. An impression was taken post cementation with polyvinyl siloxane and final cast was obtained for the fabrication of the removable part of the prosthesis. (Fig. 7)

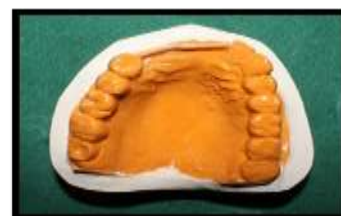

Fig 7: Final Cast

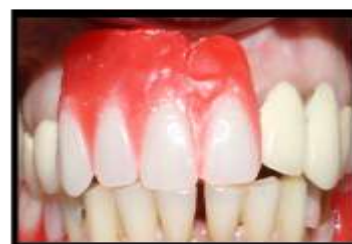

Fig 8: Try-in of the Removable Component

8. The missing teeth were arranged on the wax occlusal rim fabricated on to the edentulous area of the cast and tried for aesthetic approval by the patient. (Fig. 8)
9. The next step was the fabrication of the removable part of Andrew's bridge. Adequate Wax up was done followed by flasking of the prosthesis was done using dental plaster (Figure 9).



Fig 9: Flasking

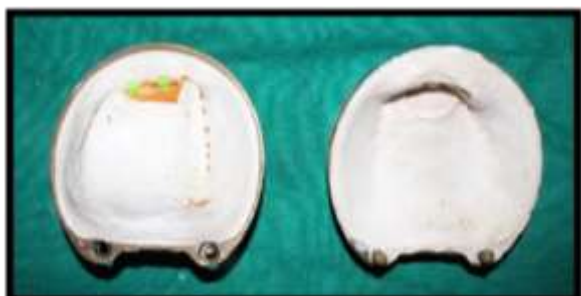

Fig 10: Placement of plastic green clips during processing

After dewaxing, the plastic green clips provided in the Preci-horix Attachment kit were placed on the bar at appropriate positions. These clips were used to create space for the pickup of the metal housing and plastic yellow retentive sleeves in the final denture.(Fig.10).The mould space was then packed with heat cured polymethylmethacrylate (PMMA) resin (Dental Products of India DPI,) and polymerized. After completion of polymerization, the green plastic clips were carefully teased out from the intaglio surface of the prosthesis. The prosthesis was finished and polished.

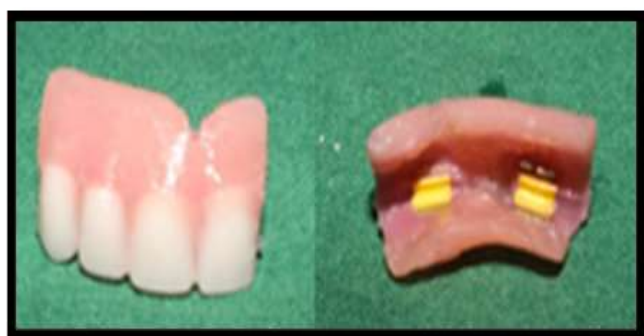


Fig 11: Final Prosthesis-Polished and Intaglio surface after Pickup of yellow retentive sleeves

10. The metal housing and yellow retentive sleeves were placed on the bar intraorally at the appropriate position to be picked up in the final prosthesis. A thin layer of self polymerizing acrylic resin was mixed and applied on the intaglio surface of the denture and the retentive sleeves were picked up.

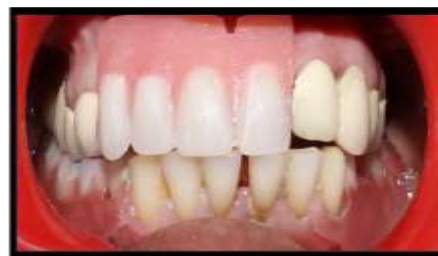

Fig 12: Post-operative Frontal View

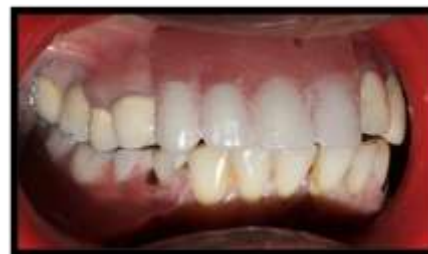

Fig 13: Post-operative Lateral View

11. The patient was trained to properly insert and remove the RPD fabricated over the fixed component of Andrew's Bridge and proper oral hygiene (including interdental brush) instructions were given to the patient. The patient was scheduled for follow-up visits every 3 months.

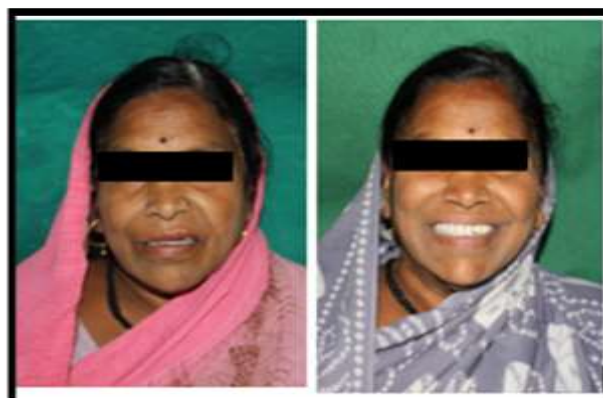

Fig 14: Pre and Post-operative Extraoral View

Discussion

There are a lot of clinical scenarios where following the extraction of teeth, there is a presence of residual ridge defect and a compromised condition of adjacent abutment teeth. The most commonly seen defects are the combined Class III defects (56% of cases), followed by horizontal defects Class I (33 % of the cases) whereas vertical defects were reported to be found in 3% of the patients [4]. Complete closure of the defect can be treated with conventional removable or fixed partial denture but may restore either esthetics or function but not both. Also surgical closure of these defects using bone grafts and then replacing the missing teeth with implants can be an option but it is an expensive treatment plan for some patients and can pose a clinical challenge to the dentist. In such cases, Andrew's fixed-removable system is a commendable alternative for treating the anterior ridge defects [5].

Andrews bridge system is a fixed removable type of prosthesis wherein a removable partial denture of gingival colored acrylic resin and acrylic denture teeth for the missing dentition clips over a bar which connects the PFM retainer

over the abutment teeth. Depending upon the length of the edentulous span, ridge form and interocclusal space available, the length and curvature of the bar is decided. It is indicated in cases with Several missing teeth along with defect in the ridge, Failure of removable partial denture because of discomfort related to its palatal extension, long edentulous space where fixed partial denture has not succeeded, cleft palate patients^[6].

The advantages of using Andrews bridge system are

- Andrews Bridge has both fixed and removable properties hence it provides maximum esthetics and optimum phonetics in cases where there is considerable tissue loss of the supporting tissues, jaw defects like cleft palate^[7] and when the alignment of the opposing arches create difficulties for the replacement teeth.
- The removable part of the prosthesis can be easily removed and reattached by the patient thus helping the patient to maintain hygiene around the abutments and under the bar.
- It is a tooth borne Removable prosthesis having good stability where the occlusal forces are directed more along the long axis of the abutment teeth.
- The acrylic denture flange is an added advantage as it does not require a separate prosthesis for the gingival defect as in the Fixed dental prosthesis.
- There are reduced chances of gag reflex and a normal perception of taste is maintained as the prosthesis flange does not extend palatally for support.

There are various retentive systems used for Andrews bridge system. There are case reports of using a coffee straw for the retentive bar element^[8]. Magnets can also be used instead of the bar and sleeve attachment^[9]. This case report describes the use of Ceka Preci-Horix attachment for the fabrication of the bar and sleeve retentive system. It consists of plastic castable bar attachment connected to the abutment teeth and casted along with it in a single piece thus minimizing chances of fracture. The metal housing and yellow retentive sleeves provide an excellent precision retentive fit to the prosthesis. The disadvantage of this system includes the need to frequently remove the prosthesis for cleaning and the associated loss of retention of the clips^[10].

Conclusion

When conventional treatments are not feasible there is always an option to consider Andrew's bridge which permits rehabilitation of congenital and acquired defects by effectively restoring the esthetics and speech by replacing the missing teeth. It has the advantages of both fixed and removable components. Preci-Horix attachment provided a very predictable precision fit for the retention of this fixed-removable prosthesis.

Funding: This case report did not receive any financial support.

Conflict of interest: None declared.

References

1. Andrew JA, Bigg WF. Andrew's bar and sleeve retained bridge: a clinical case report. *Dent Today* 1999;18:94-6, 98-9.
2. Andrews JA. *The Andrew's Bridge: A Clinical Guide*. Covington, LA: Institute of Cosmetic Dentistry 1976;3:7.

3. Tambe A, Patil SB, Bhat S *et al*. *BMJ Case Rep* 2014. doi:10.1136/bcr-2014- 203988.
4. Bhapkar P, Botre A, Menon P, Gubrellay P. Andrew's Bridge System: An Esthetic Option. *J Dent Allied Sci* 2015;4:36-40.
5. Ashish R Jain *et al*. *J Pharm. Sci. & Res* 2016;8(9):1045-1049
6. Soni R, Yadav H, Kumar V. Andrew's bridge system: A boon for huge ridge defect in aesthetic zone. *J Oral Biol Craniofac Res.* 2020;10(2):138-140. doi:10.1016/j.jobcr.2020.03.009
7. Chaudhary R, Kumar D, Khattak A, Yadav RK, Gopi A, *et al*. (2020) Prosthodontic Rehabilitation of a Cleft Patient with Andrews Bridge: A Case Report. *Int J Oral Dent Health* 6:107. doi.org/10.23937/2469-5734/1510107
8. Dr Tanvi Thaper. Restoring Anterior Aesthetics with Andrews Bridge Using a Coffee Straw. A Case Report. *IOSR Journal of Dental and Medical Sciences (IOSR-JDMS)* 2018;17(5):58-6.
9. Rathee M, Sikka N, Jindal S, Kaushik A. Prosthetic rehabilitation of severe Siebert's Class III defect with modified Andrews bridge system. *Contemp Clin Dent* 2015;6(S1):114-6.
10. Gopi A, Sahoo NK. Andrews Bridge: A fixed removable prosthesis, *J Pierre Fauchard Acad (India Sect)* 2016. <http://dx.doi.org/10.1016/j.jpfa.2016.10.002>