



ISSN Print: 2394-7489
ISSN Online: 2394-7497
IJADS 2021; 7(2): 361-365
© 2021 IJADS
www.oraljournal.com
Received: 04-02-2021
Accepted: 06-03-2021

Romal Shende
Post Graduate Student,
Department of Prosthodontics,
Government Dental College and
Hospital, Nagpur, Maharashtra,
India

Suryakant Deogade
Associate Professor, Department
of Prosthodontics, Government
Dental College and Hospital,
Nagpur, Maharashtra, India

Arun Khalikar
Professor and Head, Department
of Prosthodontics, Government
Dental College and Hospital,
Nagpur, Maharashtra, India

Sattyam Wankhade
Associate Professor, Department
of Prosthodontics, Government
Dental College and Hospital,
Nagpur, Maharashtra, India

Corresponding Author:
Romal Shende
Post Graduate Student,
Department of Prosthodontics,
Government Dental College and
Hospital, Nagpur, Maharashtra,
India

Rehabilitation of a partially edentulous patient with a bar-supported over-denture: A case report

Romal Shende, Suryakant Deogade, Arun Khalikar and Sattyam Wankhade

DOI: <https://doi.org/10.22271/oral.2021.v7.i2f.1231>

Abstract

Lack of stability and support from conventional complete denture is the persistent enigma of all times. Rehabilitation of such cases fail to please patients as well as it is distressing for dentist. Over denture on other hand has upper hand over conventional denture with respect to not only just stability and support but it also enhances the proprioception and lowers the rate of residual ridge resorption. Overdenture with a bar attachment splints the tooth together which causes even distribution of stresses. This case report dictates successful rehabilitation of a patient with the same concept applied clinically.

Keywords: rehabilitation, partially edentulous patient with, bar-supported over-denture

Introduction

In the advancing era of dentistry, with advancement in impression material and techniques and so many aspects blooming in the field, fabricating a perfectly stable and retentive denture for an edentulous jaw is still considered a tedious job for dentists. The task may turn even more cumbersome and challenging when the ridges are resorbed; this may further hamper the retention and stability of the prosthesis. This is especially true in cases of mandibular dentures since they rest on a dynamic foundation provided by the mandible and its association with the destabilizing effects of the tongue and other musculature^[1].

In many patients however, despite being candidates for a complete denture usually have few retained natural teeth. The tenets of Preventive prosthodontics suggest that any procedure that can delay or eliminate the inevitable extraction of the tooth/teeth must be emphasized. The presence of any remaining tooth can thus contribute towards additional support by acting as abutments for an over-denture that ensure less pressure on the basal seat and thus act towards preserving the alveolar bone volume^[2,3].

Moreover, it can be converted to a complete denture in due course. The most important advantage is that the patient has the psychological benefit of retaining his existing teeth which, outweighs all the disadvantages^[4].

Case report

A 63-year-old male patient reported to the Department of Prosthodontics with the chief complaint of difficulty in chewing food and poor facial appearance. Intraoral examination showed partially edentulous maxillary arch with firm 11 and 21, 22 and partially edentulous mandibular arch with firm 34, 43, 44, 48 (figure 1). Radiographic examination revealed good crown root ratio in the proposed abutments. In mandibular arch 43, 44 and in maxillary arch 11, 21, 22 were already endodontically treated (figure 2). The different treatment modalities available for this patient were conventional complete denture by extracting remaining teeth, implant and tooth-supported overdenture. The patient was not willing for extraction of remaining teeth. Following this desires of patient and treatment needs, it was planned to save and harness the remaining teeth as abutments and fabricate a single complete denture with metal coping for maxillary partially edentulous arch and bar-supported overdenture for partially edentulous mandibular arch owing to the obvious advantages.

Prior to initiating prosthetic treatment, Oral prophylaxis and intentional endodontic treatment was done for the remaining teeth. Diagnostic models were mounted on a semi-adjustable

articulator (for tentative jaw relations). This was performed to verify the interocclusal space, and it was found to be adequate and satisfactory for bar attachments.

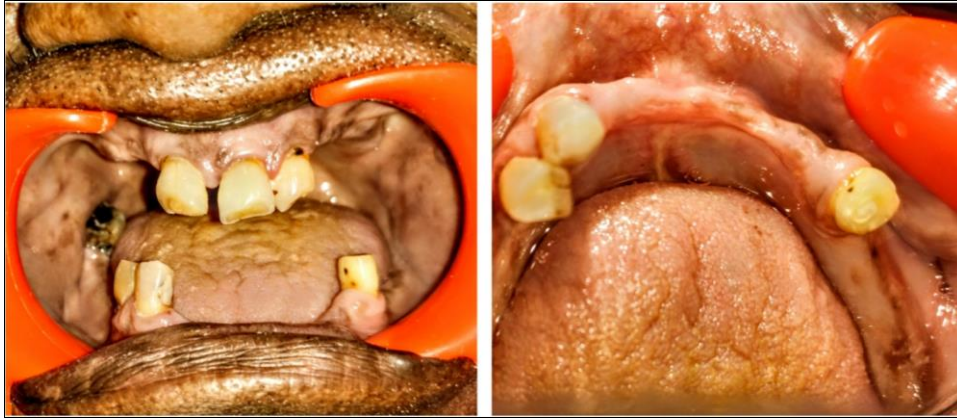

Fig 1: Pre-operative intra-oral photographs

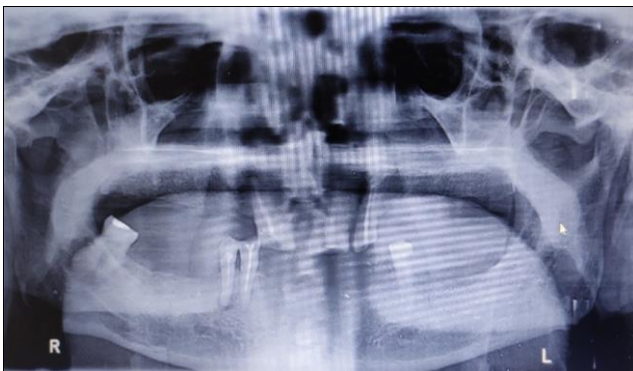


Fig 2: Pre-operative radiograph

Clinical procedure for mandibular arch

The tooth preparation was done with heavy chamfer finish line to receive copings and intra-coronal post space preparation was done so as to have extensions of the bar in the tooth structure. Custom post patterns were fabricated with auto-polymerizing resin (Pattern resin) and a pick-up impression was made using rubber base impression (figure 3). The impression was poured with die stone (Type IV die stone). Post-coping patterns was fabricated in the laboratory. Inlay casting wax was used to fabricate copings and bar on the mandibular teeth (figure 4A). The wax pattern was cast by using standard technique. The metal bar with retainer copings were tried first on the cast and then intraorally to check for the passive fit of the bar and coping (figure 4B). The bar along

with the metal copings, were cemented on to the respective tooth preparations with the help of Resin cement (figure 5A). A primary impression of the lower arch was made with irreversible hydrocolloid material and a custom tray was fabricated on the primary cast after block out. Using conventional techniques, border moulding was done and wash impression was made with low viscosity rubber base material (figure 5B). Record rims were made and jaw relation recorded using Face bow transfer which it is transferred to the semi adjustable articulator. Teeth arrangement was done and a try-in was accomplished (figure 6). After a satisfactory trial, the waxed up denture was processed following the conventional Compression Moulding method. On the day of prosthesis delivery, the yellow (medium retention) plastic clips were secured over the bar. The mandibular denture was positioned over the bar and the spot was marked and cut using acrylic trimming burs to house the plastic clip. The undercut of the bar was then blocked. Cold cure acrylic was mixed and placed in the tissue surface of the denture in the trimmed area. Separating medium was applied on the bar and on the blocked out region. The mandibular denture was then placed followed by the maxillary denture in the mouth and the patient was asked to close in centric relation. After 10 minutes the denture was removed along with the retention clip picked up in the denture. Excess acrylic was trimmed and the tissue surface was polished using finishing burs and sand paper (figure 7).

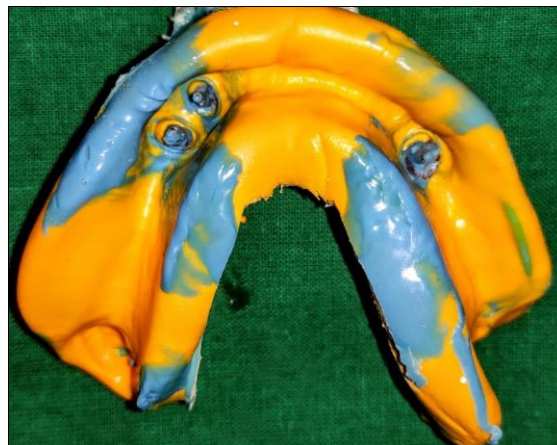

Fig 3: Pick-up impression

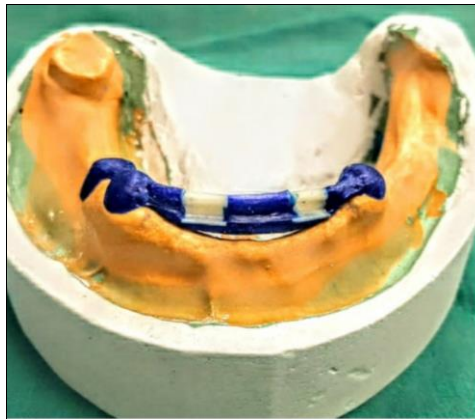


Fig 4a: Wax pattern

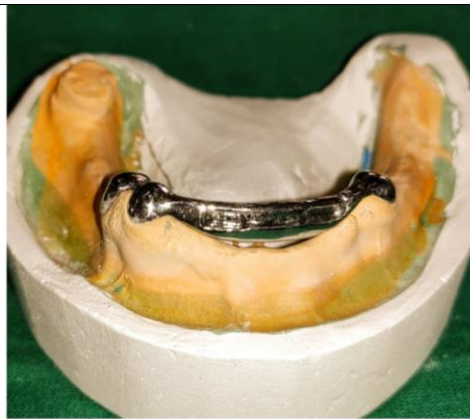

Fig 4b: Casting

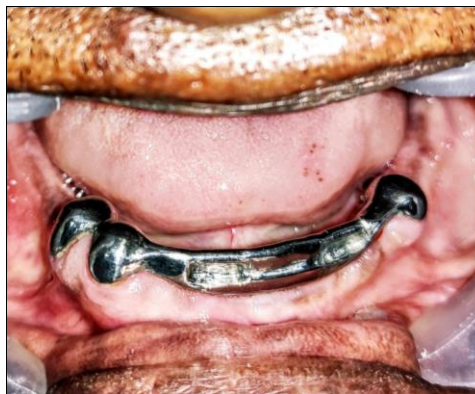

Fig 5a: Cementation of bar and copings

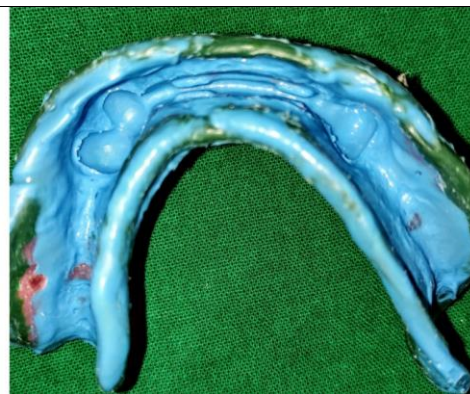

Fig 5b: Final impression

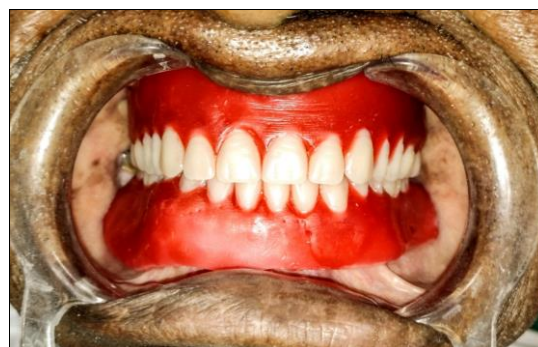

Fig 6: Try-in

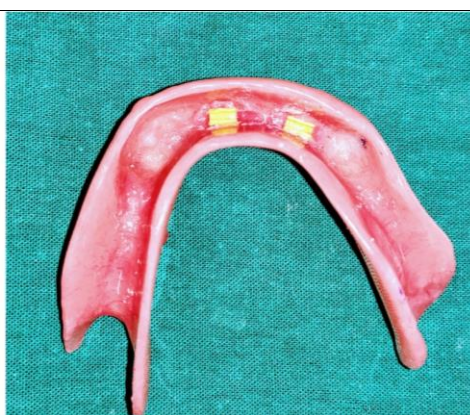
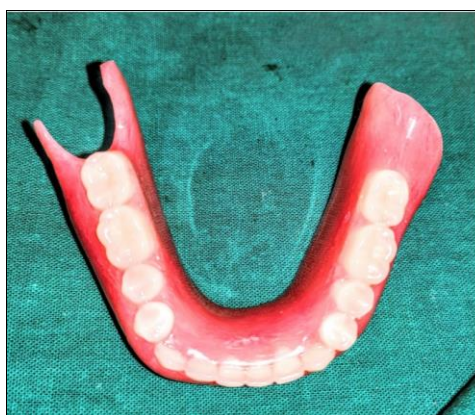
Fig 7: Final prosthesis with retentive clips

Clinical procedure for maxillary arch

The tooth preparation was done to receive copings. Impression of the prepared teeth was made with polyvinylsiloxane and subsequently poured to obtain a cast.

Inlay casting wax was used to fabricate pattern for coping over the prepared teeth (figure 8A). Metal copings were obtained by casting (figure 8B) and luted over the prepared teeth with resin cement (figure 9A). Final impression, with

coping was made using a custom tray (figure 9B). The jaw relation was recorded. Teeth arrangement and intra-oral trial was done. Maxillary complete denture was processed following the conventional Compression Moulding method (figure 10). The patient was trained for insertion and removal

of the prosthesis and post insertion instructions were given. The maintenance and importance of denture hygiene was explained in detail. Post insertion follow up visits were done at 1 day and 7 days. The patient was satisfied with the prosthesis (figure 11).

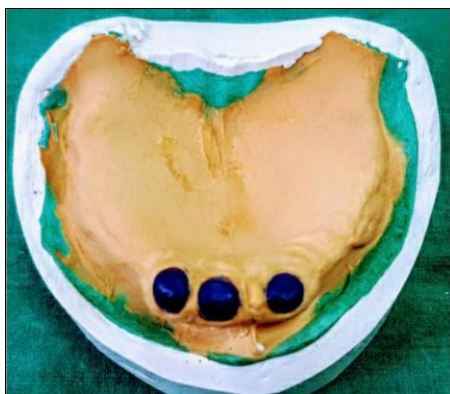

Fig 8a: Wax pattern for coping

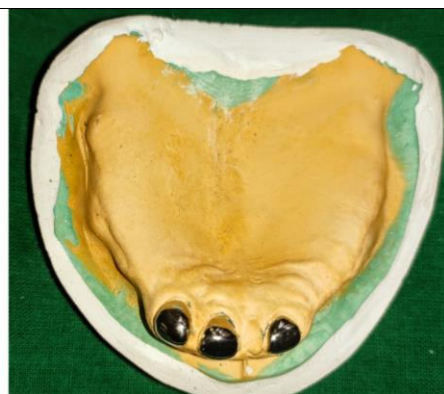

Fig 8b: Casted metal coping

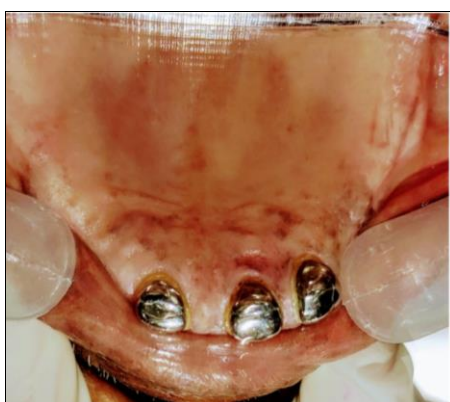

Fig 9a: Cementation of coping

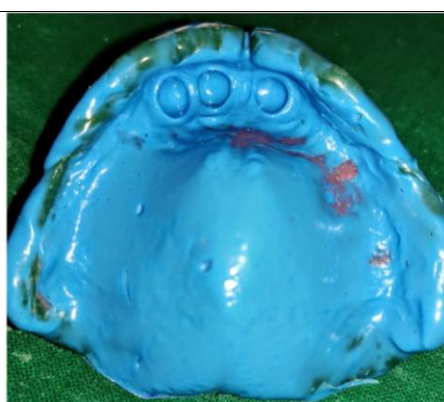

Fig 9b: Final impression

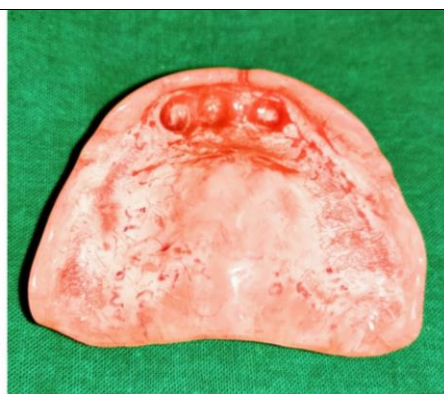
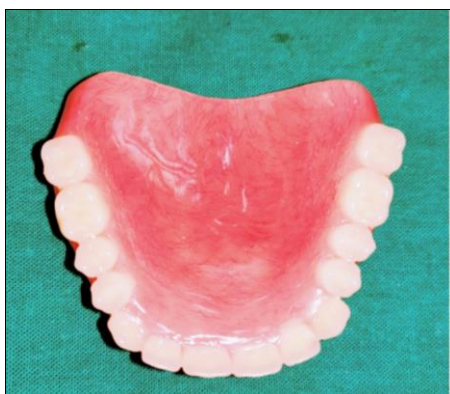
Fig 10: Fabricated denture

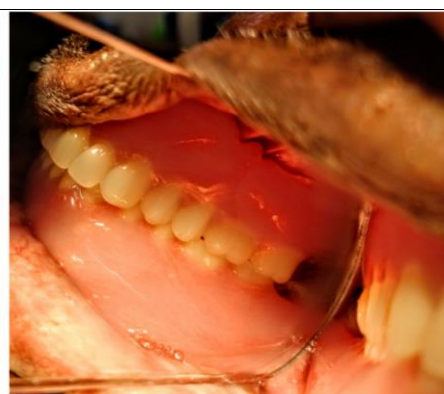
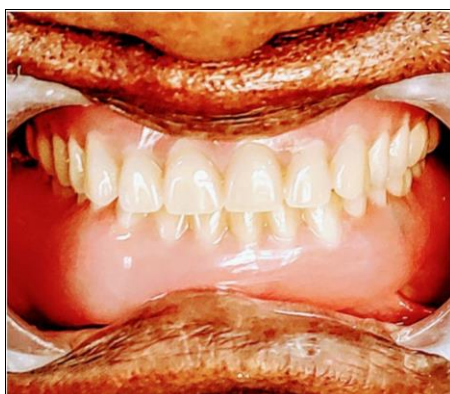
Fig 11: Final upper and lower denture

Discussion

A tooth-supported overdenture trumps over a conventional complete denture in a multitude of ways that have been documented imperatively in literature^[5]. It classifies itself as closely to a preventive procedure since it warrants preserving whatever remains and enhancing them as well through restorative means. Preparing the existing teeth to receive copings not only aids in restoring form by providing support to the prosthesis but also reinforces the periodontal health by altering the crown: root ratio to an acceptable one^[6]. As a matter of fact, providing adequate relief in the intaglio surface on the denture around the abutment even provides for better oral hygiene maintenance without undue pressure from masticatory forces directly wedging onto the gingival tissues. Moreover, the orientation of these forces as such have proven to produce more favourable response in the alveolar bone volume and thus lesser resorption rates of the basal seat, compared to conventional complete dentures^[7]. The retention of teeth also contributes to better stereognosis due to retained proprioceptive impulses from the periodontium of the abutment, that optimizes the function of the prosthesis that takes support. This, additionally provides a positive psychological reinforcement^[8].

Adding attachments enhances the retentive properties of the overdenture. These additions must be provided with adequate attention paid to the available vertical dimension that would not compromise the strength of the denture to accommodate the attachments. A Hader bar connects the available abutments and thus produce a splinting effect on the abutments. Placing a bar requires a more square or ovoid arch form and adequate available vertical dimension to accommodate the bar under the denture base and the artificial teeth over, as well. The direct method of securing the attachment using auto-polymerizing resin, is a chair-side method and saves fabrication laboratory time and resources.⁽⁹⁾ It must be particularly emphasized, that the attachments and the edentulous basal seat, both contribute to the retention, stability and support of the over-denture and thus impression-making becomes as crucial a step towards the success of the prosthesis, as are the tedious laboratory procedures used to fabricate the bar^[10].

Conclusion

Fabrication of a denture in patient with resorb residual alveolar ridge is a challenging task to perform. Although overdenture is a good alternative treatment strategy for such cases but the gauging adequate inter-occlusal space to accommodate the attachments is imperative in the diagnostic stage and one must have thorough knowledge of alternate treatment strategies in cases otherwise. Knowledge of selection of an appropriate attachment system should be of utmost importance, to ensure long-term prognosis in the mechanical point of view. This case report enlightens the clinical and laboratory steps involved in fabricating an overdenture with bar attachments.

Reference

1. Mishra R, Shivrayan A, Jain S, Mehta S. Fabrication of bar-retained tooth-supported mandibular overdenture. *Int J Oral Health Sci* 2014;4:37-41.
2. Crum RJ, Rooney GE Jr. Alveolar bone loss in overdentures: A 5-year study. *J Prosthet Dent* 1978;40(6):610-3.
3. Millar PA. Complete denture supported by natural teeth. *J Prosthet Dent* 1958;8:924.

4. Singh M, Chaudhary A, Aggarwal A *et al.* Tooth supported overdenture with an attachment: a case report. *International Journal of Science & Healthcare Research* 2020;5(1):242-246.
5. Rissin L, House JE, Manly RS, Kapur KK. Clinical comparison of masticatory performance and electromyographic activity of patients with complete dentures, overdentures, and natural teeth. *J Prosthet Dent* 1978;39(5):508-11.
6. Morrow RM, Feldmann EE, Rudd KD, Trovillion HM. Tooth supported complete dentures: An approach to preventive prosthodontics. *J Prosthetic Dent* 1969;21(5):513-22.
7. Renner RP, Gomes BC, Shakun ML, Baer PN, Davis RK, Camp P. Four-year longitudinal study of the periodontal health status of overdenture patients. *J Prosthet Dent* 1984;51:593-8.
8. Scotti R, Melilli D, Pizzo G. Overdenture supported by natural teeth: analysis of clinical advantages. *Minerva Stomatol* 2003;52:201-10.
9. Rudd K, Morrow R. *Dental laboratory procedures Removable partial dentures*, 2nd ed. St Luis: Mosby 1985;3:609-23.
10. Preiskel HW. *Overdentures made easy: a guide to implant and root supported prostheses*, 1st edn. Quintessence, Chicago 1996, 184-193.