



ISSN Print: 2394-7489  
ISSN Online: 2394-7497  
IJADS 2021; 7(2): 391-394  
© 2021 IJADS  
[www.oraljournal.com](http://www.oraljournal.com)  
Received: 23-02-2021  
Accepted: 25-03-2021

**Pragya Singh**  
Department of Periodontology,  
Subharti Dental College and  
Hospital, Meerut, Uttar Pradesh,  
India

**Amit Wadhawan**  
Department of Periodontology,  
Subharti Dental College and  
Hospital, Meerut, Uttar Pradesh,  
India

**Mohd. Nazar Rana**  
Department of Periodontology,  
Subharti Dental College and  
Hospital, Meerut, Uttar Pradesh,  
India

**Mayur Kaushik**  
Department of Periodontology,  
Subharti Dental College and  
Hospital, Meerut, Uttar Pradesh,  
India

**Corresponding Author:**  
**Pragya Singh**  
Department of Periodontology,  
Subharti Dental College and  
Hospital, Meerut, Uttar Pradesh,  
India

## **Demineralized freeze-dried bone allograft with Periocol® membrane versus Perioglas® with Periocol® membrane in the treatment of intrabony defects: A case report**

**Pragya Singh, Amit Wadhawan, Mohd. Nazar Rana and Mayur Kaushik**

DOI: <https://doi.org/10.22271/oral.2021.v7.i2f.1238>

### **Abstract**

**Introduction:** Intrabony defects associated with periodontal pockets can be successfully treated with bone graft and Guided Tissue Regeneration membrane (GTR). Demineralized freeze-dried bone allograft (DFDBA) consists primarily of collagen including bone growth and differentiation factors like Bone Morphogenetic Proteins. Perioglas® is a bioactive glass that is osteoconductive, composed entirely of elements naturally occurring in the body and bonds directly to the bone and soft tissue. Periocol® is a resorbable Guided Tissue Regenerative (GTR) membrane that delays the apical migration of gingival epithelium by excluding the gingival connective tissue and allows granulation tissue derived from PDL and osseous tissues to repopulate the space adjacent to the denuded root surface.

**Objective:** To compare DFDBA with Periocol® and Perioglas® with Periocol® membrane in the treatment of intrabony defects clinically and radiographically.

**Methodology:** A patient with bilateral intrabony defects was selected. In one site - Open Flap Debridement (OFD) with Perioglas® and Periocol® membrane was placed and on the other site – OFD with DFDBA and Periocol® membrane was placed.

**Conclusion:** DFDBA with Periocol® membrane has shown better results than Perioglas® with Periocol® membrane.

**Keywords:** Intrabony defects, DFDBA, bioactive glass, GTR membrane

### **Introduction**

Periodontal disease is one of the most prevalent afflictions worldwide and is the major cause of tooth morbidity and mortality. Periodontitis is characterized by clinical attachment loss and formation of osseous deformities, including furcation and intrabony defects [1]. To correct these osseous defects various surgical treatment modalities are available which include: Open flap debridement (OFD); OFD with bone grafts and Guided tissue regeneration (GTR). Demineralized freeze-dried bone allograft (DFDBA) consists primarily of collagen with some residual proteins; including an array of bone growth and differentiation factors like Bone Morphogenetic Proteins (BMPs), which constitute osteoinductive components of bone along with growth factors such as platelet-derived growth factor and transforming growth factor- $\beta$  [2]. Alloplasts or synthetic graft materials such as bioactive glass are osteoconductive, composed entirely of elements naturally occurring in the body (silica, calcium, phosphorous, oxygen and sodium) bond directly to bone and soft tissue [3]. Guided Tissue Regeneration (GTR), originated by Melcher, suggested that the GTR technique delays the apical migration of gingival epithelium by excluding the gingival connective tissue and allows granulation tissue derived from PDL and osseous tissues to repopulate the space adjacent to the denuded root surface [4].

Thus, the purpose of this study was to compare and evaluate clinically and radiographically the efficacy of DFDBA allograft and Perioglas® with Periocol® membrane in the treatment of intrabony defects.

**Materials and Method**

**Patient selection**

Patient with clinical and radiographic evidence of angular defects in relation to maxillary and mandibular teeth was selected. Inclusion criteria included: i) Patient having non-contributory medical history, ii) no history of antibiotic therapy in the last 6 months, iii) no history of periodontal therapy in the last 3 months, and iv) patient showing optimum compliance in oral hygiene maintenance during the phase-1 (pre-surgical) therapy. Exclusion criteria included: i) Patients having a compromised immune system, ii) patients taking drugs known to cause gingival enlargement, iii) pregnant and lactating mothers, and iv) smokers. The purpose of the investigation and the potential benefits and risks of the materials used and procedures to be performed were explained, and each patient signed a written consent form for their agreement to participate in the study. The study protocol and consent forms were approved by the institutional ethical committee and review board.

Pre-surgical (phase-1) therapy was performed on all patients, which consisted of scaling and root planing, oral hygiene instructions, motivation and education, and occlusal adjustment when indicated.

**Study design**

The patient selected was randomly divided into two sites: At site 1: Intrabony defect was subjected to OFD with Perioglas® and Pericol® membrane. At site 2: Intrabony defect was subjected to OFD with DFDBA and Pericol® membrane.

Patient’s medical history, dental history, personal history was taken and clinical parameters including Gingival Index (Loe and Silness, 1963) [5], Plaque Index (Silness and Loe, 1964) [6], Oral hygiene Index Simplified (Greene and Vermillion, 1964) [7], PPD in mm was measured. RAL in mm was recorded using an acrylic stent. CBCT was also done to assess the area of the defect (Fig.1, 2, 3, 4, 12, 13, 14, 15).

**Surgical procedure**

Adequate anesthesia was achieved by administering 2% xylocaine HCl with adrenaline 1:80, 000. After giving sulcular incisions with Bard Parker knife (blade no. 12), the full-thickness mucoperiosteal flaps were reflected using the periosteal elevators. Complete debridement of the defect was done, and a thorough root planing was carried out using the universal (COLUMBIA 4-R and 4-L) and Gracey (1-14) curettes (Fig.5, 6, 16, 17). The surgical area was thoroughly irrigated with saline, surgical templates were made, and pre-suturing was done (Fig. 7, 18) After isolation, the defect was selected to receive either DFDBA or Perioglas®. The graft was mixed with saline. The Pericol® membrane was then trimmed according to the defect for both sites. After securing the membrane the bone graft was condensed in the intrabony defect and sutures were given (Fig. 8, 9, 19, 20). After surgery postoperative instructions were given and prophylactic antibiotics for 7 days was prescribed; 10 days postoperatively patient recalled for suture removal and reinforcement of oral hygiene instructions (Fig10, 11, 21, 22).

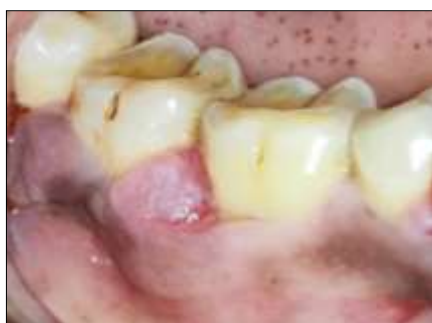

Fig 1

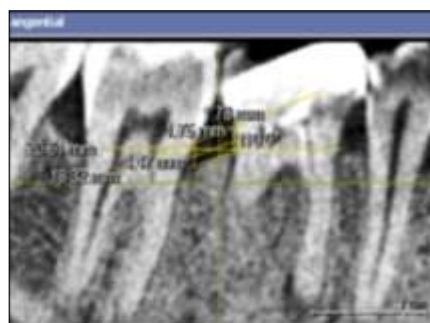


Fig 2

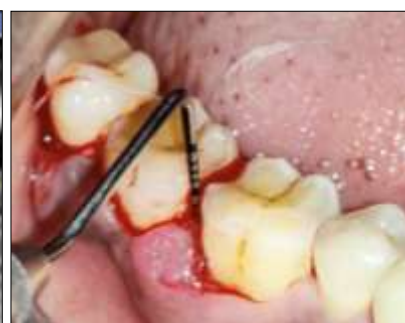

Fig 3

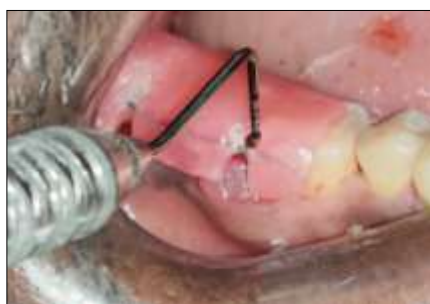

Fig 4

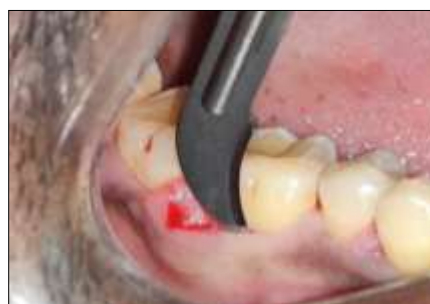

Fig 5

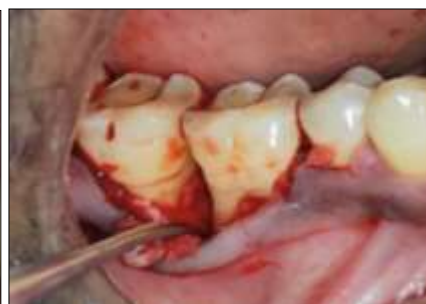

Fig 6

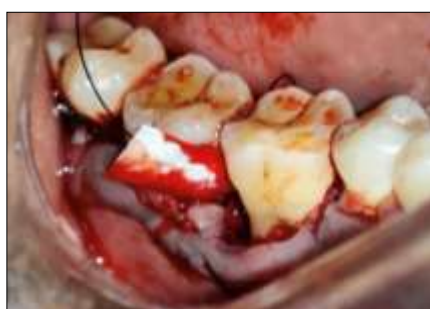

Fig 7

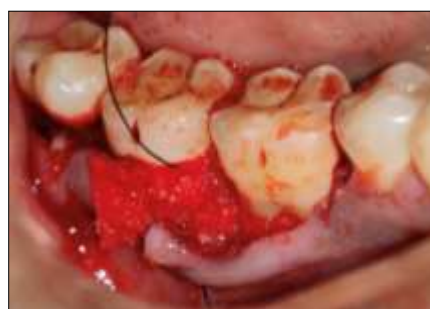

Fig 8

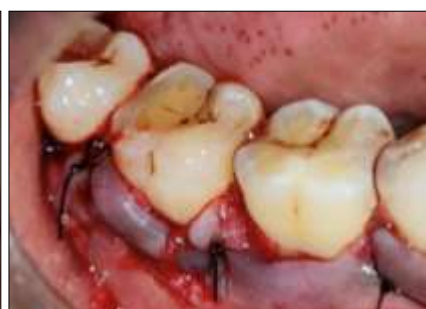
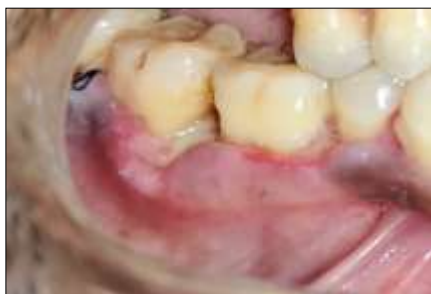
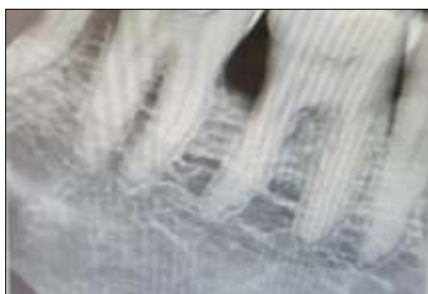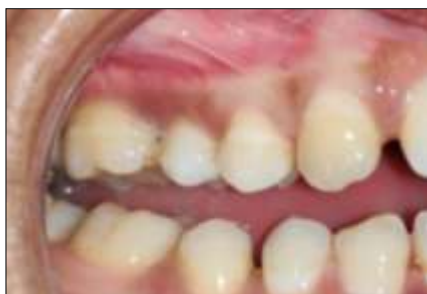Fig 9



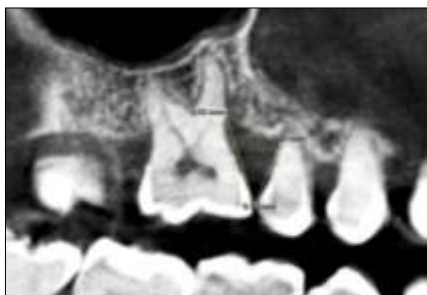**Fig 10**



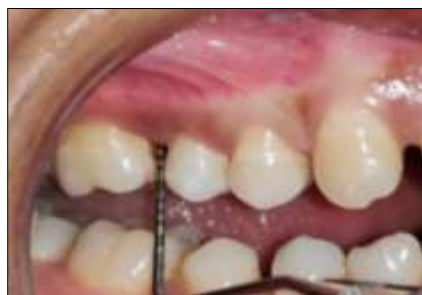**Fig 11**



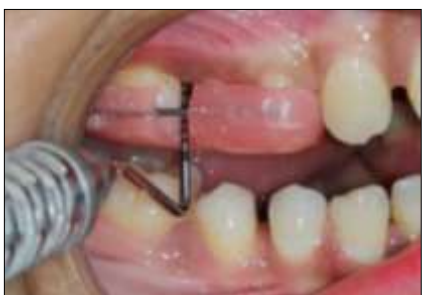**Fig 12**



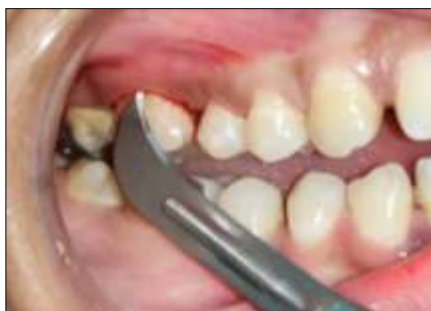**Fig 13**



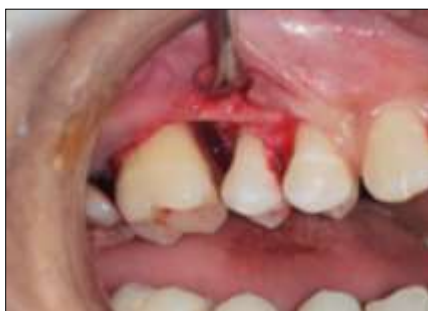**Fig 14**



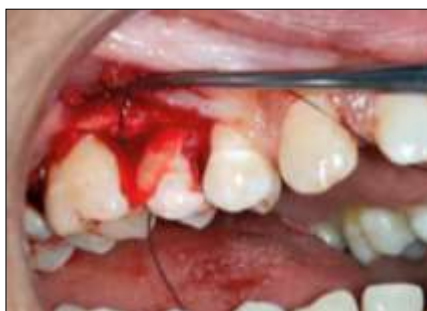**Fig 15**



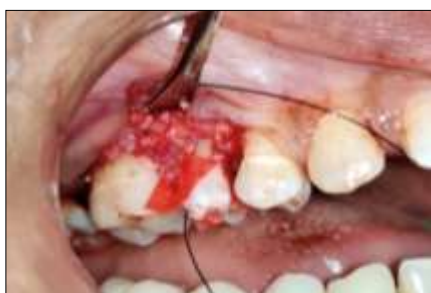**Fig 16**



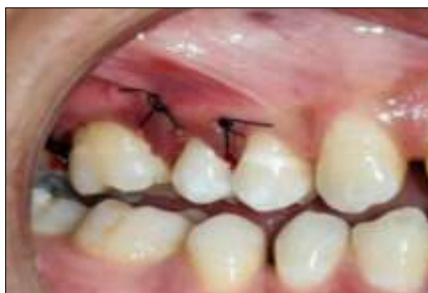**Fig 17**



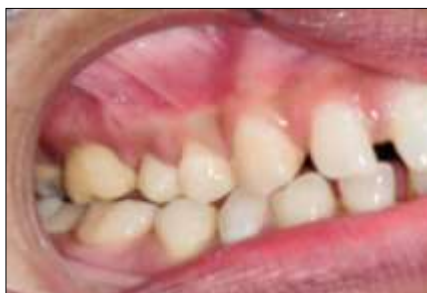**Fig 18**



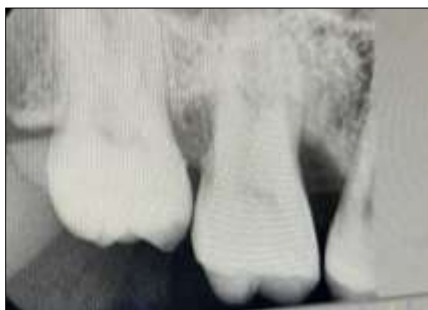**Fig 19**



**Fig 20**



**Fig 21**



**Fig 22**

**Fig 1:** Pre-operative site #47, **Fig 2:** Pre-operative CBCT, **Fig 3:** Pre-operative PPD, **Fig 4:** Pre-operative RAL, **Fig 5:** Crevicular incision given, **Fig 6:** Debridement done, **Fig 7:** Pre-suturing done and Periocol® membrane placed, **Fig 8:** Perioglas® bone graft placed, **Fig 9:** Sutures given , **Fig 10:** Post-operative after suture removal, **Fig 11:** Post-operative radiograph after 3 months, **Fig 12:** Pre-operative site # 16, **Fig 13:** Pre-operative CBCT, **Fig 14:** Pre-operative PPD, **Fig 15:** Pre-operative RAL, **Fig 16:** Crevicular incision given, **Fig 17:** Debridement done, **Fig 18:** Pre-suturing done and Periocol® membrane placed, **Fig 19:** DFDBA bone graft placed, **Fig 20:** Sutures given, **Fig 21:** Post-operative after suture removal, **Fig 22:** Post-operative radiograph after 3 months

## Discussion

The present case report was carried out to compare the efficiency of bioactive glass (osteoconductive) and DFDBA (osteoinductive). Biological responses and healing processes vary slightly different among the synthetics which makes direct comparison more difficult. Results of this case report supported favourably to those found by Katuri *et al.* [8] which reported a reduction in probing pocket depth, gain in CAL and a greater percentage of bone fill when compared to that of bioactive glass. The rationale for using DFDBA had been to not only support the barrier membrane but to induce or stimulate the formation of new bone and have demonstrated the osteogenic potential of demineralized bone grafts [9]. Gothi *et al.* stated that allografts showed significant improvement in the probing depth, RAL and radiographic area of the defect at 6 months postsurgery [10]. PerioGlas® along with barrier membrane proved to be effective in enhancing the periodontal regeneration [11].

## Conclusion

The present case report suggested that the use of DFDBA produced significant soft and hard tissue improvements as compared to Perioglas®.

## References

1. Reynolds MA, Richard TK, Nares S, Camargo PM, Caton JG, Clem DS *et al.* Periodontal regeneration— intrabony defects: Practical applications from the AAP regeneration workshop. *Clin Adv Periodontics* 2015;5:21-29.
2. Xiao Y, Parry DA, Li H, Arnold R, Jackson WJ, Bartold PM. Expression of extracellular matrix macromolecules around demineralized freeze-dried bone allografts. *J Periodontol* 1996;67:1233-1244.
3. Hench LL, Paschall HA. Direct chemical bond of bioactive glass-ceramic materials to bone and muscle. *J Biomed Mater Res* 1973;7:25-42.
4. Murphy KG, Gunsolley JC. Guided tissue regeneration for the treatment of periodontal intrabony and furcation defects. A systematic review. *Ann Periodontol* 2003;8:226-302.
5. Loe H, Silness J. Periodontal disease in pregnancy I. Prevalence and severity. *Acta Odontol Scand* 1963;21:533-540.
6. Silness J, Loe H. Periodontal disease in pregnancy II. Correlation between oral hygiene and periodontal conditions. *Acta Odontol Scand* 1964;22:121-135.
7. Greene JC, Vermillion JR. The Simplified Oral Hygiene Index. *J Am Dent Assoc* 1964;68:7-13.
8. Katuri KK, Kumar PJ, Swarna C, Swamy DN, Arun KV. Evaluation of bioactive glass and demineralized freeze dried bone allograft in the treatment of periodontal intraosseous defects: A comparative clinico-radiographic study. *J Indian Soc Periodontol* 2013;17:367-372
9. Urist MR. Bone: Formation by autoinduction. *Science* 1965;150:893-899.
10. Gothi R, Bansal M, Kaushik M, Khattak BP, Sood N, Taneja V. A comparative evaluation of freeze dried bone allograft and decalcified freeze dried bone allograft in the treatment of intrabony defects: A clinical and radiographic study. *J Indian Soc Periodontol* 2015;19(4):411-5.
11. Wadhawan A, Gowda TM, Mehta DS. Gore-tex (®) versus resolut adapt (®) GTR membranes with perioglas (®) in periodontal regeneration. *Contemp Clin Dent* 2012;3(4):406-411.