



ISSN Print: 2394-7489
ISSN Online: 2394-7497
IJADS 2021; 7(2): 395-398
© 2021 IJADS
www.oraljournal.com
Received: 25-02-2021
Accepted: 28-03-2021

Dr. Devansh Kumar
Post-Graduate, Department of
Orthodontics and Dentofacial
Orthopedics, I.T.S Dental College,
Hospital and Research Centre,
Knowledge Park III, Greater Noida,
Uttar Pradesh, India

Dr. Anshul Singla
Professor and Head, Department of
Orthodontics and Dentofacial
Orthopedics, I.T.S Dental College,
Hospital and Research Centre,
Knowledge Park III, Greater Noida,
Uttar Pradesh, India

Dr. Vishal Singh
Professor, Department of Orthodontics
and Dentofacial Orthopedics, I.T.S
Dental College, Hospital and Research
Centre, Knowledge Park III, Greater
Noida, Uttar Pradesh, India

Dr. Amrita Puri
Professor, Department of Orthodontics
and Dentofacial Orthopedics, I.T.S
Dental College, Hospital and Research
Centre, Knowledge Park III, Greater
Noida, Uttar Pradesh, India

Dr. Shruti Chaudhry
Senior Lecturer, Department of
Orthodontics and Dentofacial
Orthopedics, I.T.S Dental College,
Hospital and Research Centre,
Knowledge Park III, Greater Noida,
Uttar Pradesh, India

Dr. Shruti Premsagar
Senior Lecturer, Department of
Orthodontics and Dentofacial
Orthopedics, I.T.S Dental College,
Hospital and Research Centre,
Knowledge Park III, Greater Noida,
Uttar Pradesh, India

Dr. Shruti Sharma
Post-Graduate, Department of
Orthodontics and Dentofacial
Orthopedics, I.T.S Dental College,
Hospital and Research Centre,
Knowledge Park III, Greater Noida,
Uttar Pradesh, India

Corresponding Author:
Dr. Devansh Kumar
Post-Graduate, Department of
Orthodontics and Dentofacial
Orthopedics, I.T.S Dental College,
Hospital and Research Centre,
Knowledge Park III, Greater Noida,
Uttar Pradesh, India

The dangers of social media and DIY orthodontics amidst COVID-19

Dr. Devansh Kumar, Dr. Anshul Singla, Dr. Vishal Singh, Dr. Amrita Puri, Dr. Shruti Chaudhry, Dr. Shruti Premsagar and Dr. Shruti Sharma

DOI: <https://doi.org/10.22271/oral.2021.v7.i2f.1239>

Abstract

Social media poses new dangers for many young aged dental patients having concern about their aesthetics. Growing up in a digital era where social media is part of our daily routine, everyone is just a click away from all the information be it a fact or myth in almost every domain. Persistently being exposed to highly idealized images, many adolescents try to achieve such standards by trying all sorts of treatments at home, including dental treatment. Dentists need to be aware of these important issues in order to help younger generation to avoid various dangers and to help safeguard their longer term dental health.

This article aims to provide orthodontist about the dangers of spurious claims about ‘do-it-yourself’ dentistry, helping them avoid destructive or unstable treatments, especially those of the ‘quick fix’ variety during times of COVID-19.

Keywords: Orthodontics, COVID-19, Social media

Introduction

Over the past couple of years, ‘fourth-screen’ technology (meaning a small portable video screen such as on a mobile phone) has changed the way young people communicate with each other. [1] Photo and video-sharing applications like Snapchat and Instagram are on every smart phone, majority of which can fit in the palm of our hand and can be used at any time of day or night.

Social media is omnipresent. “Follow me on Twitter”, “Follow me on Instagram” or “Subscribe me on YouTube” can be read almost everywhere in daily life—whether it is in politics, lifestyle, or health care. Social media offers a way to communicate and share information dynamically and interactively. People can express their experiences, thoughts, feelings, and opinions in real time and share these with other social media users [2].

Data from Greenwood *et al.* showed that 83% of women and 75% of men use Facebook, while 38% of women and 26% of men use Instagram [3]. It appears that 88% of 18–29 year-olds use Facebook, whereas 59% of the same age group use Instagram. It seems that majority of the younger audiences may have moved to social media applications.

The following cases reported to our department of Orthodontics and Dentofacial Orthopedics after the first wave of COVID-19.

Case Reports

Case 1

A 30 year old male patient reported with chief complaint of bleeding gums, mobility of teeth and gingival recession. On clinical examination it was revealed that an elastic had slipped below the contact points of the teeth (Fig 1, 2). Clinically soft and oedematous gingiva was seen, with spontaneous bleeding on probing, grade II mobility and grade III gingival recession. Radiographically severe bone loss was seen till the apical 1/3 (Fig 3).

On further questioning the patient informed that he had seen videos on YouTube on how to close space between teeth. In which he saw a YouTuber use an elastic over a period of time and closed the gap between his teeth.

A similar case was reported by Konstantonis D, where the patient had place an elastic in upper front tooth region to close

the gap between his teeth which eventually lead to the loss of teeth involved.

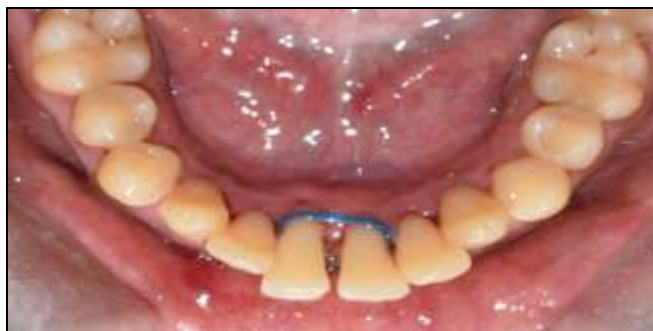

Fig 1.

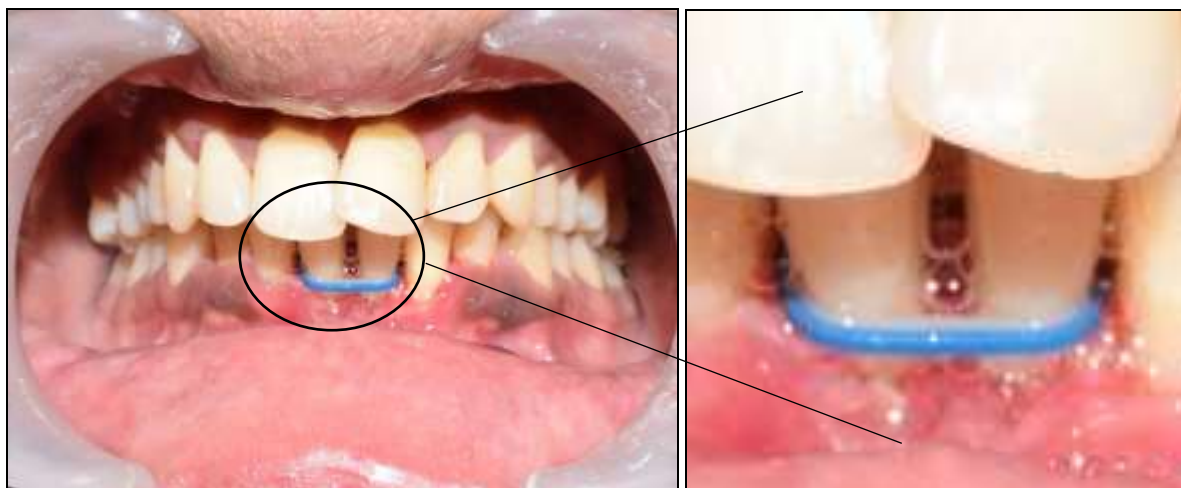


Fig 2.

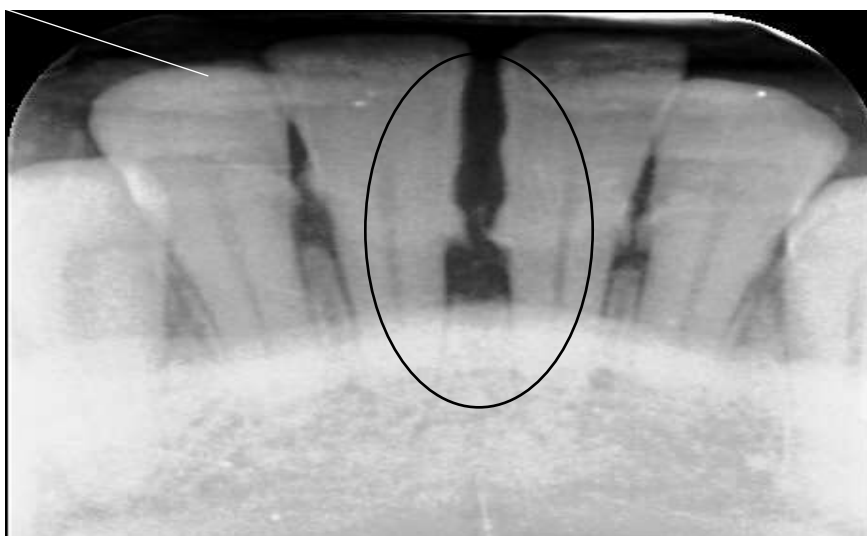


Fig 3.

Case 2

A 23 year old female patient reported to OPD with chief complaint of severe sensitivity even on inhalation of air. Clinically flat incisal surfaces was seen and sensitivity even on inhalation of air in upper incisors secondary to filing of teeth was observed (Fig. 4, 5). Radiographically flat incisal

edge with depth approaching pulp was observed (Fig. 6) On detailed history the patient revealed that she had longer central incisors as compared to her adjacent teeth which she trimmed using nail filer motivated by a beauty lifestyle video on YouTube.

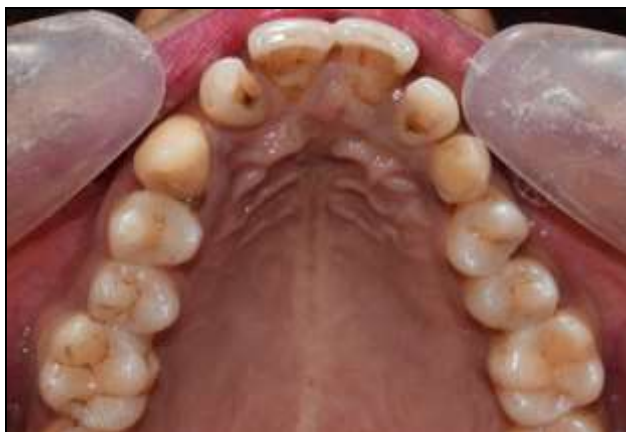

Fig. 4

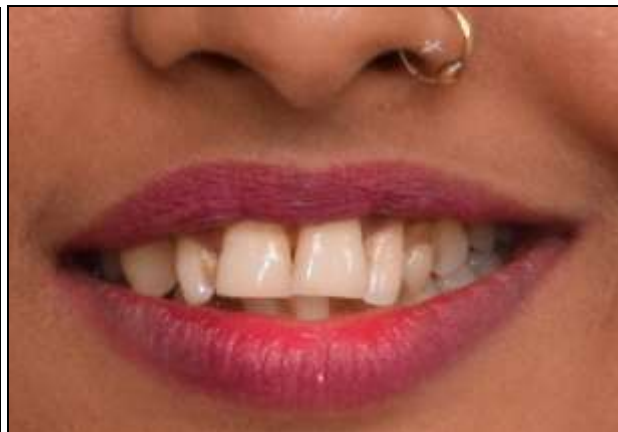

Fig. 5

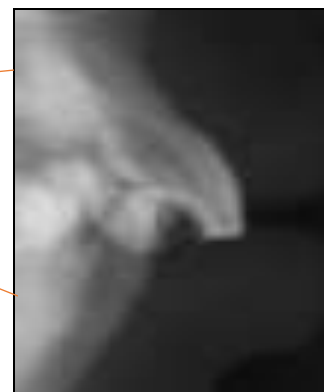
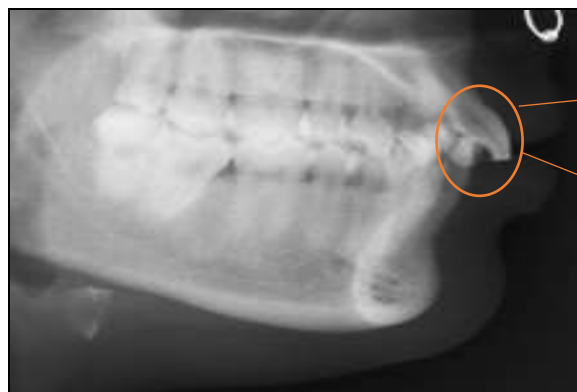

Fig 6.

Discussion

The potential for acceptance of DIY orthodontics by the public should not be taken lightly. Several studies have alerted to the harmful effects of the incorrect use of orthodontic elastic bands. Placement of orthodontic elastic bands around the cervical part of teeth can cause localized periodontal destruction by sub gingival migration of the band and subsequent tooth loss.^[4]

Depending on severity of the case, various treatment options may be tried. In case 1 area needs to be debrided of all the foreign bodies, granulation tissues, and calculus. The affected teeth may sometimes require splinting before surgical intervention. It may be required to raise a full thickness flap as in the case of Nettem *et al.*^[5] Whereas in case 2 due to severe filing of the tooth the enamel and dentin surface have been abraded leading to sensitivity even on breathing air which required an interdisciplinary approach in which root canal treatment was advised.

DIY orthodontics is becoming a readily available option for the general public through channels of social media. All dental professionals, especially orthodontists, should recognize this as a possible threat to public health and take action to protect the public by generating regulations.

Such home remedies that people are trying are either due to lack of visit to the orthodontist during COVID-19 times or either due to the lack of knowledge or affordability of the treatment cost.

Conclusion

In these case reports interdisciplinary approach to orthodontic treatment was required, resulting in first treating the underlying condition caused by the patients themselves. Social media offers unsupervised access to photographs of emerging trends in beauty and fashion. On the internet, there

are commercially driven ads for dubious therapies that are not founded on solid scientific evidence or legality, thereby endangering the long-term health of young patients.

References

1. Rana S, Kelleher M. The Dangers of Social Media and Young Dental Patients' Body Image. *Dental Update* 2018;45(10):902-10.
2. Graf I, Gerwing H, Hoefler K, Ehlebracht D, Christ H, Braumann B. Social media and orthodontics: A mixed-methods analysis of orthodontic-related posts on Twitter and Instagram. *American Journal of Orthodontics and Dentofacial Orthopedics* 2020;158(2):221-8.
3. Greenwood S, Perrin A, Duggan M. *Social Media Update 2016*. Pew Research Center: Internet & Technology, 2016. Available at: <http://www.pewinternet.org/2016/11/11/social-media-update-2016>
4. Zilberman Y, Shteyer A, Azaz B. Iatrogenic exfoliation of teeth by the incorrect use of orthodontic elastic bands. *The Journal of the American Dental Association* 1976;93(1):89-93.
5. Nettem S, Nettemu SK, Kumar KK, Reddy GV, Kumar PS. Spontaneous reversibility of an iatrogenic orthodontic elastic band-induced localized periodontitis following surgical intervention—case report. *The Malaysian Journal of Medical Sciences* 2012;19(4):77-80.
6. Behrents RG. Simply the best. *Am J Orthod Dentofacial Orthop* 2016;149:439-40.
7. Kravitz ND, Burris B, Butler D, Dabney CW. Teledentistry, do-it-yourself orthodontics, and remote treatment monitoring. *J Clin Orthod* 2016;50:718-26.
8. Park JH. Teledentistry and do-it-yourself orthodontics. *PCSO Bulletin* 2019;91:5-6. Available at:

<http://www.brightcopy.net/allen/pcso/91-4/index.php#/8>.

9. Behrents RG. Who is responsible to inform and protect the public? *Am J Orthod Dentofacial Orthop* 2014;146:407-8.
10. Abel Y, Nelson S, Amberman BD, Hans MG. Comparing orthodontic treatment outcomes between orthodontists and general dentists with the ABO index. *Am J Orthod Dentofacial Orthop* 2004;126:544-8.
11. AAO. Cautions the Public as New DIY Orthodontics Approach Gains Attention. American Association of Orthodontists. AAO 2016.
12. Konstantonis D, Brenner R, Karamolegkou M, Vasileiou D. Torturous path of an elastic gap band: interdisciplinary approach to orthodontic treatment for a young patient who lost both maxillary central incisors after do-it-yourself treatment. *Am J Orthod Dentofacial Orthop* 2018;154:835-847.