



ISSN Print: 2394-7489
ISSN Online: 2394-7497
IJADS 2021; 7(2): 574-579
© 2021 IJADS
www.oraljournal.com
Received: 16-02-2021
Accepted: 18-03-2021

Minha Majeed Kak
PG Scholar, Oral and
Maxillofacial Pathology,
Kothiwal Dental College and
Research Centre, Moradabad,
Uttar Pradesh, India

Priyanka Rastogi
Professor and HOD, Oral and
Maxillofacial Pathology,
Kothiwal Dental College and
Research Centre, Moradabad,
Uttar Pradesh, India

Anurag Nath
PG Scholar, Oral and
Maxillofacial Pathology,
Kothiwal Dental College and
Research Centre, Moradabad,
Uttar Pradesh, India

Ritesh Kumar
Lecturer, Oral and Maxillofacial
Pathology, Kothiwal Dental
College and Research Centre,
Moradabad, Uttar Pradesh,
India

Corresponding Author:
Minha Majeed Kak
PG Scholar, Oral and
Maxillofacial Pathology,
Kothiwal Dental College and
Research Centre, Moradabad,
Uttar Pradesh, India

Histopathological interpretation of oral cavity lesions

Minha Majeed Kak, Priyanka Rastogi, Anurag Nath and Ritesh Kumar

DOI: <https://doi.org/10.22271/oral.2021.v7.i2i.1266>

Abstract

Although the oral cavity lesions constitute only a small minority of pathological conditions, they are of great significance, as they have a potential to jeopardize the health and longevity of the patient. Among the various oral cavity lesions, oral cancer is a global health problem with increasing incidence and mortality rates. In India a vast majority of oral cancers are preceded by precancerous lesions & conditions caused by the use of tobacco in various forms. The aim of the present study is to know the spectrum and patterns of various oral cavity lesion. All the oral cavity specimens received in the Department of Oral Pathology, during the study period were included for the study. Data such as age, gender, and site of the lesion was collected. Data collected was analyzed. A total of 100 cases were analyzed during the study period. Age ranged from 2 to 78 years in the study. Overall male were affected more than the female with male: female (M:F) ratio of 3.5:1. Buccal mucosa (33%) was the commonest site involved followed by tongue (28%). Neoplastic lesions accounted for 69% cases and non-neoplastic accounted for 31% cases. Among the neoplastic lesion, squamous cell carcinoma (SCC) was seen in 40% cases; verrucous carcinoma in 6% and ameloblastic carcinoma in 1% cases; and adenosquamous carcinoma 1% cases. Most of the malignant lesions were located in the buccal mucosa (16%) and tongue (15%), followed by gingiva (6%), palate & floor of mouth (4%) each, lips (2%) alveolus (1%). Histology along with a detailed clinical work-up was found to be a useful, reliable and accurate diagnostic technique for lesions of oral cavity. A variety of lesions were encountered in the study with predominance of malignant lesions. Squamous cell carcinoma was the commonest malignant lesion.

Keywords: oral cavity, squamous cell carcinoma, buccal mucosa, malignancy

Introduction

Oral mucosa provides a defensive mechanism against various microbial pathogens, trauma as well as carcinogens. It can be affected by a variety of soft tissue lesions and conditions ^[1].

Oral mucosal lesions are usually mystified by their etiology which may be viral, fungal, bacterial, any habits related or may even be without definite etiology. Hence, it is of utmost importance to have knowledge regarding the lesions that occur in the oral mucosa ^[2].

Development of malignant oral lesions is generally through a progression from the oral conditions termed as premalignant. The terms precancer, precursor lesions, premalignant, intra-epithelial neoplasia and potentially malignant have been used in the literature to broadly describe clinical presentation that may have a potential to become cancer. A precancerous lesion is a morphologically altered tissue in which oral cancer is more likely to occur than in its apparently normal counterpart ^[3].

Oral cancer ranks the 8th most common cancer worldwide and 3rd most common cancer in India. Age standardized incidence rate of oral cancer is 12.6 per 100,000 population ^[4].

Certain common oral lesions appear as masses, prompting concern about oral carcinoma. Many are benign, although some (e.g., leukoplakia) may represent neoplasia or cancer. Palatal and mandibular tori are bony protuberances and are benign anomalies. Oral pyogenic granulomas may appear in response to local irritation, trauma, or hormonal changes of pregnancy. Mucoceles represent mucin spillage into the oral soft tissues resulting from rupture of a salivary gland duct. Oral fibromas form as a result of irritation or masticatory trauma, especially along the buccal occlusal line. Oral cancer may appear clinically as a subtle mucosal change or as an obvious mass. Oral leukoplakia is the most common premalignant oral lesion. For persistent white or erythematous oral lesions, biopsy should be performed to rule out

neoplastic change or cancer. Most oral cancers are squamous cell carcinomas. Tobacco and heavy alcohol use are the principal risk factors for oral cancer. Family physicians should be able to recognize these lesions and make appropriate referrals for biopsy and treatment [5].

Histopathology is still the gold standard for the diagnosis of oral cavity lesions. Different sites in the oral cavity show propensity for different types of lesions. The present study was carried out to assess the pattern of various oral cavity lesions.

Materials and Methods

This study was carried out in the Department of oral Pathology.

Clinical data

Patient clinical data included in the study were sex, age at presentation, personal habits like betel usage, tobacco smoking, alcohol consumption, others and family history of oral cancer. Clinical examination included site of the lesion and morphology of the lesion.

Histopathological data

The specimen consisted of excisional biopsy performed on small lesions, incisional biopsy performed on large lesions and multiple specimens from different areas. The tissue samples were fixed in 10% neutral buffered formal saline. It was then processed in automatic tissue processor, embedded in paraffin and cut at a thickness of 5 microns and blocks and slides prepared. Slides were stained with routine Haematoxylin and Eosin stain and then studied by Pathologists. Whenever special stains like Periodic acid Schiff

(PAS) were required, additional slides of the same were made. Results were then correlated with the clinical history of the patients. Data were analyzed.

Results

A present study shows evaluation of 100 cases of oral cavity lesions. The age for oral cavity lesions ranged from 2 to 78 years. Out of total 100 cases, 78 (78%) were males and 22 (22%) were females. A Male:Female ratio of 3.5:1. Youngest was an 2-year-old female child, who diagnosed with mucocele.

Oldest was a 78-year-old male diagnosed with squamous cell carcinoma of tongue, came with history of tobacco chewing and development of oral ulcer. Only 6 cases were observed in less than 20 years of age group, all having benign lesions.

Non-neoplastic, benign neoplasms and malignant lesions according to the age have been depicted in [Table-1]. The sites of involvement of various lesions (in decreasing frequency) included: buccal mucosa 33 (33%), tongue 28 (28%), gingiva 17 (17%), palate 11 (11%), lip 5 (5%), floor of mouth 4 (4%) & alveolus 2 (2%) cases [Table-2].

In present study males have more oral cavity lesions (both neoplastic and non-neoplastic) than the females.

In the oral cavity, benign lesions mostly involved the buccal mucosa followed by tongue, gingiva & palate, lip in descending order of frequency. Inflammatory lesions of oral cavity, most commonly seen in buccal mucosa.

Neoplastic lesions (both benign and malignant lesions) accounted for 69% cases and non-neoplastic lesions accounted for 31% cases. The various lesions have been depicted in [Table-4].

Table 1: Age-wise distribution of oral lesions

Age (Years)	Non-neoplastic No (%)	Benign No (%)	Malignant No (%)	Total No (%)
<20	0	6	0	6
21-40	9	6	9	24
41-60	15	6	28	49
61-80	7	3	11	21
Total	31	21	48	100

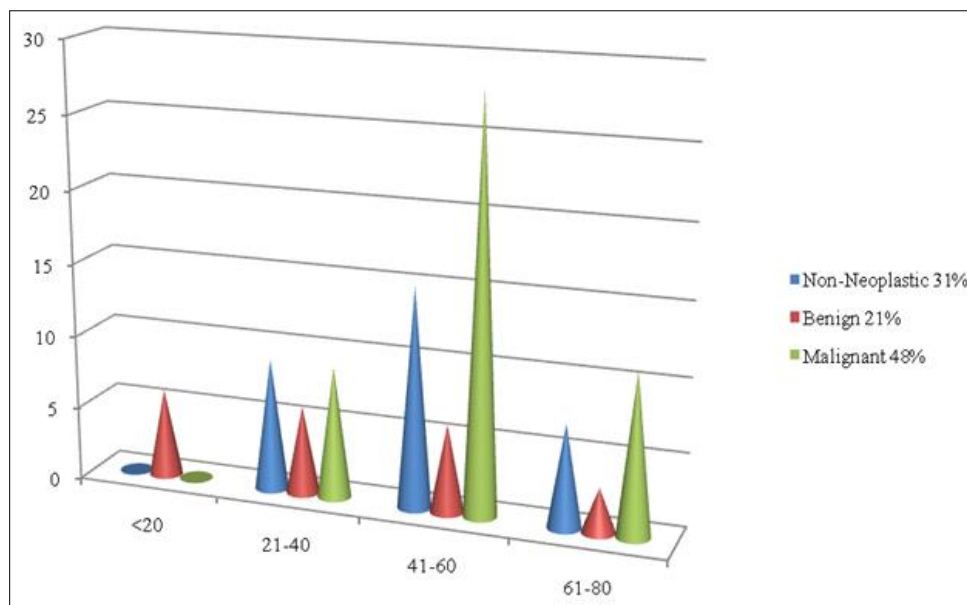


Fig 1: Age-wise distribution of oral lesions

Table 2: Regional distribution of oral lesions

Site	Non neoplastic	Benign	Malignant	Total (%)
Buccal mucosa	11	06	16	33
Tongue	08	05	15	28
Gingiva	07	04	06	17
Palate	03	04	04	11
Lip	01	02	02	05
Floor of mouth	00	00	04	04
Alveolus	01	00	01	02
Total	31	21	48	100

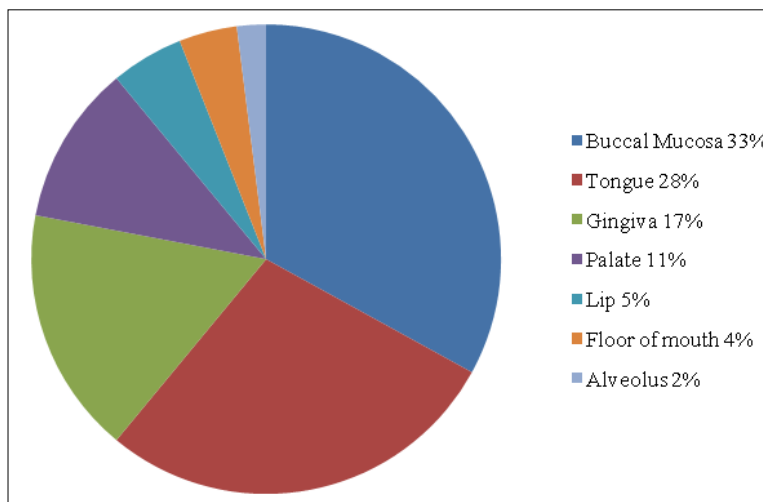


Fig 2: Regional distribution of oral lesions

Table 3: The distribution of study cases regarding their sex and nature of lesion

Sex	Non-neoplastic No (%)	Benign No (%)	Malignant No (%)	Total (%)
Male	25	13	40	78
Female	06	8	8	22
Total	31	21	48	100

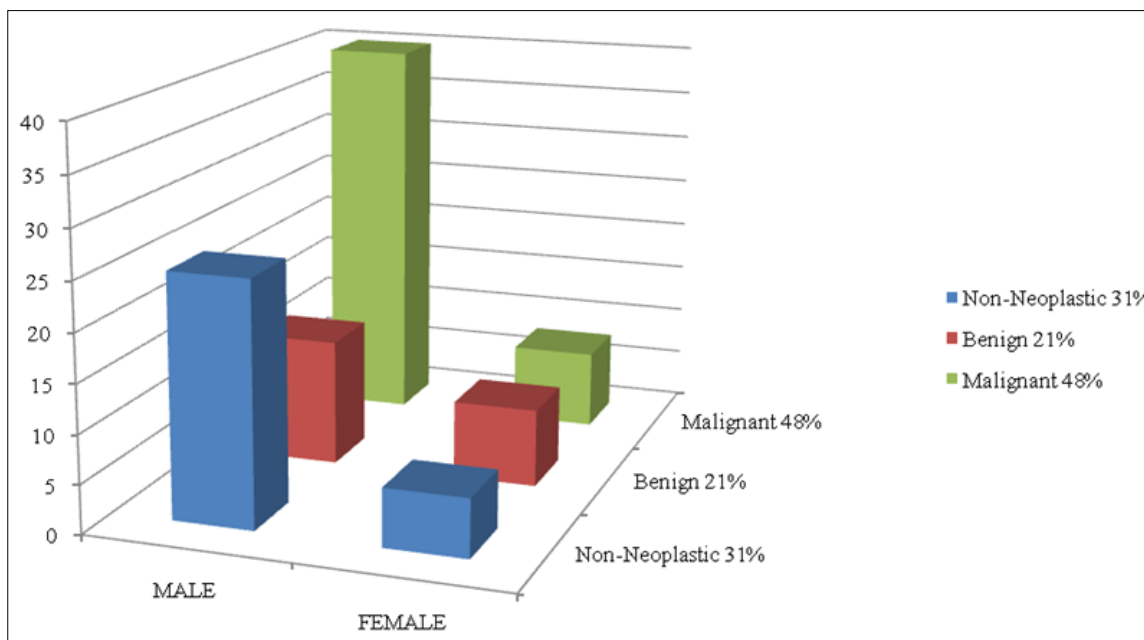


Fig 3: The distribution of study cases regarding their sex and nature of lesion

Table 4: Overall distribution of oral cavity lesions

Type of lesion	Number	Percentage (%)
Non-neoplastic	31	31 (%)
Chronic inflammatory lesions	9	9 (%)
Fibrosis	10	10 (%)
Fibrous hyperplasia	3	3 (%)
Cyst	4	4 (%)
Tubercular pathology	1	1 (%)
Mucocele	4	4 (%)
Benign lesions	21	21 (%)
Granuloma pyogenicum	7	7 (%)
Papilloma	10	10 (%)
Hemangioma	3	3 (%)
Pleomorphic adenoma	1	1 (%)
Malignant lesions	48	48 (%)
Squamous cell carcinoma	40	40 (%)
Verrucous carcinoma	6	6 (%)
Ameloblastic carcinoma	1	1 (%)
Adenosquamous carcinoma	1	1 (%)
Total	100	100 (%)

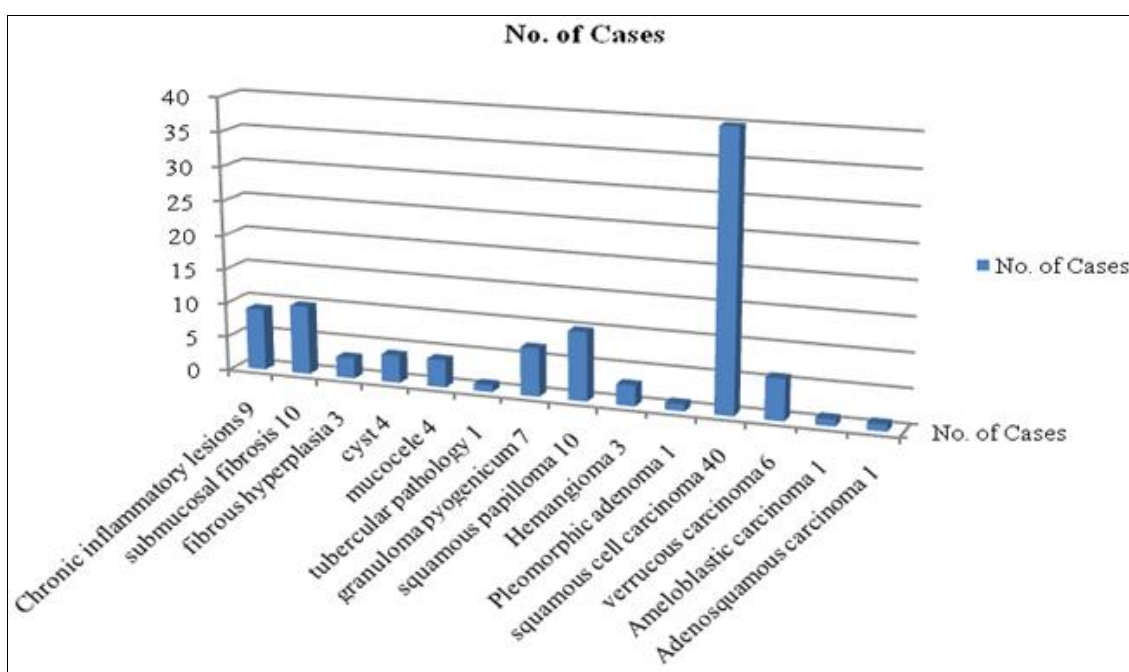


Fig 4: Overall distribution of oral cavity lesions

Table 5: Comparison of distribution of oral cavity lesions-Gender wise with other study

Gender	Present study	Pudasaini S and Barar R [6]	Ranjan <i>et al.</i> [14]
Male	78%	57%	75.18%
Female	22%	43%	24.81%

Table 6: Comparison of nature of oral cavity lesions with other studies

Nature of lesion	Present study	Modi <i>et al.</i> [7]	Ranjan <i>et al.</i> [14]
Non-neoplastic	31%	38.6%	39.10%
Benign	21%	28.7%	13.53%
Malignant	48%	32.7%	47.36%

Table 7: Comparison of regional distribution of oral cavity lesions with other studies

Site	Present study	Modi <i>et al.</i> [7]	Ranjan <i>et al.</i> [14]
Buccal mucosa	33%	26.8%	20.32%
Tongue	28%	26.1%	29.32%
Gingiva	17%	21%	-
Palate	11%	12.6%	9.02%
Lip	05%	6.7%	7.52%
Floor of mouth	04%	3.4%	10.53%
Alveolus	02%	3.4%	-
Tonsil	-	-	22.56%
Vestibule	-	-	0.75%

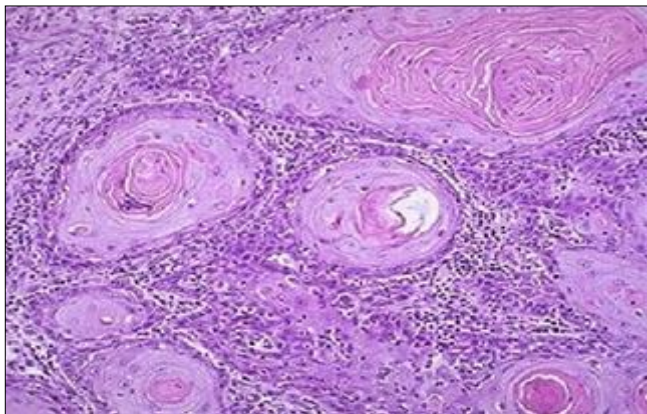


Fig 5: Squamous cell carcinoma

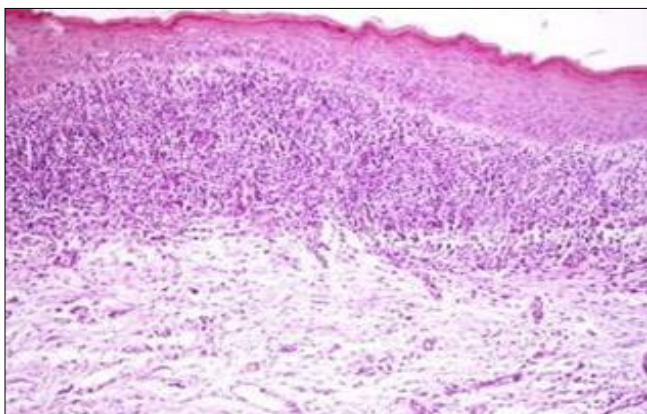


Fig 6: Oral submucosal fibrosis

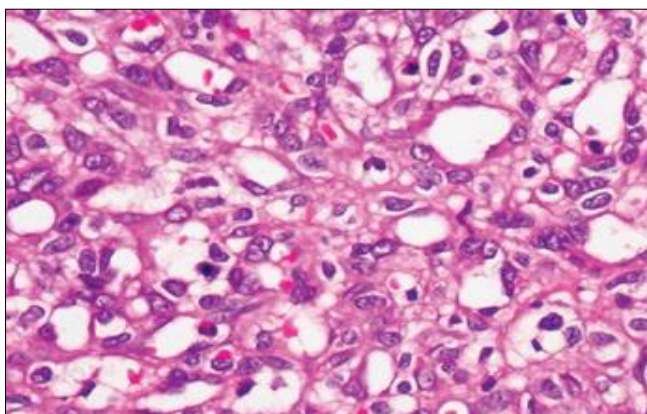


Fig 7: Granuloma pyogenicum

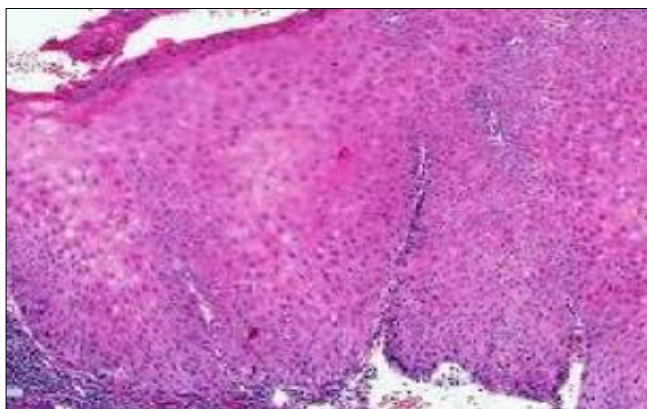


Fig 8: Verrucous carcinoma

Discussion

Oral cancer is a global health problem with increasing incidence and mortality rates. In India, a vast majority of oral

cancers are preceded by precancerous lesions and conditions caused by the use of tobacco in some form.

In our study the age range was 2 to 78 years with a mean of 40 years. This co-relates with many studies done in the different parts of the world.

In the present study, men had high incidence of oral mucosal lesions than in females, which is similar to the report by Pudasaini S and Barar R [6] and Ranjan *et al.* [14]. In contrast, previous studies by Modi *et al.* [7] and Claudia *et al.* [8] reported a higher incidence of oral lesions in females, probably due to more deleterious oral habits in females in their area of study. However, malignant lesions were more common in males, as also reported by Iype *et al.* [9].

Benign lesions were more common in age group 20-40 years and maximum malignant lesions were seen in age group 41-60 years similar to the findings of Saraswathi *et al.* [10]. It was observed in our study that benign neoplastic lesions accounted for 21 (21%) cases. Malignant neoplastic lesions (48%) accounted for the maximum number of cases, similar to that reported by Ranjan *et al.* [14]. If the non-neoplastic and benign neoplasms were clubbed together the incidence was 52 cases (52%), similar to that observed by Mehrotra *et al.* [11].

The incidence of neoplastic lesions was more common in males than in females with M:F ratio of 3.5:1 which is higher than study of Pudasaini S and Barar R [6]. Who documented a ratio of 2:1. This observation can be due to more unhygienic oral habits in males in this area.

In the present study, the incidence of oral cancer increased, as the age increased, which was similar to the study of Modi *et al.*, and Malaovalla *et al.* [7, 12].

In our study the most common site affected was buccal mucosa followed by tongue and then the gingiva. Study by Modi *et al.* [7] reported buccal mucosa as the main site to be involved. In the present study malignancy was observed to involve buccal mucosa & tongue most frequently, probably due to use of tobacco. Modi *et al.* [7] and Mirbod and Ahing [13] also reported ventrolateral border of tongue to be the commonest site for carcinoma tongue.

Tongue and gingiva are the most common sites of infection in patients with oral tuberculosis, Oral tubercular lesions progressively extend from the gingival margin to the depths of the adjacent vestibule and are often associated with enlarged cervical lymph nodes [1].

Verrucous lesions of the oral cavity comprise of a wide spectrum of clinicopathologically overlapping lesions. Verrucous hyperplasia was first described by Shear and Pindbor [15]. Diagnosis of verrucous lesions is challenging for clinicians as well as pathologists as they include a spectrum of benign, potentially malignant, and frankly invasive malignancies. The lesions have similar gross morphology and distinguishing them clinically is difficult, even an incisional biopsy may be misleading. There is a lot of confusion regarding the current clinical and histopathological guidelines to diagnose this potentially malignant entity [16].

Oral cavity has rich blood supply and lymphatic drainage, therefore the likelihood of cervical metastases of Squamous cell carcinoma is very high making it a life-threatening disease [17]. Early diagnosis and treatment is necessary in oral cancer as studies have shown that a cure rate of over 90% can be achieved in early stages [18]. The reasons for increase in incidence of oral cancer in Indians are urbanization, changes in lifestyles, increased population and increased lifespan of individuals [19].

It should be noted that the data from a single institution may have some limitations. It usually reflects the specific patient

population reporting to the hospital rather than the community as a whole. Oral cavity is easily accessible to examination, so early diagnosis of pre-cancerous and cancerous lesions can be detected much easily. However, the most important step is preventing the use of tobacco or its products. Various research techniques have been used to increase the sensitivity and specificity of detection of oral lesions especially malignancy but all have their own limitations. These diagnostic tests include -Toluidine blue staining, oral brush cytology, tissue reflectance, narrow emission tissue fluorescence, tumour markers and molecular diagnostic techniques^[20,21].

Conclusion

In our study, a variety of lesions were encountered with predominance of malignant lesions, Squamous cell carcinoma being the commonest. Any mass lesion especially in the oral cavity should be biopsied to rule out malignancy. Histology along with a detailed clinical workup was found to be a useful, reliable, and accurate diagnostic technique for lesions of the oral cavity. An increase in premalignant lesions, associated with increased pan masala intake is alarming and needs to be taken care of. Oral cavity is the easily accessible site for self-examination and clinical inspection at regular interval, so early diagnosis of malignant lesions can be possible.

Health professionals should encourage to disseminate information of harmful effects of tobacco chewing and development of oral cancer.

Notes

Financial or other competing interests: None

References

1. Ali M, Joseph B, Sundaram D. Prevalence of oral mucosal lesions in patients of the Kuwait University Dental Center. *Saudi Dent J* 2013;25(3):111-8.
2. Prasad KV, Javali SB, Rajesh G, Jithendra A. An epidemiological study of oral mucosal lesions in Karnataka State, India. *J Indian Acad Oral Med Radiol* 2004;16(1):9-18.
3. DeSouza C, Pawar U, Chaturvedi P. Precancerous Lesions of Oral Cavity. *Otorhinolaryngol Clin: An Int J* 2009;1(1):7-17.
4. Strengthening the prevention of oral cancer; the WHO perspective. *Community Dentistry Oral Epidemiology* 2005;33:397-99.
5. Wanda Gonsalves C, MD, Angela Chi C, DMD, Brad Nenille W, DDS. Common oral lesions: Part II. Masses and neoplasm. *Am Fam Physician* 2007;75(4):509-512.
6. Pudasaini S, Barar R. Oral cavity lesions: A study of 21 cases. *Journal of Pathology of Nepal* 2011;l:49-51.
7. Modi D, Laishram RS, Sharma LD, Debnath K. Pattern of oral cavity lesions in a tertiary care hospital in Manipur, India. *J Med Soc* 2013;27:199-202.
8. Claudia FG, Marqués NA, Berini-Aytés L, Gay-Escoda C. Prevalence of biopsied oral lesions in a Department of Oral Surgery (2007-2009) *J Clin Exp Dent* 2011;3:e73-77.
9. Iype EM, Pandey M, Mathew A, Thomas G, Sebastian P, Nair MK. Oral cancer among patients under the age of 35 years. *J Postgrad Med* 2001;47:171-76.
10. Saraswati TR, Ranganathan K, Shanmugam S, Ramesh S, Narasimhan PD, Gunaseelan R. Prevalence of oral lesions in relation to habits: Cross-sectional study in south India. *Indian J Dent Res* 2006;17:121-25.
11. Mehrotra R, Pandya S, Chaudhary AK, Kumar M, Singh M. Prevalance of oral pre-malignant and malignant lesions at a tertiary level hospital in Allahabad, India. *Asian Pac J Cancer Prev* 2008;9:263-6.
12. Malaovalla M, Silverman S, Mani NJ, Bilimoria KF, Smith IW. Oral cancer in 57,518 industrial workers of Gujarat, India: A prevalence and follow up study. *Cancer* 1976;37(4):1882-6. PMID: 946594.
13. Mirbod SM, Ahing SI. Tobacco-associated lesions of oral cavity. Part II. Malignant lesions. *J Can Dent Assoc* 2000;66:308.
14. Ranjan Agrawal *et al.* Spectrum of Oral Lesions in A Tertiary Care Hospital. *J Clin Diagn Res* 2015;9(6):EC11-EC13.
15. Shear M, Pindborg JJ. Verrucous hyperplasia of the oral mucosa. *Cancer* 1980;46:1855-62.
16. Kallarakkal TG, Ramanathan A, Zain RB. Verrucous papillary lesions: Dilemmas in diagnosis and terminology. *Int J Dent* 2013, 298249.
17. Haq MEU, Abid H, Hanif MK, Warraich RA, Mahmood HS, Saddique K. Frequency and pattern of oral and maxillofacial carcinomas. *Annals* 2009;15:171-75.
18. Kumar S, Heller RF, Pandey U, Tewari V, Bala N, Oanh KTH. Delay in presentation of oral cancer: A multifactor analytical study. *Natl Med J India* 2001;14(1):13-17.
19. Murthy NS, Mathew A. Cancer epidemiology, prevention and control. *Current Sci* 2004;86(4):518- 27.
20. Misra V, Singh PA, Lal N, Agarwal P, Singh M. Changing pattern of oral cavity lesions and personal habits over a decade: Hospital based record analysis from Allahabad. *Indian J Community Med* 2009;34:321-25.
21. Sridharan G. Epidemiology, control and prevention of tobacco induced oral mucosal lesions in India. *Indian J Cancer* 2014;51:80-85.